

LEFT PARADUODENAL HERNIA PRESENTING WITH ACUTE INTESTINAL OBSTRUCTION - A DIAGNOSTIC DILEMMA

Dr. Shailesh Kumar¹, Dr. Priyadarshi Dikshit², Dr. Naveen Kumar³, Dr. Swati Sattavan⁴
Department of General Surgery, PGIMER & Dr. RML Hospital, New Delhi, India

ABSTRACT

Introduction: Left Para-duodenal hernias (LPDH) are uncommon causes of acute intestinal obstruction which may remain asymptomatic or may present with chronic left abdominal pain with or without acute intestinal obstruction. Early diagnosis and treatment is associated with decreased morbidity and mortality.

Case Summary: A middle aged lady presented with features of acute intestinal obstruction which on exploration was found to be left para-duodenal hernia. The hernia was reduced and sac obliterated.

Conclusion: LPDH should be kept in the differential diagnosis for patients presenting with chronic left upper abdominal pain. High degree of suspicion, early diagnosis, with familiarity of surgical anatomy may obviate the need of an emergency laparotomy and avoid any associated intra or perioperative complication.

KEYWORDS: Acute Intestinal Obstruction, Internal Hernia, Left para-duodenal hernia

ABBREVIATIONS: PDH: Para-duodenal Hernia; LPDH: Left Para-duodenal Hernia

Corresponding author mail: shaileshkdr@gmail.com

Conflict of interest: NO

Case is original: Yes

INTRODUCTION

Internal hernias account for around 1% of all cases of acute intestinal obstruction [15]. Para-duodenal hernia (PDH) represents the most common type of congenital internal hernia. It can be asymptomatic, causes chronic abdominal pain or presents with acute intestinal obstruction. The diagnosis of this congenital malformation is often made during surgical intraoperative exploration for intestinal obstruction. All surgeons should be familiar with the anatomy, pathophysiology and surgical

treatment of the condition. Early diagnosis of the condition can reduce the morbidity and mortality associated with late presentation. We present a middle aged lady with LPDH presenting as acute intestinal obstruction.

CASE SUMMARY

A 47 year old lady presented with complaint of pain on left side of abdomen with abdominal distension for 3 days with obstipation and bilious vomiting for 1 day. She had history of on and off left sided abdominal discomfort and

Left Paraduodenal Hernia-A diagnostic dilemma

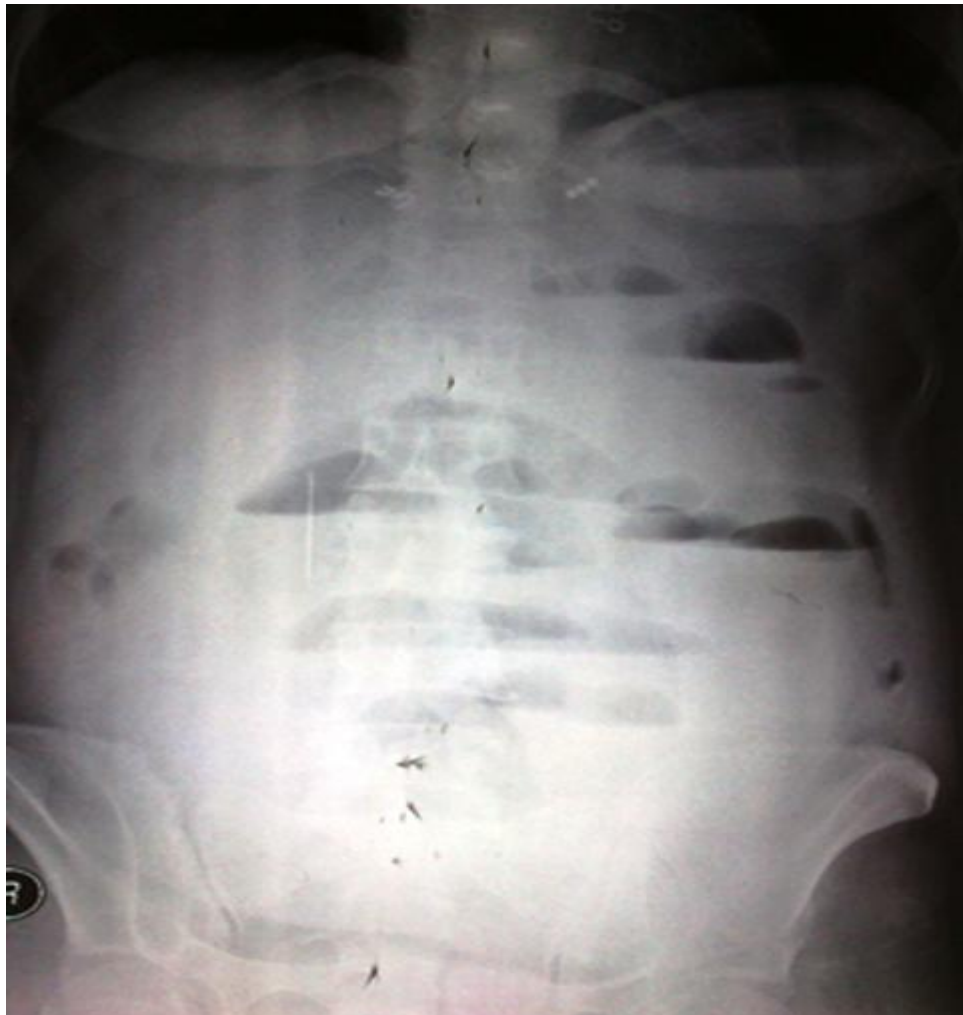constipation for past 6 months. She was a known diabetic for past 20 years on oral hypo-glycaemic agents.

On examination, abdomen was distended with fullness seen over left flank region, a soft, tender lump was felt in the left flank extending to the left hypogastrium and left iliac regions. Bowel sounds were sluggish. Digital rectal examination revealed hollowed empty rectum. Patient had tachycardia (110 /min) with BP 100/ 60 mm Hg

and rest systemic examination was within normal limits.

On investigation, x-ray abdomen erect showed multiple air fluid levels restricted to the midline and to the left (Fig 1). She was managed with provisional diagnosis of acute intestinal obstruction keeping her NPO, with IV fluids and NG aspiration and was planned for emergency exploratory laparotomy.

Figure 1: X- ray abdomen erect



Left Paraduodenal Hernia-A diagnostic dilemma

On exploration, 500 ml of turbid peritoneal fluid was aspirated, with dilated proximal jejunum and rest jejunal loops and proximal ileum seen herniating through an internal defect found behind the inferior mesenteric vein and the descending mesocolon (Fig 2,3,4). The herniated bowel loops were reduced by opening the neck of the hernia inferiorly and gently withdrawing the bowel loops. The herniated bowel loops were inflamed but were viable. The retro mesocolic space (fossa of Landzert) was obliterated with transmesocolic sutures using 3-0 polyglactin interrupted sutures. The patient had an unremarkable postoperative recovery and follow-up.

Figure 2: Intra Op view 1

A: Herniated small bowel loops seen through the descending mesocolon;

B: Proximal dilated jejunal loop; C: Transverse Colon

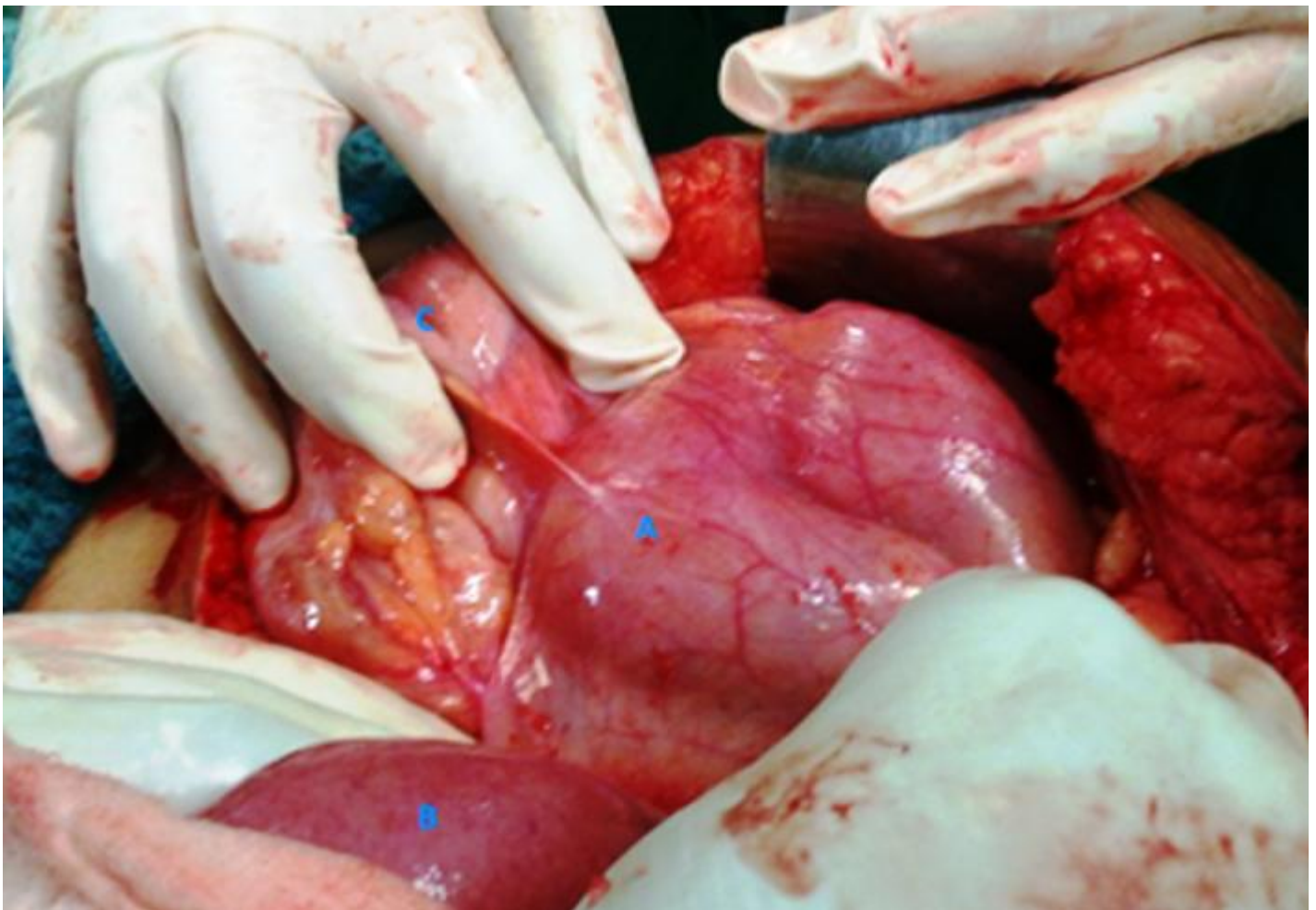


Figure 3: Intra op view 2

A: herniated small bowel seen through descending mesocolon;

B: Left colic artery;

C: Dilated proximal jejunal loops;

D: Inferior mesenteric vein seen coursing through the anterior boundary of neck of hernia defect

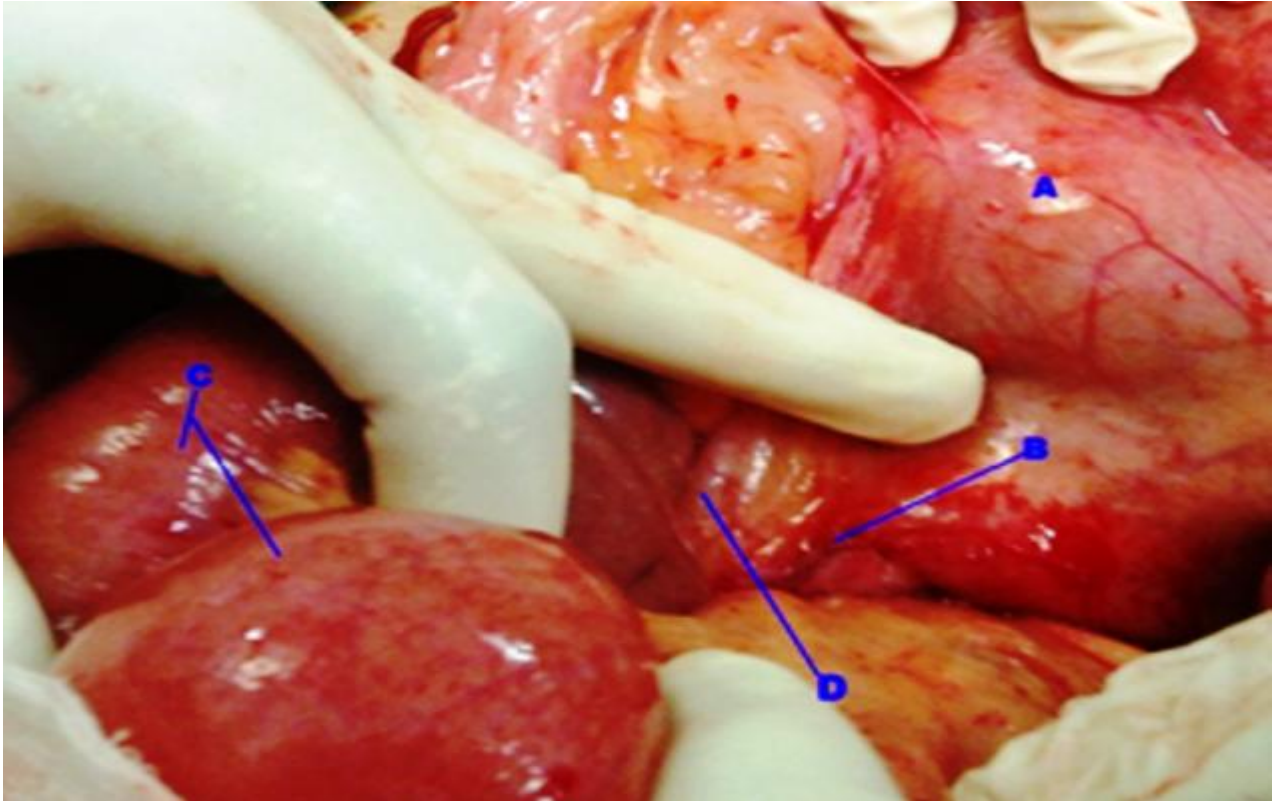
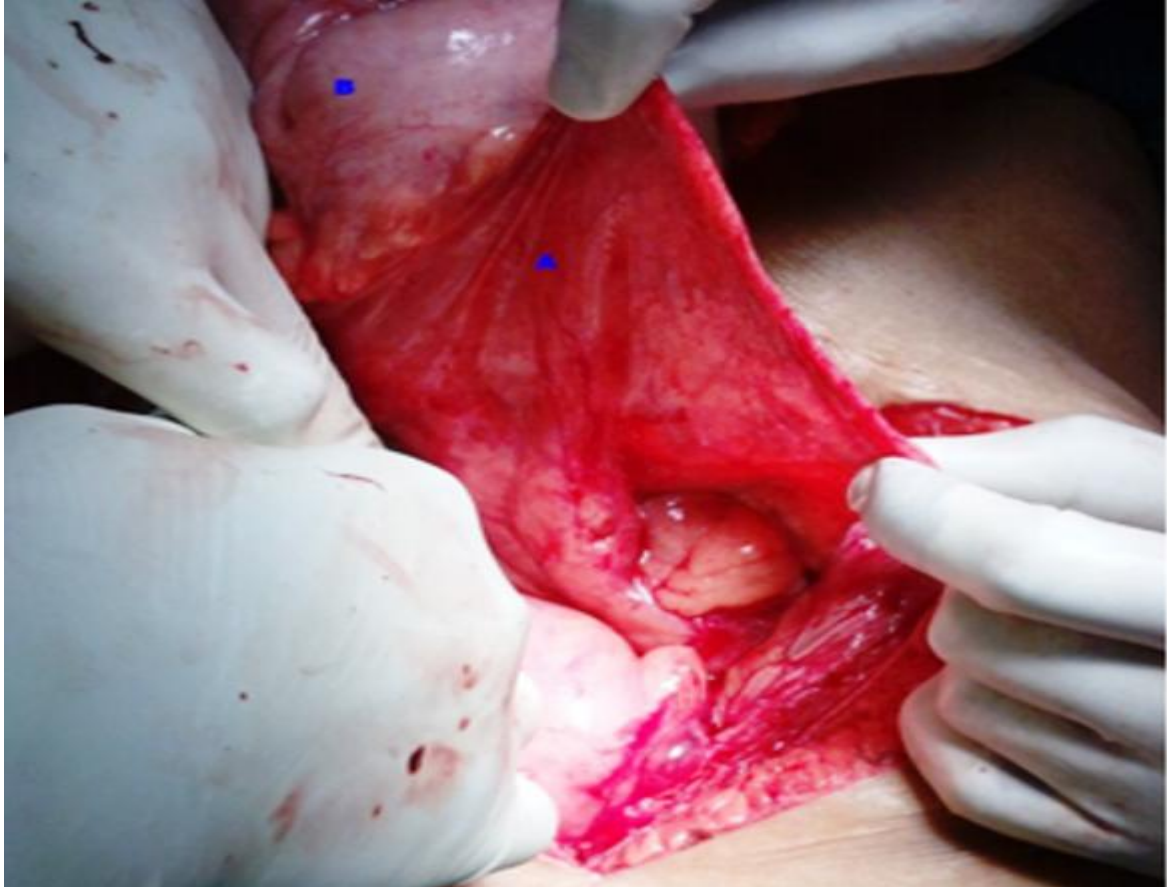

Figure 4: Intra Op view 3

A: Anterior wall of hernia sac; B: Transverse colon

**DISCUSSION**

Para-duodenal hernias are the most common type of internal hernia, accounting for approximately 53% of all cases and are more frequent in men (3: 1) ^[1, 2,3]. Left para-duodenal Hernia accounts for 75% of all para-duodenal hernias ^[1,3]. In large autopsy series the prevalence of PDH has been reported between 0.02 and 0.2% however it might be higher as suggested by a recent retrospective review of 294 upper gastrointestinal X-ray series that revealed PDH in 2% of the reviewed cases ^[10, 11].

LPDH occurs through the fossa of Landzert (present in 2% of general population ^[4]) whose mouth opens to the right and the fossa is directed towards left in the retroperitoneal space behind the left mesocolon. The boundaries of the sac are: *anteriorly*- inferior mesenteric vein, left colic artery; *superiorly*- duodeno-jejunal flexure, pancreas, left renal vein; laterally- aorta on right and left kidney on left side; a downward incision of the ring usually avoids injury to the inferior mesenteric vein ^[5]. Small bowel loops prolapse postero-inferiorly through the fossa to the left of

Left Paraduodenal Hernia-A diagnostic dilemma

the fourth part of the duodenum into the left portion of the transverse mesocolon and descending mesocolon.

Clinical Features of LPDH like other internal hernias include nausea, vomiting (especially after a large meal), and recurrent intestinal obstruction. In addition, these patients will also often present with postprandial pain, typically chronic in nature, with symptoms dating back to childhood^[6]. Only around 50% of paraduodenal hernias present with SBO or bowel strangulation^[9].

On radiography or oral contrast studies, these hernias will present as an encapsulated circumscribed mass of a few loops of small bowel (usually jejunum) in the left upper quadrant, lateral to the ascending duodenum; these loops may have mass effect, depressing the distal transverse colon and indenting the posterior wall of the stomach^[6].CECT may reveal mesenteric vessel abnormalities, including enlargement, stretching, and anterior displacement of the main mesenteric trunks, especially the inferior mesenteric vein, to the left^[7,8].

Management is surgical: both laparoscopic and open approaches can be adopted. In early uncomplicated presentations diagnosed preoperatively, laparoscopic approach is a

preferred option. There are many case reports supporting the safety of laparoscopic approach in the treatment of para-duodenal hernias^[9, 12]. However if the diagnosis is equivocal and cannot be confirmed preoperatively as encountered in complicated cases presenting as intestinal obstruction then a open approach is the best option^[13]. In our case, as patient presented with acute intestinal obstruction with no confirmed pre-operative diagnosis, an open laparotomy was done.

Aims of surgical correction should be: reduction of bowel contents without damaging the inferior mesenteric vein in case of left paraduodenal hernias and obliteration of the hernial defect. The constricting ring cannot be divided in paraduodenal hernias due to the presence of an important vessel in the free edge of the fold. In such cases the bowel contents need to be aspirated in order to reduce the volume of their contents to enable reduction. In case of strangulation resection anastomosis is the only option^[14]. Early diagnosis of the condition can result in a planned laparoscopic repair of the hernia with lesser morbidity/ mortality in comparison to late presentation with acute abdomen.

REFERENCES

1. Ghahremani GG. Abdominal and pelvic hernias. In: Gore RM, Levine MS, eds. *Textbook of*

gastrointestinal radiology, 2nd ed. Philadelphia, PA: Saunders, 2000:1993–2009

Left Paraduodenal Hernia-A diagnostic dilemma

2. Newsom BD, Kukora JS. Congenital and acquired internal hernias: unusual causes of small bowel obstruction. *Am J Surg* 1986; 152:279–284
3. Blachar A, Federle MP. Internal hernia: an increasingly common cause of small bowel obstruction. *Semin Ultrasound CT MR* 2002; 23:174–183
4. Lucie C. Martin, Elmar M. Merkle, William M. Thompson. Review of Internal Hernias: Radiographic and Clinical Findings. *AJR* 2006; 186:703–717
5. John Elias Skandalakis, Gene L. Colborn. Skandalakis' Surgical anatomy: the embryologic and anatomic basis of modern surgery, Volume 2. Page 131
6. Meyers MA. Dynamic radiology of the abdomen: normal and pathologic anatomy, 4th ed. New York, NY: Springer-Verlag, 1994
7. Blachar A, Federle MP, Brancatelli G, Peterson MS, Oliver JH 3rd, Li W. Radiologist performance in the diagnosis of internal hernia by using specific CT findings with emphasis on transmesenteric hernia. *Radiology* 2001; 221:422–428
8. Nishida T, Mizushima T, Kitagawa T, Ito T, Sugiura T, Matsuda H. Case report: unusual type of left paraduodenal hernia caused by a separated peritoneal membrane. *J Gastroenterol* 2002; 37:742–744
9. Palanivelu C, Rangarajan M, Jategaonkar PA, Anand NV, Senthilkumar K. Laparoscopic repair of paraduodenal hernias: mesh and mesh-less repairs. A report of four cases. *Hernia* 2008; 12: 649-53.
10. Jeong GA, Cho GS, Kim HC, Shin EJ, Song OP. Laparoscopic repair of paraduodenal hernia. Comparison with conventional open repair. *Surg Laparosc Endosc Percutan Tech* 2008; 18: 611-5.
11. Yoo HY, Mergelas J, Seibert DG. Paraduodenal hernia. A treatable cause of upper gastrointestinal tract symptoms. *J Clin Gastroenterol* 2000; 31: 226-9.
12. Finick CM, Barker S, Simon H, Marx W. A novel diagnosis of left paraduodenal hernia through laparoscopy. *Surg Endosc* 2000 Jan; 14(1): 87.
13. Jeong GA, Cho GS, Kim HC, Shin EJ, Song Op. Laparoscopic repair of paraduodenal hernia: comparison with conventional open repair. *Surg Laparosc Endosc Percut Tech*. 2008 Dec; 18(6): 611-5.
14. Brigham Ra, Fallon WF, Saunders JR, Harmon JW, d' Avis JC. Paraduodenal Hernia: diagnosis and surgical management. *Surgery* 1984 Sep; 96(3): 498-502.
15. Mathias J, Bruot O, Ganne P A, Laurent V, Regent D. Hernies internes. EMC Radiodiagnostic - Appareil digestif 33-015-A-37-2.