

Neuroendocrine carcinoma of kidney: A Case report

Kinra Prateek¹, Agarwal DC², Blessy D³, Mutreja D⁴, Alam A⁵, Tewari V⁶

ABSTRACT

It is hypothesised that neuroendocrine carcinoma of kidney arises from totipotent neural crest cells. Clinically the secreting type of tumours can present with flushing and diarrhoea initially. On imaging it is not possible to diagnose this condition as it is identical to clear cell renal cell carcinoma. It is important for pathologists to diagnose this entity as it might require intra-arterial chemotherapy post-surgery. Due to paucity of literature on this entity, the clinical outcome is exactly not clear.

Key words: immunohistochemistry, Neuroendocrine carcinoma kidney

Associate Professor¹, Commandant², Junior Resident³, Asst Prof⁴, Professor & HOD⁶,

Department of Pathology, Command Hospital Air Force, Bangalore, India

Professor & HOD⁵, Dept. Of Radiology; Command Hospital Air Force, Bangalore, India

Corresponding author mail: pkinra_in@yahoo.com

Conflict of interest: Nil

INTRODUCTION

Neuroendocrine tumours (NET) can rarely occur in kidneys. NET of the kidney are unusual because neuroendocrine cells are not found within normal renal parenchyma. The first reported case of a renal carcinoid tumor was over 40 years ago. Ever since, less than 100 cases have been reported in the English language literature¹. The clinical behaviour of renal NETs remains unclear due to the rarity of these lesions. Earlier studies indicated these tumours to arise from neural crest, however more recent studies have demonstrated that a few have embryologic origin from the neuroectoderm².

NETs represent a wide spectrum, including well-differentiated NET (carcinoid), well-differentiated neuroendocrine carcinoma (WDNC), poorly differentiated neuroendocrine carcinoma (large cell neuroendocrine carcinoma (LCNEC), and small cell carcinoma (SCC)³. Carcinoids are typically slow-growing, may secrete hormones, and may follow a variable clinical course. In contrast, the WDNC, LCNEC & SCC usually presents with locally advanced or metastatic disease and carry a grave prognosis. We report a case of well differentiated neuroendocrine carcinoma. The biological behaviour of these tumors ranges over a spectrum, and

can only be judged accurately by their metastatic tendency.

CASE REPORT

A 41 year old lady presented to urology clinic with dull aching pain in the right loin for duration of 3 months. There was no history of hematuria, dysuria or

fever. On imaging (CECT Abdomen) the patient was detected to have well defined heterogeneously enhancing mass (precontrast HU42, post contrast HU61) seen in the superior pole of right kidney measuring 7.2x6.3x7.5 cm (Figure No. 1a).

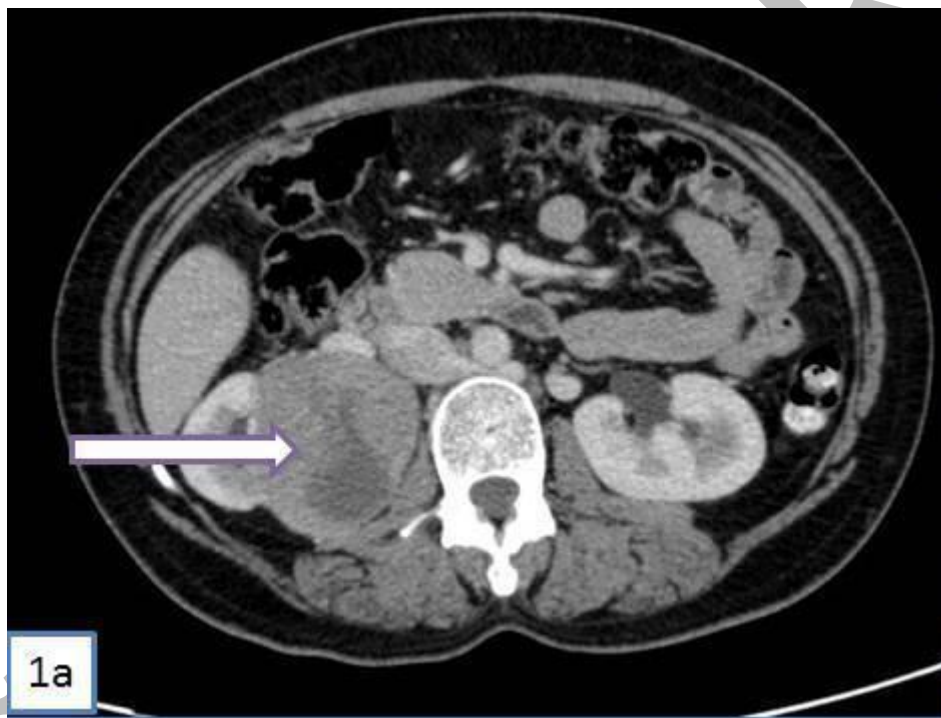

Figure No. 1a: CECT Abdomen: Well defined heterogeneously enhancing mass (pre-contrast HU42, post contrast HU61) seen in the superior pole of right kidney.

The lesion showed necrosis and small foci of calcification. The mass was infiltrating the right renal artery. No thrombus was visualised in the renal vein. Adrenal could be identified separately. Perilesional lymph nodes measured 14mm in greatest dimension. Liver also showed 3 lesions, subcentimetric hypoenhancing in

segment VII, VIII and IV. Multiple well defined nodules were seen in the basal segments of both the lungs.

The patient was taken up for right nephrectomy with a radiological diagnosis of renal cell carcinoma with metastatic disease in livers/lungs and spread to right renal artery. The mass on grossing in

superior pole of kidney measured 8x7 x6.5 cm extending into hilum (Figure No. 1b).

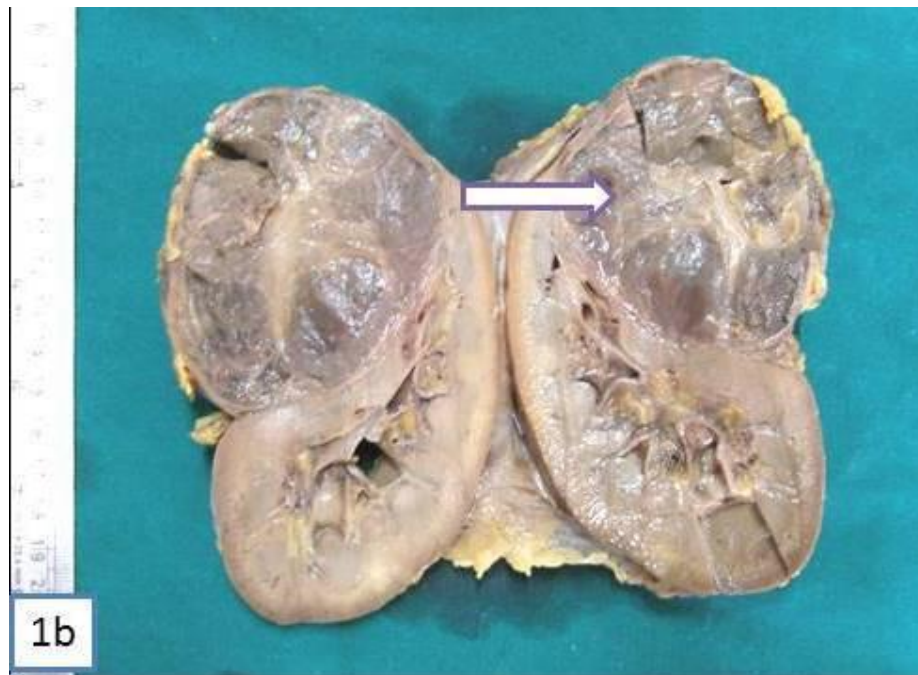

Figure No. 1b: Grey coloured tumour in the superior pole kidney with areas of necrosis

The cut section of tumour was hemorrhagic, friable with fibrous septae. Gerota's fascia was adherent to the tumour. The tumour was seen extending into renal artery. Microscopic examination of the tumour showed ribbons festoons, papillae and nests of medium sized cells with amphophilic cytoplasm and nuclei showing salt and pepper chromatin (Fig No. 1c & d).

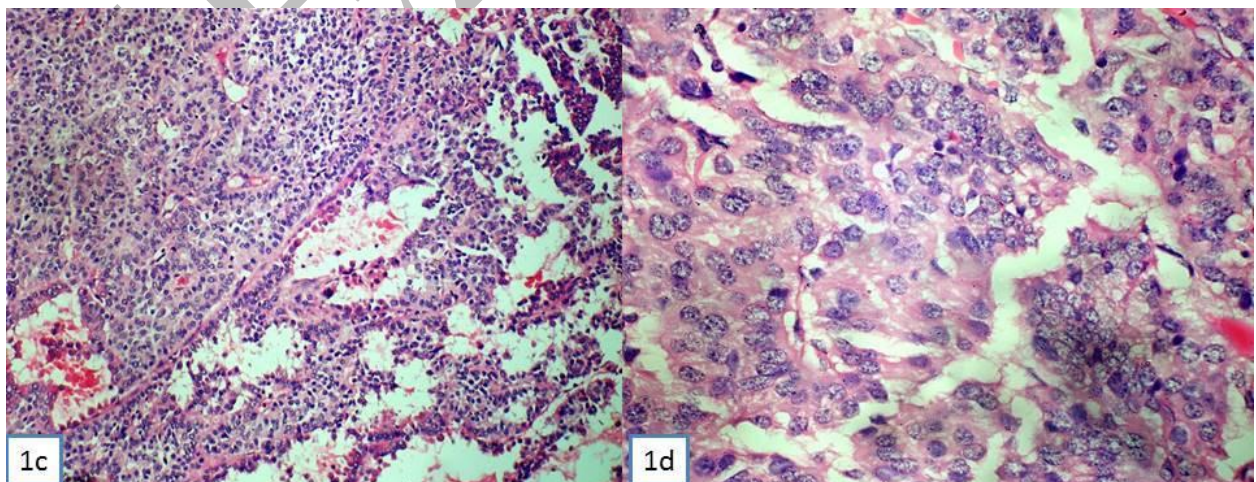


Figure No. 1c: Festoons and ribbons of small cells with eosinophilic cytoplasm (HE -40X);
1d: Salt and pepper chromatin, eosinophilic granular cytoplasm and mitotic figures (HE
400X)

Few nuclei showed prominent nucleoli and grooving. Mitotic index was 6-7/ high power field. No psammoma bodies seen. The tumour was reaching upto Gerota's fascia but not invading it. Background showed coagulative necrosis and hemorrhage. Sections from renal artery showed tumour thrombus.

Immunohistochemically the tumour was positive for Synaptophysin, Neuron Specific Enolase, Vimentin and negative for CK7, CK20, Chromogranin and CD10 (2a-d). The Ki67 index was 25%. The final diagnosis offered was well differentiated neuroendocrine carcinoma of the kidney.

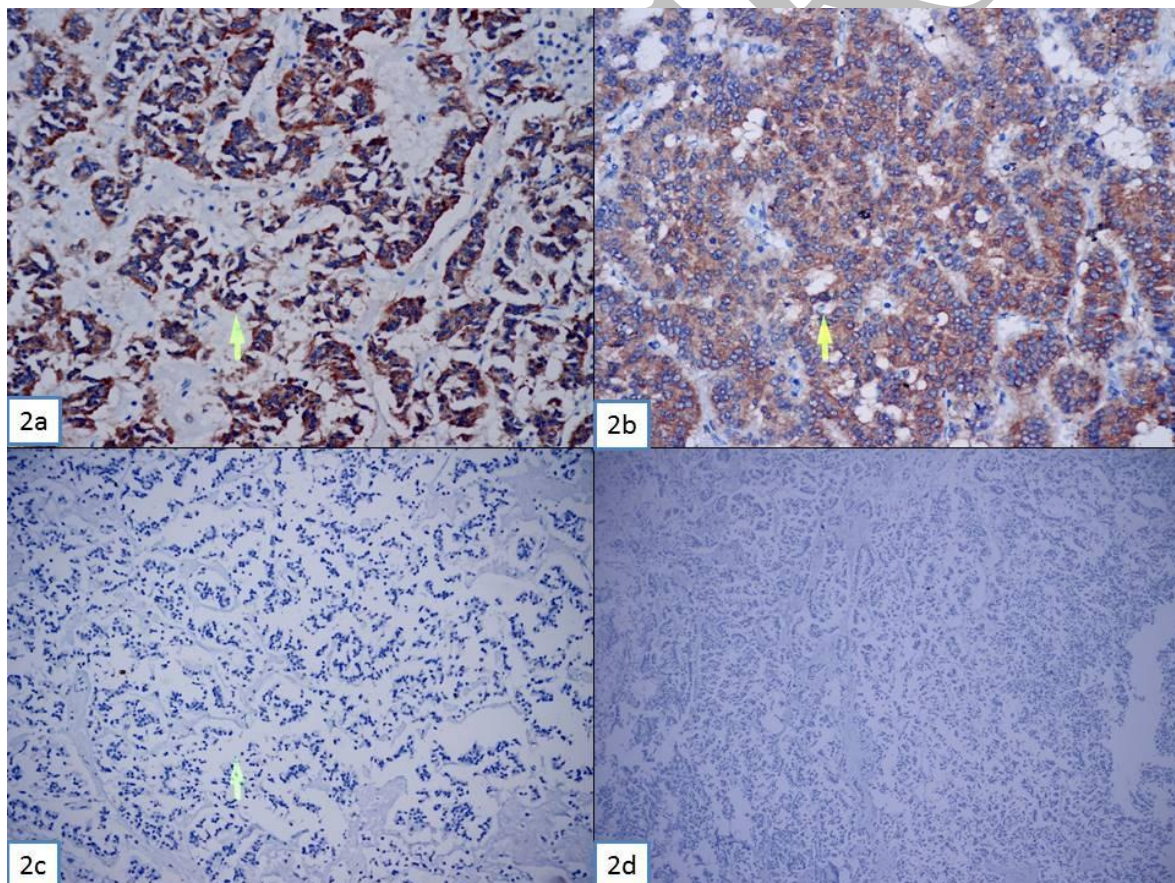


Figure No. 2a: Immunohistochemistry Synaptophysin +ve (100X); 2b: NSE +ve (100X); 2c: CD10 -ve (40X); 2d: CK 7 -ve (40X)

DISCUSSION

Neuroendocrine cells have been identified in the renal pelvis but not in the normal renal parenchyma [4]. Various theories support the fact that NETs arise from totipotent stem cells that further differentiates towards neuroendocrine path. Several theories have been used to explain the origin of such tumors, including metastasis from an unknown primary tumor site to the kidney, activation of aberrant gene sequences (loss of heterozygosity at one locus on Chromosome 3p21) and concurrent renal congenital abnormalities like horseshoe kidney and teratomas^{4,5}. The peak age of incidence for NET is between the fifth and sixth decades. Patients with renal NET beyond the age of 40 years had a poor outcome⁴.

In the largest study on NET of kidneys by Lane et al the incidence of neuroendocrine tumours of kidney was 9 in 2780 kidney tumours. The 9 cases included 6 carcinoids, two well differentiated neuroendocrine carcinoma and one large cell neuroendocrine carcinoma⁶.

The carcinoid tumours are generally silent for years before being detected. A diagnosis of non secreting NET of kidney is challenging as it presents as a renal mass like other renal tumours.

Secreting tumours are still thought of if a patient of renal mass has symptoms of flushing dyspnoea or diarrhoea. The tumour can also secrete ACTH, intestinal peptide or glucagon. Our case had no clinical features suggesting secreting NET. On imaging NET show no to minimal enhancement, heterogeneity, and calcifications. These findings are neither sensitive nor specific for renal NET and cannot distinguish these tumors from renal cell carcinomas⁷.

The size of carcinoids averaged to 4.8 cm whereas the carcinoma averaged to 12 cm. The index case had a maximum dimension of 8cm. The small cell and large cell neuroendocrine tumours unlike carcinoid showed haemorrhage and necrosis⁸. Grossly and microscopically the case discussed showed necrosis and hemmorrhage.

Nephrectomy forms the main stay of treatment for low grade NET. 47 % of low grade NET had a disease free survival of 43months⁵. Often the NEC presents with distant metastasis. In this scenario intra-arterial chemotherapy needs to be added for management⁹.

CONCLUSION

Neuroendocrine tumours of renal parenchyma are rare. They commonly mimic the clear cell renal cell carcinoma on imaging. It is important to distinguish

the two from therapeutic point of view. The diagnosis of neuroendocrine tumours especially the carcinoma requires awareness and the pathologists should judiciously use neuroendocrine immunohistochemistry to confirm the same.

REFERENCES

1. Shurtleff BT, Shvarts O, Rajfer J. Carcinoid tumor of the kidney: Case report and review of the literature. *Rev Urol.* 2005;7: 229–33.
2. DeLellis RA, Osamura RY. Neuroendocrine tumors: An overview. *Path Case Rev.* 2006; 11:229–34.
3. Oberg K. Neuroendocrine tumors of the gastrointestinal tract: Recent advances in molecular genetics, diagnosis, and treatment. *Curr Opin Oncol.* 2005; 17:386–91.
4. el-Naggar AK, Troncoso P, Ordonez NG. Primary renal carcinoid tumor with molecular abnormality characteristic of conventional renal neoplasms. *Diagn Mol Pathol.* 1995; 4:48–53.
5. Romero FR, Rais-Bahrami S, Permpongkosol S, Fine SW, Kohanim S, Jarrett TW. Primary carcinoid tumors of the kidney. *J Urol.* 2006;176:2359–66.
6. Lane BR, Chery F, Jour G, Sercia L, Magi-Galluzzi C, Novick AC, Zhou M. Renal neuroendocrine tumours: a clinicopathological study. *BJU Int.* 2007 Nov;100(5):1030-5.
7. Mouloupoulos A, DuBrow R, David C, Dimopoulos MA. Primary renal carcinoid: Computed tomography, ultrasound, and angiographic findings. *J Comput Assist Tomogr.* 1991;15:323–5.
8. Lane BR, Jour G, Zhou M. Renal neuroendocrine tumours *Indian J Urol.* 2009 Apr-Jun; 25(2): 155–160.
9. Kawajiri H, Onoda N, Ohira M, Nakatani T, Wakasa K, Ishikawa T, et al. Carcinoid tumor of the kidney presenting as a large abdominal mass: Report of a case. *Surg Today.* 2004;34:86–9.