

Nasopalatine Cyst causing resorption of Teeth: A Case ReportPrashanthi C¹, Sujatha S Reddy, Pallavi Chauhan², Kuhu Majumadar³**ABSTRACT**

Nasopalatine duct cysts (NPDC) are the most frequently encountered developmental, epithelial, non-odontogenic cysts of the maxilla. It is commonly asymptomatic and often incidentally discovered on clinical and radiographic examination. We report a case of NPDC with varied clinical findings but with pathognomonic radiographic findings and rare resorption of root. A differential diagnosis of swelling in anterior maxilla has also been presented along with a review.

Keywords: Intramaxillary, Nasopalatine cyst, Nasopalatine duct, Resorption of teeth

¹Senior lecturer, ²Professor, ³PG Student,

Department of Oral Medicine and Radiology M.S. Ramaiah Dental College, Bangalore.

Corresponding author mail: drprashanthi.1@gmail.com

Conflict of interest: Nil

INTRODUCTION

The nasopalatine duct cyst (NPDC) was first described by Meyer in 1914.¹ It is also called as Incisive canal cyst and Elevator shaft cyst. In the past, known as the fissured cyst, now according to the WHO classification is defined as a non – odontogenic, developmental, epithelial cyst of maxilla.²

The nasopalatine duct communicates the nasal cavity with the anterior region of the maxilla. It is located on the midline and palatine to the maxilla, above the incisive papilla. During fetal development the duct gradually narrows until one or two central clefts are finally

formed on the midline of the maxilla. The nasopalatine neurovascular bundle is located within the duct, and emerges from its intrabony trajectory through the nasopalatine foramen. There can be as many as six different foramina, though there are usually only two, with independent neurovascular bundles (right and left).

The vascular and neuronal elements can emerge separately; in this sense, foramina containing exclusively vascular elements are known as Scarpa's foramina.³ The NPDC is unique in that it develops in only one location, which is the midline of the anterior maxilla, in close

relationship to the nasopalatine canal. It may occur in the nasopalatine canal or in the soft tissues of the palate, "Cyst of palatine papilla". NPDCs are the most common nonodontogenic cysts of the mouth, representing up to 1% of all maxillary cysts.⁴ These lesions are almost three times more frequent in males than in females.⁵ The maximum prevalence is between 40 and 60 years of age. In addition NPDC may also be at a risk for malignant transformation reinforcing the need for their detection and accurate diagnosis.

We report a case of NPDC with resorption of associated teeth with histo-pathological findings.

CASE REPORT

A 26 year old female patient reported to us with a complaint of a

swelling on her maxillary anterior palatal region since 8 months and dull, intermittent pain on eating food in that region since 2 months. The swelling had gradually increased to attain the present size and was not associated with any bleeding or pus discharge. She also gave history of her maxillary anterior teeth gradually moving from their position. There was no history of any trauma. There was no relevant medical or dental history reported by the patient.

Intraoral examination revealed a solitary, roughly ovoid swelling on anterior palatal region. It was roughly 1.5 cm in diameter cm in dimension. Left maxillary central incisor was inclined mesio-labially and was grade 1 mobile and tender (Figure 1). On palpation swelling was firm, tender and non fluctuant.

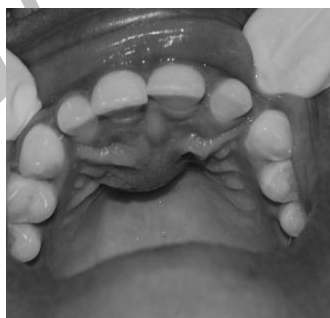

Figure 1: Showing mesio-labially inclined left maxillary central incisor.

A provisional diagnosis of infected periapical cyst in relation to the maxillary central incisors was given. Differential diagnosis of enlarged naso-palatine duct,

Nasopalatine cyst, Adenomatoid odontogenic tumor and Odontogenic cysts-keratocyst and dentigerous cyst associated with a mesiodens were considered.

Pulp vitality test revealed maxillary left central incisor was non vital. Intraoral periapical radiograph revealed a well-defined oval peri-apical radiolucency seen in right central incisor around 1X 1.5cms and approaching peri-

apical region of left central incisor with sharp blunting of apex of both central incisors which was indicative of resorption. Midpalatine suture was also well defined (Figure 2).

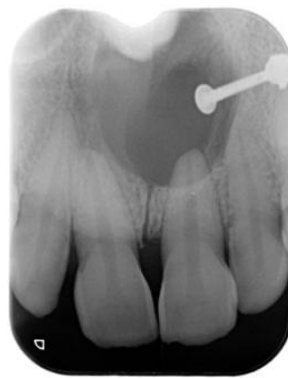

Figure 2: IOPAR showing well defined radiolucency with root resorption of maxillary central incisors.

Panoramic radiograph showed a well defined radiolucency extending in periapical region from maxillary incisors with distally inclined roots of left central incisor (Figure 3).

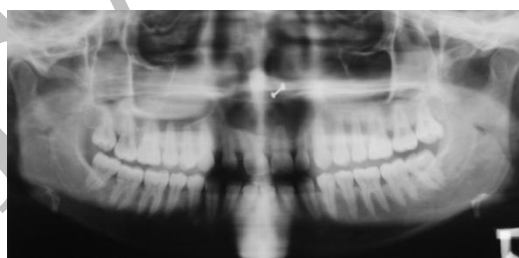


Figure 3: Panoramic radiograph showing well defined radiolucency in mid palatal region

Maxillary anterior topographic occlusal radiograph showed well defined periapical radiolucency in midline in the periapex of right central incisor (Figure 4.).

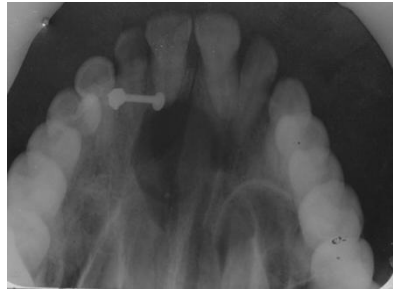

Figure 4: Maxillary topographic anterior occlusal radiograph showing well defined radiolucency

A radiographic diagnosis of periapical cyst irt to maxillary central incisor was given. FNAC revealed no aspirate and all blood investigations were normal.

Enucleation was performed and specimen was sent for histopathological examination which revealed it to be an infected nasopalatine duct cyst with non-keratinized stratified squamous epithelium

and stroma shows numerous neurovascular bundles and moderately dense diffuse chronic inflammatory cell infiltrate, chiefly composed of phagocytes and plasma cells (Figure 5) and (Figure 6). Patient is under follow up.

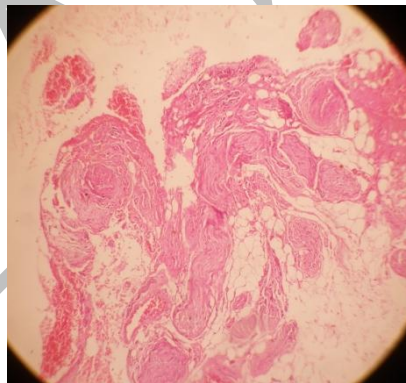


Figure 5:10X Photomicrograph showing neurovascular bundles

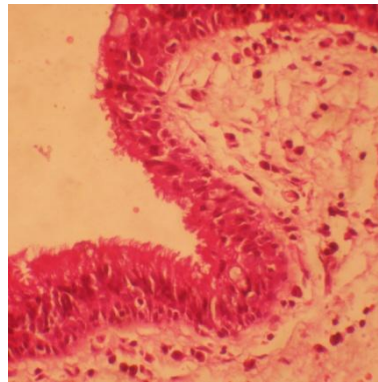


Figure 6: 40 X photomicrograph showing chronic inflammatory cells

DISCUSSION

The nasopalatine duct cyst is a developmental cyst derived from proliferation of embryonic epithelial remnants of the nasopalatine duct. It may occur at any age but it is seen most often in fourth to sixth decades of life, though there have been reports of NPDCs in pediatric patients up to 8 years of age.^{4,6} The cause of nasopalatine duct cyst is essentially unknown. Trauma, infection, and mucous retention within associated salivary gland ducts have all been suggested as possible pathogenetic factors; however, most believe that spontaneous cystic degeneration of residual ductal epithelium is the most likely etiology.

In the reported case there was no history of trauma, therefore it is likely for the cyst to have been caused by spontaneous development. Nasopalatine duct cysts (NPDCs) are almost three times more common in males than in females^{1,5},

and show a predilection for Caucasian individuals.⁷

As regards to race, the findings are controversial; since some studies report the same incidence in both negroes and whites^{1,2} and any difference between them may be attributable to lesser economical resources among the former.⁷

Most of the cysts are asymptomatic and constitute casual findings.⁶ Large cysts may present with a multitude of symptoms ranging from pain, anterior palatal/labial swelling, discharge, itching, ulceration, local infection and/or fistulisation⁸. In our case slight tenderness was observed. Interestingly, patients with small lesions may present with disproportionately severe symptoms, while those with large cysts manifest few or no symptoms.⁹

Nasopalatine duct cysts commonly present centrally or unilaterally with no predilection for the side of occurrence.

A rare case of bilateral nasopalatine ductcysts has been reported by Cicciu et al in a 35 year old black man¹⁰. On rare occasions, larger cysts may result in a 'through and through' fluctuant expansion of the labial alveolar mucosa and anterior hard palate.¹¹ An uncommon case of amassive NPDC with nasolabial protrusion has been reported by Tanaka et al.¹¹ When the cyst extends anteriorly amidst the maxillary central incisor roots, the term 'median alveolar cyst' is employed.¹² However, the term 'median palatal cyst' is used when the cyst expands posteriorly into the hard palate.¹²

Radiographically, the cyst presents as a well-delineated rounded, ovoid, inverted pear-shaped or heart-shaped radiolucency in the mid-line of the anterior maxilla. Superimposition of the anterior nasal spine explains the heart-shape presentation of the lesion. A diameter greater than 6 mm of the incisive foramen is usually consistent with a NPDC. The NPDC present with an average diameter of 1.5 to 1.7 cms with an inter-gender difference in mean diameter of 4 mm.⁸

Panoramic/periapical/occlusal radiographs, computed tomography and magnetic resonance imaging may aid in establishing a diagnosis of NPDC.^{12,13} T1W1 images of NPDC depict a high

signal intensity owing to presence of keratin and viscous fluids.¹³ Histological examination of NPDC may reveal squamous/cuboidal/ciliarcylindrical/stratified/pseudostratified epithelial cells, goblet cells and ample inflammatory infiltrate within the cyst lumen.⁸ The presence of melanin has been documented in one reported case.¹⁴

Large cysts may cause divergence and rarely smooth, regular resorption of the maxillary central incisors and their roots.¹⁵ In our case also rare resorption of central incisors was seen. Treatment modalities for NPDC include surgical excision, marsupialization and electro coagulation.¹⁴ Owing to malignant transformation of NPDC, some authors recommend a radical en bloc resection of the anterior maxilla.^{12,15} Recurrence is infrequent and has been reported in 11% of the patients.¹²

CONCLUSION

The purpose of writing this article is to lay emphasis on unusual causes of swelling, pain and teeth resorption in anterior hard palate. Dental practitioners should be aware of the possibility of NPDC and its differentiation from an enlarged incisive canal.

REFERENCES:

1. Vasconcelos R, De Aguiar MF, Castro W, De Araújo VC, Mesquita R. Retrospective analysis of 31 cases of nasopalatine duct cyst. *Oral Dis.* 1999;5(4):325-8.
2. Herráez-Vilas JM, Gay-Escoda C, Berini-Aytés L. Quiste del conductonasopalatino. Revisión de la literatura y aportación de 14 casos. *Rev EurOdonto-Estomatol.* 1994;6(4):231-6.
3. Moss HD, Hellstein JW, Johnson JD. Endodontic considerations of the nasopalatine duct region. *J Endod.* 2000;26(2):107-10.
4. Ely N, Sheehy EC, McDonald F. Nasopalatine duct cyst: a case report. *Int J Paediatr Dent.* 2001;11(2):135-7.
5. Gnanasekhar JD, Walvekar SV, Al-Kandari AM, Al-Duwairi Y. Misdiagnosis and mismanagement of a nasopalatine duct cyst and its corrective therapy. A case report. *Oral Surg Oral Med Oral Pathol Oral RadiolEndod.* 1995;80(4):465-70.
6. Velasquez-Smith MT, Mason C, Coonar H, Bennett J. A nasopalatine cyst in an 8-year-old child. *Int J Paediatr Dent.* 1999 Jun;9(2):123-7.
7. Swanson KS, Kaugars GE, Gunsolley JC. Nasopalatine duct cyst: an analysis of 334 cases. *J Oral Maxillofac Surg.* 1991 Mar;49(3):268-71.
8. Neville, Damm, Allen, Bouquot. *Oral and Maxillofacial Pathology.* 2nd edition. New Delhi: Elsevier, 2002.
9. Shafer, Hine and Levy. *A textbook of oral pathology.* Fourth edition, Pennsylvania, Elsevier, 2003.
10. Cicciu M et al. Rare Bilateral Nasopalatine Duct Cysts: A case report. *The Open Dentistry Journal,* 2010, 4, 8-12.
11. Tanaka S, Iida S, Murakami S, Kishino M, Yamada C and Okura M. Extensive nasopalatine duct cyst causing nasolabial protrusion. *Oral Surg Oral Med Oral Pathol Oral RadiolEndod* 2008; 106:e46-e50
12. De Cuyper K, Vanhoenacker F M, Hintjens J, Verstraete K L, Parizel P M. Nasopalatine duct cyst – Images in Clinical Radiology, *JBR-BTR,* 2008, 91: 179.
13. Hisatomi M, Asaumi J, Konouchi H, Matsuzaki H, Kishi K. MR imaging of nasopalatine duct cysts. *European Journal of Radiology* 39 (2001) 73-6.
14. Francoli J E, Marques N A, Aytes L B, Escoda C G. Nasopalatine duct cyst: Report of 22 cases and review of the literature. *13(7):E438-43.*
15. Images in clinical radiology, *JBR–BTR,* 2008, 91: 179.

SEAJCRR