

Malignant Transformation of Cutaneous Lichen Planus: Case Report

Dr. Munlima Hazarika¹, Dr. Anupam Sharma², Dr. B. B Borthakur³, Dr. Mouchumi Bhattacharyya⁴

ABSTRACT

Background: Lichen planus is a chronic mucocutaneous T-cell-mediated disease, the cause of which remains unknown. Malignant transformation in the cutaneous lesions of Lichen Planus is a rare occurrence and should be kept in mind while treating such lesions.. Epidemiological studies from the last 20 years have revealed a malignant transformation rate of 0.27% per year, emphasizing the importance of the clinical follow-up of lichen planus patients, to ensure an early diagnosis and treatment in the initial stage. **Case report:** We report a 17 year female who developed a squamous cell carcinoma in a long standing hypertrophic lichen planus in the left thigh. **Conclusion:** A high degree of suspicion is necessary whenever we come across a non-healing lesion in a patient with lichen planus.

Keywords: Cutaneous lichen planus; squamous cell carcinoma

¹Department of Medical Oncology, ²Department of Pathology, ³Department of Surgical oncology, ⁴Department of Radiation Oncology

Dr. B. Borooah Cancer Institute. Guwahati, Assam, India.

Corresponding author mail: dranupamsarma@gmail.com

Conflict of interest: None and confirmed the case was recruited for this study with informed consent and approved by appropriate institutional authority.

INTRODUCTION

Lichen planus (LP) is a mucocutaneous disease, affecting about 1-2% of the population, characterized by nonspecific chronic inflammatory process which leads to an intense destruction of the basal layer of the epithelium. It can affect the oral mucosa, skin, nails and genitalia.

Neoplastic transformation in lichen planus has been described, especially in the oral form of the disease where an estimated 0.3-3% of patients may develop squamous cell carcinoma. Malignancy though uncommon with cutaneous lichen planus, has been described in chronic hypertrophic lesions of lichen planus on the legs. [1-3]

CASE REPORT

We describe a 17 year old female, who presented to our Out Patient Department in September, 2013 with a non-healing ulcer on her left thigh which had been present for approximately 6 months. She was diagnosed as having hypertrophic variant of lichen planus 11 years back for which she has been receiving treatment irregularly with salicylate and betamethasone from several dermatologists with partial response.

On examination multiple raised pigmented verrucous plaques on thighs, dorsum, shins and ankles of both her legs, flexural areas of the wrists, the elbows, neck, chest and back were found with areas of depigmentation in some lesions. An ulcero-proliferative lesion measuring approximately 6cms x 5cms x 2cms was present on the medial aspect of her left thigh (Figure 1).

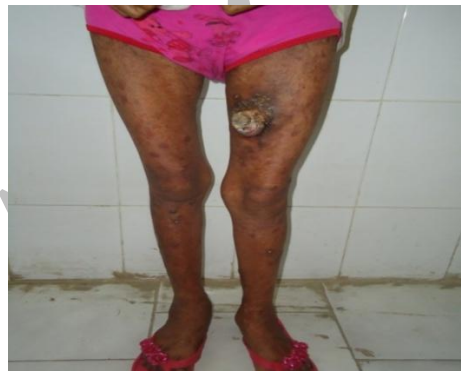

Figure 1: Cutaneous lichen planus on the medial aspect of left thigh.

This was tender, soft to firm in consistency and with a raised everted keratotic edge. Ulcer floor was hypertrophic, covered with slough and bled on

manipulation. The surrounding skin was lichenified, keratotic and pigmented. Other parts of the body had post inflammatory changes at sites of earlier lesions (Figure 2).

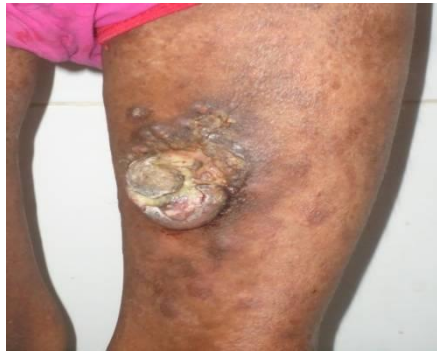

Figure 2: Ulcero-proliferative lesion with a raised everted keratotic edge, surrounding skin is lichenified and pigmented.

The histopathological examination of the ulcer biopsy confirmed diagnosis of well differentiated squamous cell carcinoma with atypical squamous epithelium and keratinization (Figure 3).

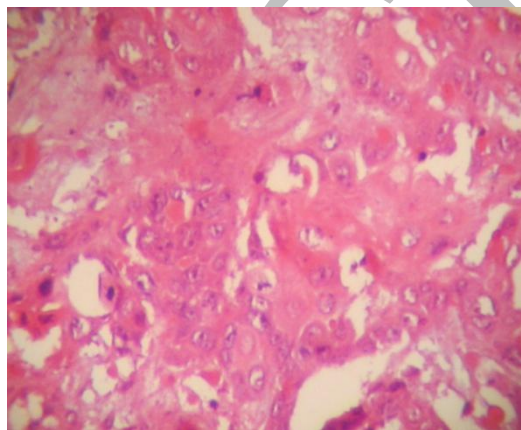


Figure 3: Photomicrograph showing well differentiated squamous cell carcinoma (H&E.400x).

The regional lymph nodes were normal on physical examination. Buccal mucosa, nails and hair were unaffected. The general physical examination and systemic examination of the patient were

unremarkable. All the laboratory findings were within normal limit. Patient is now planned for wide local excision followed by full thickness skin grafting

DISCUSSION

Hypertrophic lichen planus (LP) is a chronic variant of lichen planus characterized by hypertrophic or warty

lesions most often found on the pretibial area of the lower limbs. [2, 4, 5]

Malignant transformation of LP of the skin is very rare, as compared to malignant

transformation of lichen ruber of the mucous membranes of the mouth. In an epidemiological study by Sigurgeirsson et al. amongst 2071 cases of LP only 6 cases developed cutaneous Squamous Cell Carcinoma (SCC) during 9.9 years of follow up. [2] There are reports of a few such cases from India where the patients with long standing LP underwent malignant change. [1, 3, 7, 8]

SCC is more frequently found among patients with hypertrophic LP than in those with plain lesions. [6] It has been observed that the lesions with areas of depigmentation are likely to transform into carcinoma. [3] Depigmentation was present in our case too. Another common feature of all cases reported so far in literature is the presence of the lesions in the legs as in our case. Hence such cases must be followed up closely so that early diagnosis and timely intervention is feasible.

Histopathology in such lesions shows hyperkeratosis, acanthosis, papillomatosis and hypergranulosis. [9, 10] Our patient had a well-differentiated SCC developed in the preexisting hypertrophic LP lesions over left thigh. The association between LP and SCC is not well explained. Several authors have indicated that the

association may be due to the fact that the risk factors and underlying pathogenesis of both the diseases is similar.

Several other factors such as immune alterations associated with LP, treatment with arsenical or ionizing / ultraviolet radiation and chronic inflammation along with the accelerated cellular turnover may also be responsible for development of SCC in patients suffering from LP. [11, 12, 13, 14, 15, 16, 17] The common occurrence of the lesions on the legs can be explained by the fact that patients with pruritic and chronic dermatosis tend to scratch their legs more often and more intensely, causing chronic inflammation, which is a well established risk factor for carcinogenesis. [6]

CONCLUSION

Although malignant transformation of cutaneous lichen planus is not very common but we should always consider any abnormal skin presentation in a preexisting lichen planus lesion with great suspicion, especially in lower limbs and perform biopsy to rule out squamous cell carcinoma.

REFERENCES

1. Rahul Shetty, ShashankLamba, ArchanaGulur, Sapna Patel, Ashish Kumar Gupta: Carcinoma in cutaneous

- Lichen Planus. *Our Dermatol Online*. 2013; 4(1): 75-77
2. Sigurgeirsson B, Lindelöf FB: Lichen planus and malignancy. An epidemiologic study of 2071 patients and a review of the literature. *Arch Dermatol*. 1991;127:1684-6.
 3. Jayaraman M, Janaki VR, Yesudian P: Squamous cell carcinoma arising from hypertrophic lichen planus. *Int J Dermatol*. 1995;34:70-1.
 4. Kaplan B, Barnes L. Oral lichen planus and squamous carcinoma. Case report and update of the literature. *Arch Otolaryngol*. 1985; 111:543–547.
 5. Marder MZ, Deesen KC. Transformation of oral lichen planus to squamous cell carcinoma: a literature review and report of case. *J Am Dent Assoc*. 1982; 105: 55–60. PMID:6955364
 6. Krasowska D, Kozłowicz K, Kowal M, Kurylcio A, Budzynska-Włodarczyk J, Polkowski W, Chodorowska G. Twice malignant transformation of hypertrophic lichen planus. *Ann Agric Environ Med*. 2012; 19(4): 787-789.
 7. Prabhavathy D, Rathnavelu P, Sundaram M. Hypertrophic Lichen Planus with Malignant Transformation. *Indian J Dermatol Venereol Leprol*. 1994; 60: 236-237.
 8. Balachandran C, Ramnarayan K. Squamous cell carcinoma on preexisting plaque of lichen simplex chronicus. *Indian J Dermatol Venereol Leprol*. 1994; 60: 219-220.
 9. Mobine N, Toussaint S, Kamino H. Noninfectious erythematous, papular and squamous diseases. In: Elder D, Elenitas R, Johnson BL Jr, Murphy GF (Eds): *Lever's Histopathology of the Skin* 194-199. Lippincott Williams and Wilkins, Philadelphia, USA 2005.
 10. Bandyopadhyay D, Panda S. Basal cell carcinoma occurring in a lesion of lichen planus: Coincidence or causation? *Indian J Dermatol Venereol Leprol*. 2008; 74: 662-664
 11. Gawkrödger DJ, Stephenson TJ, Thomas SE. Squamous cell carcinoma complicating lichen planus: a clinicopathological study of three cases. *Dermatology* 1994; 188: 36–39. PMID:8305755
 12. Bonnekoh B, Kuhun A. Squamous epithelial cancer in lichen ruber hypertrophicus. A case report with a

- review of the literature. *Z Hautkr* 1986; 61: 394–402. PMID:3705663
13. Wang YN, Chen HC, Wang B, Fang H. Oral and esophageal lichen planus following radiotherapy of nasopharyngeal carcinoma. *Acta DermVenereol.* 2011; 91: 94-95.
14. Leal-Khoury S, Hruza GJ. Squamous cell carcinoma developing within lichen planus of the penis. Treatment with Mohs micrographic surgery. *J DermatolSurgOncol.* 1994; 20: 272–276. PMID:8163749
15. Yesudian P, Rao R. Malignant transformation of hypertrophic lichen planus. *Int J Dermatol.* 1985; 24: 177–178.
16. Franck JM, Young AW. Squamous cell carcinoma in situ arising within lichen planus of the vulva. *Dermatol Surg.* 1995; 21: 890– 894. PMID:7551747
17. Castano E, Lopez-Rios F, Alvarez-Fernandez JG, Rodriguez-Peralto J L, Iglesias L. Verrucous carcinoma in association with hypertrophic lichen planus. *ClinExpDermatol.* 1997; 22: 23-25. PMID:9330048.