

Ellis – Van Crevald syndrome- A Rare Case

Tejas Mukund Kulkarni¹, Rajendra S. Birangane², Sanjiv Onkar³, Abhay Kulkarni⁴, Kamal Yadav⁵, Swati Reddy⁶

ABSTRACT

Ellis van crevald syndrome or chondroectodermal dysplasia is known to be a rare genetic disorder first described by Richard W.B Ellis & Simon Van crevald in 1940. This syndrome comprises tetrad of chondrodysplasia, bilateral postaxial polydactyly of the hands, ectodermal dysplasia & congenital heart defects. The orofacial manifestation includes dental malformations, hypodontia, multiple gingivolabial musculofibrous frenulae, notching of the lower alveolar process, fusion of the upper lip gingival mucosal margin. This paper includes a case report of a young female patient having similar characteristic features and orofacial manifestations suggestive of this syndrome and its management.

Key words: Bilateral polydactaly, Chondrodysplasia, Ellis Van Crevald syndrome (EVC), Orofacial manifestations

^{1,5} Senior Resident, ² Associate Professor and H.O.D, ³ Reader, ⁴ Senior lecturer, Dept of Oral medicine and Radiology, PDU Dental College, Solapur, India

⁶ Senior Resident, Dept of Prosthodontics, PDU Dental College, Solapur. India

Corresponding author mail: dr.tejas84@gmail.com

Conflict of interest: None

INTRODUCTION

Ellis and van crevald in 1940 defined a syndrome that comprises of certain type of chondrodysplasia, bilateral postaxial polydactaly of the hands, tiny and dysplastic units and few cases with congenital heart defects. They coined the term chondroectodermal dysplasia, now it is known as Ellis van crevald syndrome.^{1,2} It is rare autosomal recessive congenital

disorder having incidence of approximately 1 in every 60,000 live births and has equal sex predilection.³ Polydactaly is a stable finding which is often bilateral, postaxial and noted on the ulnar side. Polydactaly of feet can be found only in 10% of the cases. There is wide space frequently present between hallux and other toes.⁴ Patient shows short extremities. Acromelic and mesomelic

shortness of limbs often seen which is commonly found on the distal aspect. Patient is incapable of making a tight fist frequently. Shortness of lower legs is observed which becomes more apparent as the growth advances.⁵ Almost all patients shows dystrophic fingernails that are thin, hypoplastic and spoon shaped.⁶ Genu valgum can be seen as a result of abnormal proximal tibial epiphysis.⁷

In 50-60% cases congenital cardiac manifestations can be seen.⁸ Middle portion of upper lip is fused with gingival margin obliterating maxillary labial vestibule with numerous accessory frenulae adhering the lip to gingival margin.⁹⁻¹³ There can be dental transposition, abnormally shaped teeth, enamel hypoplasia, hypodontia and malocclusion. There may be exfoliation of teeth soon after erupting.¹⁴⁻¹⁸ This article describes a case of young female patient of EVC syndrome with similar clinical manifestations.

CASE PRESENTATION

A 31 year old female reported with chief complaint of missing upper and lower front teeth since birth. She was

unmarried and teacher by profession. Strikingly this was her first dental visit and she was concern about her missing teeth after such long edentulous time span. History revealed patient's parents had consanguineous marriage. She was the child of normally developed parents and their other siblings. Pregnancy and birth were without any adverse incident. Parents gave her history of fusion of middle portion of upper lip with anterior maxillary gingival margin noted soon after birth and was operated.

Systemic examination was non-contributory and showed no cardiac defects after examination by the physician. The patient's stature was short having short hands and feets (Figure 1). Face was symmetric and esthetic. Hairs and skin were normal. Hypoplasia of middle portion of upper lip was noted (Figure 2).



Figure 1: Patients stature showing short hands and feet's

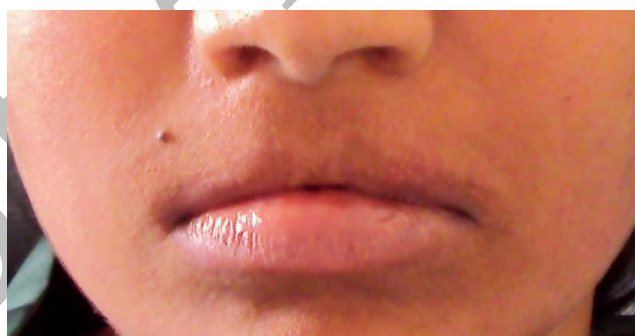


Figure 2: Hypoplastic middle portion of upper lip

Patient showed typical bilateral postaxial hexadactyly of hands and Nails of the hands and feet were thin and dystrophic (Figure 3). Intraoral examination revealed missing upper and lower central and lateral incisors (Figure 4).

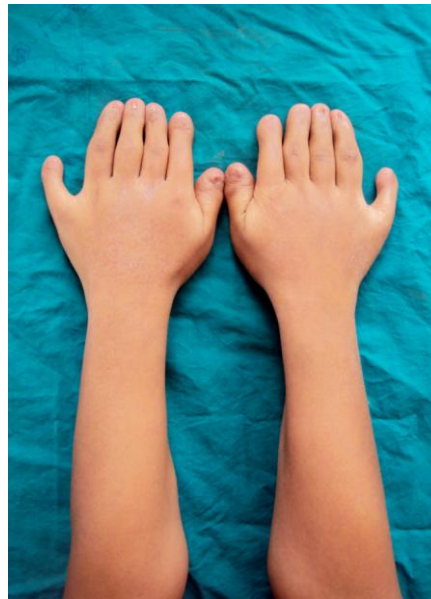


Figure 3: Bilateral postaxial Hexadactyly of hands and thin dystrophic nails

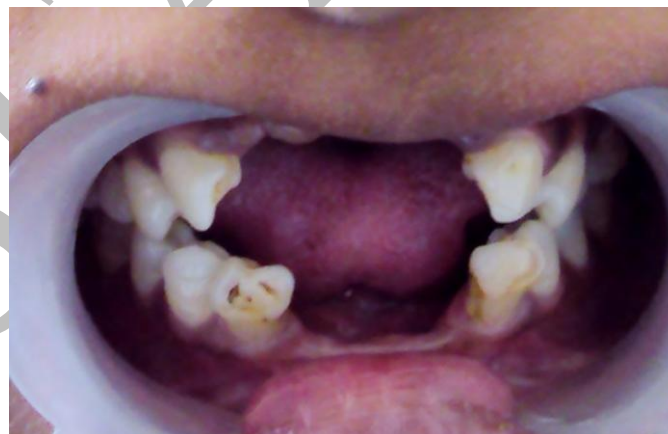

Figure 4: Congenitally missing upper and lower central and lateral incisors

Lower canines were mimicking that of a premolar. Maxillary alveolar ridge showed slight serrations and accessory frenulae (Figure 5).

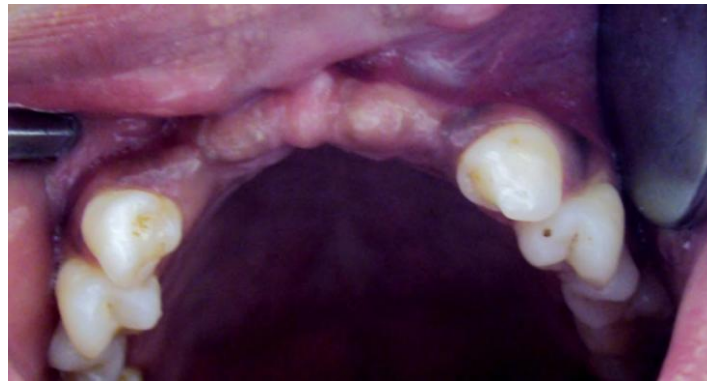

Figure 5: Maxillary alveolar ridge showing serrations or notching and accessory Frenulae

INVESTIGATION

Radiographic examination showed missing upper and lower incisors with no impacted or supernumerary tooth (Figure 6).

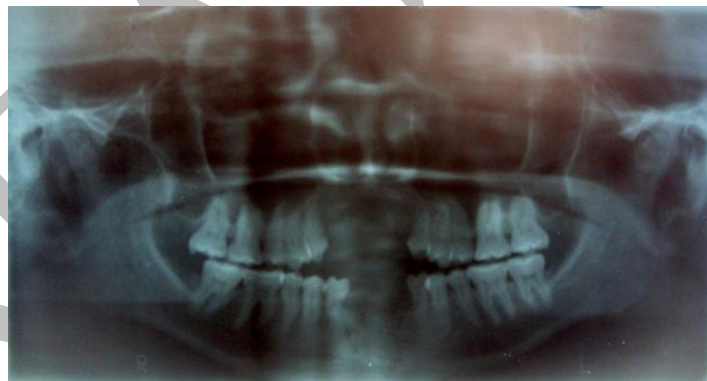


Figure 6: Panoramic radiograph showing missing incisors. No supernumerary or impacted teeth can be seen

DIFFERENTIAL DIAGNOSIS

Differential diagnosis with other syndromes including short stature, polydactaly and Orofacial abnormilities (I and II orofaciodigital syndrome) (gorlin and pindberg, 1964) and asphyxiating thoracic dystrophy (Brueton and Dillon, 1990) can be made.

TREATMENT

Patient underwent thorough oral prophylaxis, intentional root canal treatment of upper and lower right and left canines followed by fixed partial denture of anterior gingival ceramic (Figure 7,8).

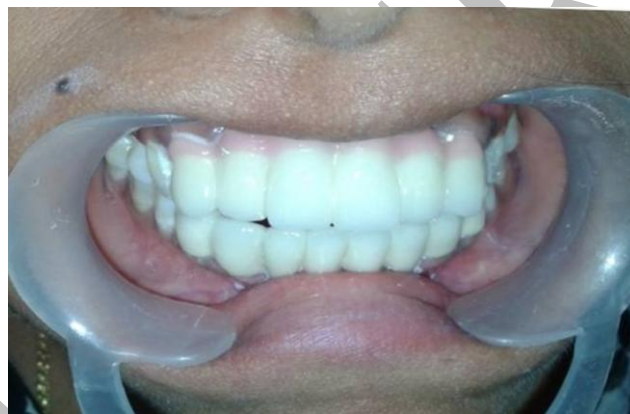

Figure 7: Fixed partial prosthesis of gingival ceramic given to the patient



Figure 8: Post-treatment photograph of the patient

DISCUSSION

Ellis Van Crevald syndrome also called as chondroectodermal dysplasia or mesoectodermal dysplasia is an autosomal recessive disease. It is caused by mutations of the EVC I AND EVC II genes. This syndrome is linked with parental consanguinity in about 30% cases.⁶ EVC is characterized by short limbs, postaxial polydactaly, genu valga, short upper lip, multiple frenulae, fusion of upper portion of middle lip, hypoplasia of anterior maxilla, dysplastic teeth and nails and congenital heart defects in 60% individuals.^{1,16,19} Multiple small alveolar notches or clefts also can be seen on crest of thin alveolar ridge.^{6,16} In patients with EVC erupted teeth tends to be small with an accentuated cusp height and resembles bicuspid sometimes.²⁰

All the reported features were present in the present case except congenital cardiac manifestations. About 100 cases have been reported between the first full description of the syndrome in 1940 by R. Ellis and S. Van crevald in 1968.¹ After that approximately 50 other cases reported in the literature.¹⁶ EVC

syndrome requires multidisciplinary approach for the treatment.²¹

Cardiologist plays important role in managing congenital cardiac problems in neonates. Orthodontist, oral surgeon and prosthodontist has key role in managing craniofacial abnormality in patients affected by this syndrome. Our patient being unmarried female and teacher by profession, esthetic treatment was the major concern. She undergone thorough oral prophylaxis, intentional root canal treatment of the upper and lower canines followed by fixed gingival ceramic prosthesis considering skeletal brittleness and bone resorption associated by the prosthodontic team.

CONCLUSION

Patients with complaints of congenitally missing teeth should be carefully observed for other ectodermal features. In a patient suspecting EVC syndrome, detail history of parents including consanguineous marriage and history of any labio-gingival fusion abnormality at the time of child's birth will be helpful in diagnosis. Management of this syndrome requires multidisciplinary approach including

expert opinion of cardiologists, oral physician, endodontists, prosthodontist etc.

REFERENCES

1. Ellis RW, Van crevald S. A syndrome characterized by ectodermal dysplasia and congenital morbus. *Arch Dis childhood.* 1940;15:65.
2. Tongsong T, Chanprapaph P. Prenatal sonographic diagnosis of Ellis-Van crevald syndrome. *J clin ultrasound* 2000; 38-41.
3. Dhandabani Jayraj, Thangaduraj Maheswaran. Ellis Van crevald. *J pharm bioallied sci.* 2012 August; 153-156.
4. Al-khainaizan S, Al-sanna N, Teebi AS. What syndrome is this? Chondroectodermal dysplasia- The Ellis Van crevald syndrome. *Pediatr Dermatol* 2001; 18: 68-70.
5. Ellis RW, Andrew JD. Chondroectodermal dysplasia. *J Bone joint surg* 1962; 44; 626-36.
6. Gorlin RJ, Cohen MMJ, Hennekam RCM : Syndromes of the head and neck, *Oxford University Press* 2001, New York, 201-204.
7. K. Kurian: Chondroectodermal dysplasia. *Indian Journal Of Dental Research* 2007; 18; 31-34.
8. Atasu M, Biren S. Ellis Van Crevald syndrome: Dental, clinical, genetic and dermatoglyphic findings of a case. *J clin Pediatr Dent* 2006; 24; 141-5.
9. Biggerstaff RH, Mazahari M. Oral manifestation of Ellis Van Crevald syndrome. *J AM Dent Assoc* 1968; 77: 1090-5.
10. Douglas WF, Schoholtz GJ, Geppart LJ. Chondroectodermal dysplasia (Ellis Van Crevald syndrome): Report of two cases in a subship and Review of literature. *Am J Dis Child* 1959; 97; 473-8.
11. Filly RA, Golbus MS, Carey JC, Hall JG. Short limbed dwarfism; ultrasonographic diagnosis by menstruation of fetal femoral length. *Radiology* 1981; 138; 653-6.
12. Prabhu SR, Daftavy DK, Dholkia HM. Chondroectodermal dysplasia (Ellis Van Crevald Syndrome): Report of two cases. *J Oral Surg* 1978; 36; 631-7.

13. Hunter ML, Roberts GJ. Oral and dental anomalies in Ellis Van Creveld Syndrome. Report of a case: *Int J Pediatr Dent* 1998; 8; 153-7.
14. Arya L, Mendiratta V, Sharma RC, Solanki R.S. Ellis Van Creveld syndrome. Report of two cases. *Pediatr Dermatol* 2001; 18; 485-9.
15. Thompson SW, Ruiz Perel UL, Blair HJ, Barton S, Novarro V, Robson JL, et al. Sequencing EVC1 and EVC2 identifies mutations in 2/3 of EVC patients. *Hum Genet* 2007; 120; 663-70.
16. Baujat G, Le Merrer M. Ellis Van Creveld. *Orphanet J Rare Dis.* 2007;2:27.
17. Winter GB, Geddes M. Oral manifestations of Ellis Van Creveld syndrome. Report of a case. *Br Dent J.* 1967,122: 103-7.
18. Ghosh S, Setty S, Sivakumar A, Pai KM. Report of a new syndrome focus on differential diagnosis and review of Ellis Van Creveld syndrome. Curry-Hall, Acrofacial dysostosis and orofacial digital syndrome. *Oral surg Oral med Oral pathol Oral radiol. Endod.* 2007;103;670-6
19. Margarita Varela and Carmen Ramos. *European Journal of Orthodontics* 1996;18; 313-318.
20. Naser A Aminabadi, Akram Ebrahimi and Sina G. Oskoui. Ellis Van Creveld syndrome- A case report. *J of Oral science*; 2010; vol 52; No 2; 333-336.
21. Lynch G, Perry LW, Takakvwa T. Scott LP: Congenital heart diseases and chondroectodermal dysplasia. *Am j Dis child* 1968; 115: 80-87.