

## **Salivary Choristoma in the Floor of Mouth: A Rare Case Report**

Dr. Shivesh kumar<sup>1</sup>, Dr. Abhinav Srivastava<sup>2</sup>, Dr. Chander Mohan<sup>3</sup>

### **ABSTRACT**

Salivary choristoma is a tumor like growth of otherwise normal salivary gland found in an abnormal location. It develops from groups of primordial cells located at a site remote from the original tissue. This case report describes a patient presented with swelling in the floor of mouth and occasional watery discharge from the swelling. Histopathological Examination showed the presence of salivary gland lobules suggesting it to be salivary choristoma. This rare case emphasizes upon considering this rare entity in the differential diagnosis of swelling in the oral cavity and oropharynx.

**Key words:** Excision, Floor of mouth, Histopathological Examination, Salivary Choristoma

<sup>1</sup> PG resident (First year), <sup>2</sup> Assistant Professor, <sup>3</sup> Professor and Head

Department of ENT, Rohilkhand Medical College and Hospital, Bareilly, Uttar Pradesh, India

**Corresponding author mail:** drabhinav.srivastava@yahoo.co.in

Conflict of interest: None

### **INTRODUCTION**

Choristoma or heterotopic tissue is histologically proliferation of normal tissue not normally found in the anatomic site of proliferation. They are uncommonly found in the head and neck region, and rarely occur in intraoral tissues. Choristomas in the oral cavity can consist of several different types of tissues such as bone cartilage, gastric mucosa, glial tissue, and tumor-like masses of sebaceous glands. Amongst those frequently observed choristomas of the oral cavity are those that consist of bone. Osseous choristomas are

frequently more observed among oral choristomas<sup>1</sup>. Monserrat(1913), was the first to report an osseous lesion in the tongue and he labeled it as 'lingual choristoma', the term that normally describes neoplastic pathology<sup>2</sup>. Clinically they present as soft tissue masses in the oral cavity with foreign body sensation.

A rare case of Salivary choristoma in the floor of mouth is presented emphasizing that some of the normal things can occur at another normal anatomical place where they are not at all expected to occur, and must be considered in differential diagnosis.

**CASE REPORT**

A 40 years old female came to ENT OPD complaints of swelling and foreign body sensation in mouth with occasional watering from the swelling since last 3 – 4 years. There was no history of sudden increase in size of the swelling nor any history of associated pain and bleeding from the

swelling. Clinical Examination revealed a firm swelling in the floor of the oral cavity on left side of frenulum, it was not tender and did not bleed on touch. It was not palpable bidigitally. No swelling was present along sub-mandibular duct (Figure 1).

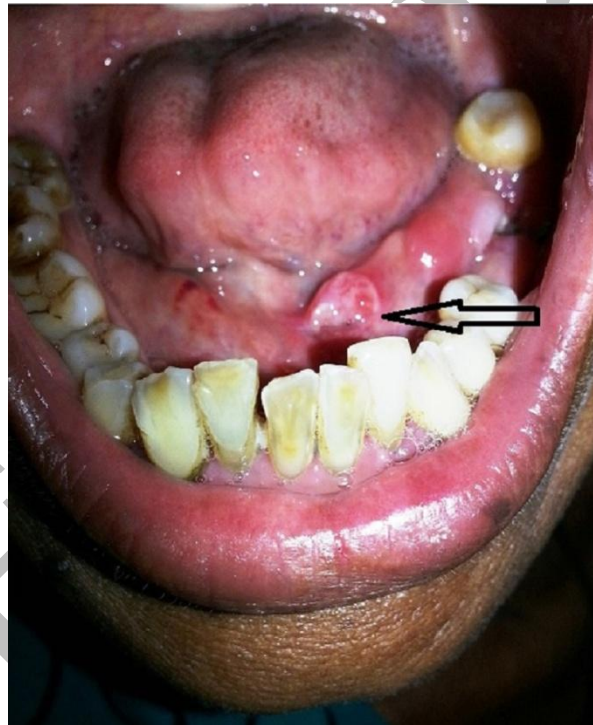


Figure 1: Picture shown choristoma (Arrow)

The excision of the swelling was planned and the tissue of size 0.5 cm x 0.75 cm was excised completely having no visible connection with major or minor salivary

gland. Excised tissue was sending for histopathological examination. Patient did not complaint of recurrence during last six months of our follow-up.

Histopathological examination of the lesion showed numerous salivary gland lobules composed of normal-appearing serous acini and ducts suggesting major

salivary gland tissue. This finding was in favor of choristoma in the oral cavity (Figure 2).

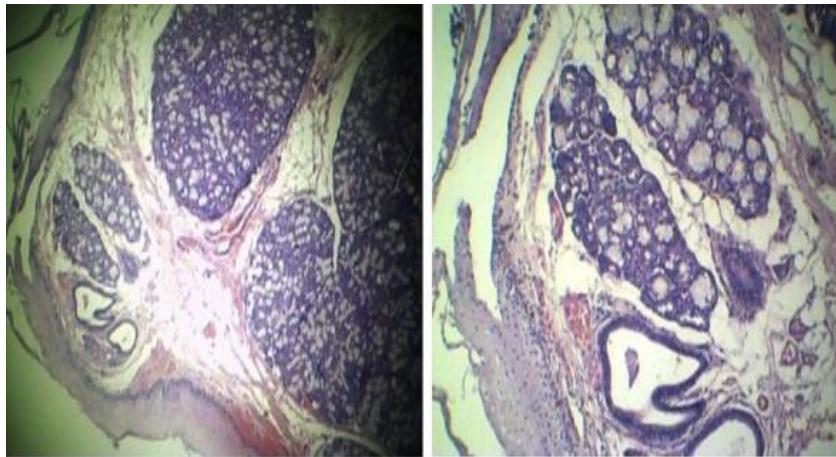


Figure 2: Microscopic picture showing normal serous acini of major salivary gland (low and high Power).

### **DISCUSSION**

Osseous and cartilaginous lesions of the intraoral soft tissues are uncommon. Kroll and co-workers reported 24 cases of intraoral soft tissue osseous lesions. They favoured the term, choristoma, for these lesions, since they represented tumor like growths of histologically normal tissue in an abnormal location<sup>1</sup>. According to some investigators, choristoma refers to a tumor like growth that has developed from groups of primordial cells located at a site remote from the original tissue or organ<sup>2</sup>.

The age range for reported cases of intraoral choristomas is between 8 and 73 years; however, the majority have been diagnosed in women between the age of 20 and 40 years. Most intraoral choristomas develop in the area of the foramen caecum, anterior and ventrolateral surface of tongue, buccal mucosa and lingual alveolus of mandible<sup>3</sup>. In the oral cavity, it can consist of several different types of tissues such as bone, cartilage, gastric mucosa, glial tissue, and tumor-like masses of sebaceous glands.

It is rare to find salivary tissue in a rare location of floor of mouth, as bone being the

most common tissue being present mostly around foramen caecum<sup>3,4</sup>.

Since the intraoral choristoma is rare, most such lesions are misdiagnosed as other soft tissue tumors. As per the location of the lesion, the differential diagnosis for intraoral choristoma varies. The most common clinical differential diagnosis for this swelling is calculus along sub-mandibular duct, ranula, malignancy of floor of mouth.

Oral choristoma can be classified according to types of tissues they constitute<sup>5</sup>:

Salivary Gland choristoma: 1. Central  
2. Gingival

Both have ectopic salivary gland tissue appearing as a raised tumor like mass; must not have any connection with normal minor or major salivary glands.

Cartilagenous choristoma: composed of mature hyaline cartilage in fibrous tissue that resembles perichondrium; usually multilobulated; chondrocytes vary from small to large, but lack atypia.

Osseous choristoma: composed of dense mature bone; osteocytes are compact and unremarkable; no prominent osteoblastic rimming; occasionally bone and cartilage are present in same lesion.

Lingual thyroid choristoma

Lingual sebaceous choristoma

Glial choristoma

Gastric choristoma

Gastric / respiratory mucosal choristoma: a) solid and b) cystic

Though various possible mechanisms for the development of salivary choristoma have been proposed but the exact pathogenesis of this rare entity is yet to be finalized. It is possible in our case that minor salivary gland tissue of floor of mouth and elements of Sub-mandibular gland may have been mechanically displaced during prenatal development and subsequently, develop as swelling in the floor of mouth.

### **CONCLUSION**

It should be emphasized that, though salivary choristoma is a rare condition but one should be aware of such a rare entity as salivary heterotopias or salivary choristoma in the oral cavity, and this must be considered in the differential diagnosis. However, tumorigenic potential of salivary gland choristoma is yet to be proved as none has been reported till date.

**REFERENCES**

1. Krolls SO, Jacoway JR, Alexander WN. Osseous choristomas(Osteomas) of intraoral soft tissues. Oral Surg Oral Med Oral Pathol. 1971;32:588-95.
2. Chou LS, Hansen LS, Daniels TE. Choristoma of the oral cavity: A review. Oral Surg Oral Med Oral Pathol. 1991;72:584-93.
3. Tohill MJ, Green JG, Cohen DM. Intraoral osseous and cartilaginous choristomas: Report of three cases and review of the literature. Oral Surg Oral Med Oral Pathol. 1987;63:506-10.
4. Shimono M, Tsuji T, Iguchi Y, Yamamura T, Ogasawara M, Honda T, et al. Lingual osseous choristoma. Report of 2 cases. Int J Oral Surg. 1984;13:355-9.
5. Ranmeet Batra. The Pathogenesis of oral choristoma. J Oral Maxillofac Surg 2012;24:110.