

## **Paranasal sinus involvement in Tracheobronchopathia Osteoplastica: A rare Association**

Dr. Venkatesha Belur Keshavamurthy<sup>1</sup>, Dr. Munish Kambakatti Shekarappa<sup>2</sup>, Dr. Shivakumar Andanur Mahalingappa<sup>3</sup>, Dr. Kishan Ashok Bhagwat<sup>4</sup>, Dr. Jeyashanth Riju<sup>5</sup>, Dr. Anil Kumar G.<sup>6</sup>

### **ABSTRACT**

Tracheobronchopathia osteochondroplastica (TO) is a rare and benign disorder characterized by cartilaginous and /or osseous submucosal deposits projecting into the laryngotracheobronchial lumen. The disorder is usually asymptomatic and most of the cases have been diagnosed incidentally as a surprise during difficult intubation or during bronchoscopy. A case of TO in association with Paranasal sinus involvement being reported for its rarity.

**Keywords:** Tracheobronchopathia Osteoplastica, Paranasal Sinuses, Polyps, Intubation

<sup>1,2,4</sup> Associate professor, <sup>3</sup> Professor and Head of department,

<sup>5</sup> Post graduate, Department of Otorhinolaryngology, SSIMS&RC, Davangere

<sup>6</sup> Specialist in Otorhinolaryngology, ESIC Hospital, Ernakulam

Corresponding author mail: [bk.venkatesha@gmail.com](mailto:bk.venkatesha@gmail.com)

Conflict of interest: None

### **INTRODUCTION**

Tracheobronchopathia Osteochondroplastica is a rare disease encountered as surprise during difficult intubation. Etiopathogenesis of this condition is unclear till date; some insight into the etiology towards klebsiella<sup>1</sup> has been pointed out in the literature. Only few conditions like amyloidosis, atrophic rhinitis has been associated with Trachobronchopathia osteochondroplastica. Here with presenting a Case of Rare association of Paranasal sinus involvement with Tracheoosteopathia chondroplastica .

### **CASE PRESENTATION**

A 23 yr old patient presented to ENT department with history of unilateral nasal obstruction with mucopurulent nasal discharge of 1 yr duration. Unilateral nasal obstruction was partial to begin and progressed to complete nasal obstruction over a period of one year. There was no history of blood stained nasal discharge. No respiratory complaints like difficulty in breathing, cough with or without expectoration were noted. Diagnostic nasal Endoscopy revealed multiple sessile smooth polyps arising from the left middle meatus

with mucoid discharge and crusting. Routine blood parameters were within normal limits. After Radiological investigations of nose and Paranasal sinuses, patient was diagnosed to have suspected fungal rhinosinusitis and was posted to Endoscopic sinus procedure under general anaesthesia. Patient was taken up for surgery under General Anesthesia with Grade I ASA risk. Anaesthetist noted difficulty in passing endotracheal tube beyond subglottic region. Bronchoscopy was performed to visualize the obstruction at subglottic region. A shelf like bone projection from the lateral wall of the bronchus occupying two thirds of the lumen of trachea noted. 3.5 mm ventilating bronchoscope was negotiated into the lumen and multiple fibronodular lesions seen

extending from the subglottic region until carina. Characteristically such lesions were not visualized on the posterior membranous portion of the trachea. Biopsy was taken from two different sites of the tracheal lesion and also from the middle meatus. No respiratory symptoms were present upon enquiring the patient in detail post operatively. X- Ray Chest and CT Thorax were performed post operatively. X ray chest shows irregular tracheal lumen and CT showed multiple submucosal calcium deposition through out the trachea sparing the membranous portion of the tracheal lumen. Histopathology shows non specific chronic inflammatory reactive pattern from both sites.

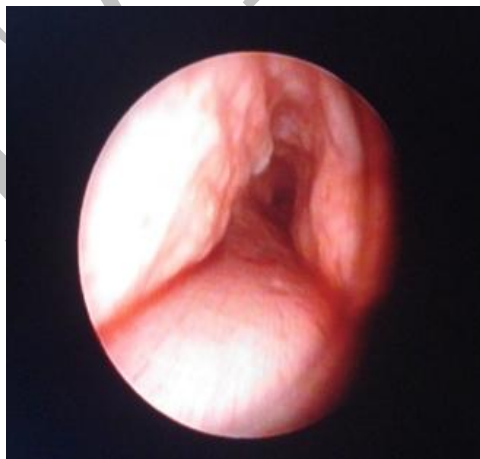

Figure 1: Multiple fibronodular lesions extending throughout tracheal lumen typically sparing the posterior membranous wall

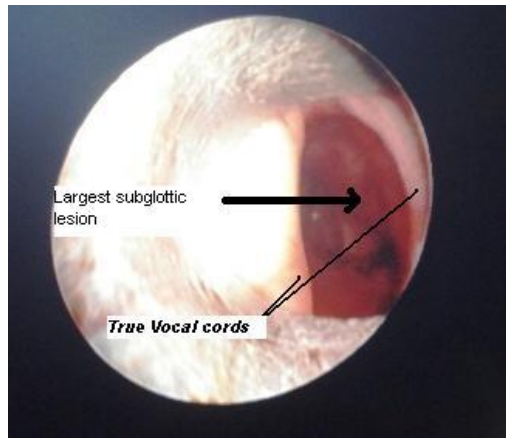


Figure 2: Subglottic shelf like projection in to the tracheal lumen

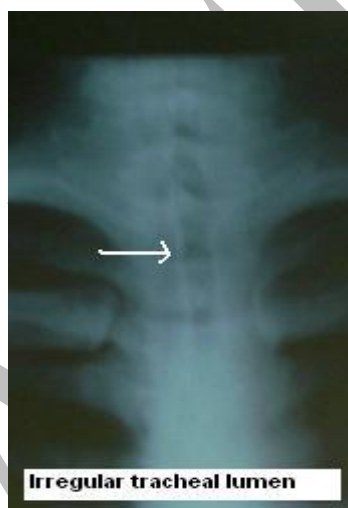


Figure 3: Irregular outline of the tracheal lumen.

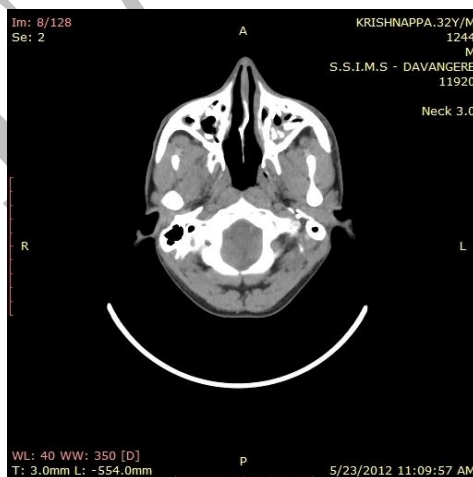

Figure 4 showing the CT Paranasal sinuses

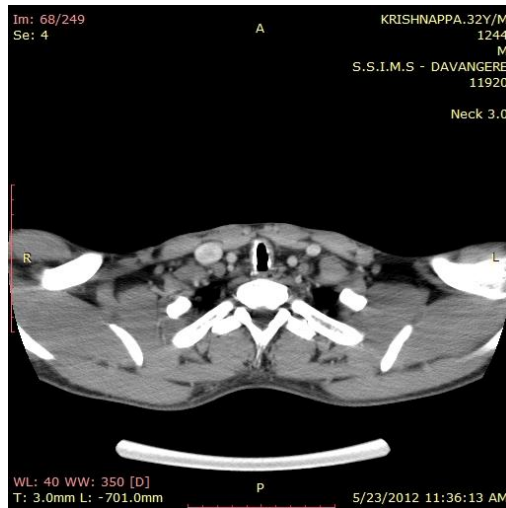

Figure 5

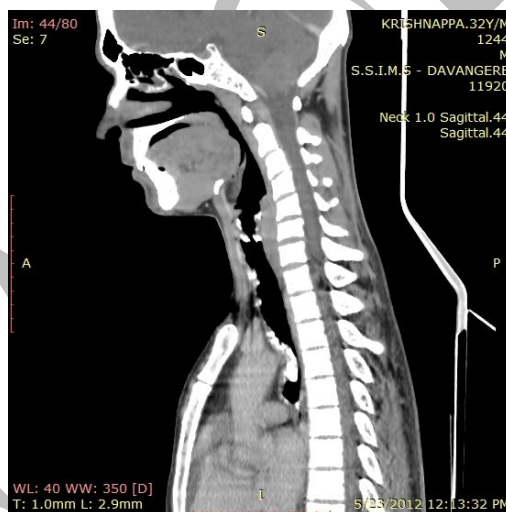


Figure 6

Figure 5 and 6: CT of Thorax axial cuts showing characteristic submucosal depositions of the calcium in the anterior and lateral walls of the trachea sparing the posterior membranous portion.

5b showing saggital section involving the whole length of the trachea.

### **DISCUSSION**

Tracheobronchopathia osteochondroplastica is an idiopathic benign disease of the trachea and major bronchi characterized by multiple submucosal osteocartilaginous nodules. The nodules classically affect the lower two-

thirds of the trachea and proximal portions of the primary bronchi<sup>2</sup>. The nodules may be either focal or diffuse. There is a 3:1 male predilection, and the disease typically manifests in patients in their mid-50s.

The Mechanisms of nodules formation in TO is unknown. Classical theories include ecchondrosis and exostosis arising from the cartilaginous tracheal rings or metaplasia of the submucosal elastic and connective tissue. Despite a compatible distribution of lesions at histology, no objective data support these hypothesis.<sup>3</sup>

The prevalence of tracheobronchopathia osteochondroplastica found during routine bronchoscopy for unrelated complaints ranges from 0.02%<sup>4</sup> to 0.7%<sup>5</sup>. Frequently, however, the diagnosis is made after a difficult intubation or during bronchoscopy. Many experienced bronchoscopists believe the disease occurs more often but is not recognized owing to its indolent course<sup>6</sup>. Most patients are asymptomatic, but presentation may include cough, dyspnea at exertion, recurrent infection, wheezing, and, on occasion, hemoptysis. The latter symptom occurs when opposing nodules rub against each other, causing erosion of the mucosa and subsequent bleeding.

At histopathologic examination, the nodules are submucosal osteocartilaginous growths. The mucosal surface is typically intact, and a connection to the perichondrium of a tracheal ring is frequently seen. In moderate to severe disease, conventional radiography

may reveal tracheal scalloping and nodular irregularity or irregular asymmetric stenosis. Thickened tracheal cartilage with irregular calcification is seen with CT. Multiple nodules, with or without calcification, may project into the airway lumen. The nodules of tracheobronchopathia osteochondroplastica spare the posterior membrane<sup>7,8</sup>

The typical bronchoscopic appearance is of multiple smooth, raised, white, osteocartilaginous nodules, often described as “beaded”. These nodules are typically distributed over the anterolateral walls in association with the cartilaginous rings, sparing the posterior membrane. These lesions are typically hard, and biopsy of them is difficult. The diagnosis is often made from the visual appearance alone. There is currently no specific treatment to remove the abnormal tissue growth or to prevent the development of new nodules. Association of Tracheobroncho osteopathia chondroplastica with klebsiella ozenae is suspected. Most cases of Tracheobronchopathia osteoplastica are asymptomatic and the prognosis is generally good. These association of lung cancer<sup>9</sup>. Amyloidosis,<sup>10</sup> sinobronchial syndrome<sup>11</sup> atrophic rhinitis and as in this case with

Paranasal sinus involvement may be coincidental or may give an insight into the pathology of tracheobronchopathia osteoplastica.

### **CONCLUSION**

Tracheobronchopathia osteoplastica(TO) is a clinically silent disorder and should be suspected in all cases of difficult intubation especially when resistance is felt while introducing endotracheal tube. Granulomatous disorders of nose and paranasal sinuses also needs evaluation of trachea for TO.

### **REFERENCES:**

1. Harma RA, suurkari S. "Trachopathia osteochondroplastica, A clinical study of thirty cases". *Acta Otolaryngol* 1977;84: 118-23
2. Braman SS, Grillo HC, Mark EJ. "A 44-year-old man with tracheal narrowing and respiratory stridor.Massachusetts General Hospital Case Records" case 32-1999. *N Engl J Med* 1999; 341:1292–1299
3. Romain Lazor, Jean Francois Cordier, "Tracheobronchopathiaosteochondroplastic" , *Orphanet*. June 2002, update: june 2004.
4. Van Nierop MAMF, Wagenaar SS, van den BoschJMM, Westermann CJ. "Tracheobronchopathiaosteochondroplastica : report of four cases". *Eur J Respir Dis* 1983; 64:129–133.
5. Primer G. "Tracheopathia osteochondroplastica".*Prax Pneumol* 1979; 33:1060–1063.
6. Prince J S. et al. "Nonneoplastic Lesions of the Tracheobronchial Wall: Radiologic Findings with Bronchoscopic Correlation" *RadioGraphics* 2002; 22:S215–S230
7. Kwong JS, Mueller NL, Miller RR. "Diseases ofthe trachea and main-stem bronchi: correlation of CT with pathologic findings". *RadioGraphics* 1992; 12:645–657, 2.
8. Marchiori E. et al, "Diffuse abnormalities of the trachea: computed tomography findings" *Jornal Brasileiro de Pneumologia J. bras. pneumol. vol.34 no.1 São Paulo Jan. 2008*
9. Barthwal M.S., Chatterji R.S. and Mehta A "Tracheobronchopathiaosteochondroplastica", *Indian J Chest Dis Allied Sci* 2004; 46 : 43-46
10. Klrba G , et al. "Unusual Combination ofTracheobronchopathiaOsteochondroplastica and AA Amyloidosis", *Yonsei Med J* 50(5): 721-724, 2009
11. Oka H et al. "Tracheobronchopathia osteochondroplastica associated with sinobronchial syndrome", *Intern Med.* 2009;48(7):579-80.