

Carotico clinoid foramen and interclinoid bars - A case report

Usha Kothandaraman¹, S.Lokanadham²

ABSTRACT

We have observed one skull with bilateral carotico clinoid foramen and interclinoid bars formed by fusion of carotico clinoid ligaments between the anterior, middle and posterior clinoid processes. The incidence of the complete type of bilateral carotico clinoid foramen in our study was 1 out of 20 human dry skulls (5%). The bilateral formation of interclinoid bars and carotico-clinoid foramen have high significance due to their rare occurrence. Carotico clinoid foramen may cause changes in the internal carotid artery in clinoid segment which may cause compression of cavernous sinus due to its medial position. Our study provides a guide to neurosurgeons in surgical approaches to prevent fatal complications while performing regional surgeries.

Key words: clinoid process, carotico clinoid foramen, interclinoid bars,

¹Professor and Head, ²Faculty

Department of Anatomy, ESIC Medical College & PGIMSR, Chennai, Tamilnadu - 600078.

Corresponding author mail: loka.anatomy@yahoo.com

Conflict of interest: NIL

INTRODUCTION

Osseous bridge between the tip of the middle and anterior clinoid processes forms Carotico-Clinoid Foramen. Anterior Clinoid Process formed from the medial end of the lesser wing of sphenoid bone which provides attachment to the free margin of the tentorium cerebelli and is grooved medially by the internal carotid artery [1]. Carotico-Clinoid Ligament connects the anterior clinoid process and middle clinoid process, which is

sometimes ossified. Ossification of carotico-clinoid ligament or of a dural fold extending between the anterior clinoid process and middle clinoid process may result in the formation of the Carotico-Clinoid Foramen [2]. The ossified carotico-clinoid ligament may have compressive effects on the internal carotid artery. The fibrous ossification of ligaments is considered a normal physiological process that occurs with aging; however this process is an

exception when one considers the formation of the carotico-clinoid foramen [1,3]. Our study gives basic knowledge to surgeons about the interclinoid bars and carotico-clinoid foramen formation.

CASE REPORT

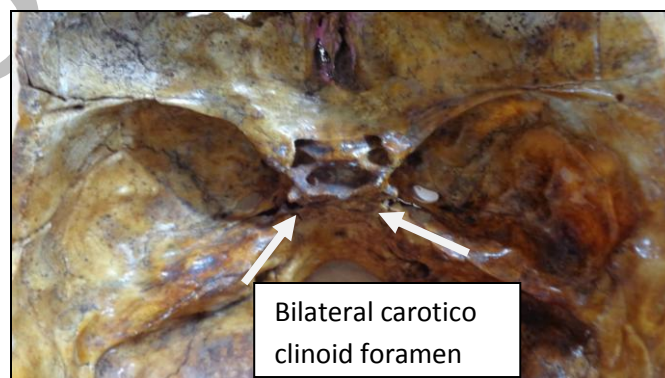
We have observed fusion of clinoid processes forming the inter-condylar bars and carotico-clinoid foramen in one skull out of 20 dry human skulls (5%) utilized from the Department of anatomy, ESIC Medical College, Chennai. In the present study, carotico-clinoid foramen was observed bilaterally in middle cranial fossa. Carotico-clinoid foramen formed by the fusion of anterior and middle clinoid processes located posterior to the optic canal, anterior to the pituitary fossa and lies lateral to the tuberculum of sella turcica. We keenly noted the inter-condylar bars bilaterally connecting the anterior, middle and posterior clinoid

processes. Complete ossification of the fibrous ligament between anterior, middle and posterior clinoid processes was observed.

DISCUSSION

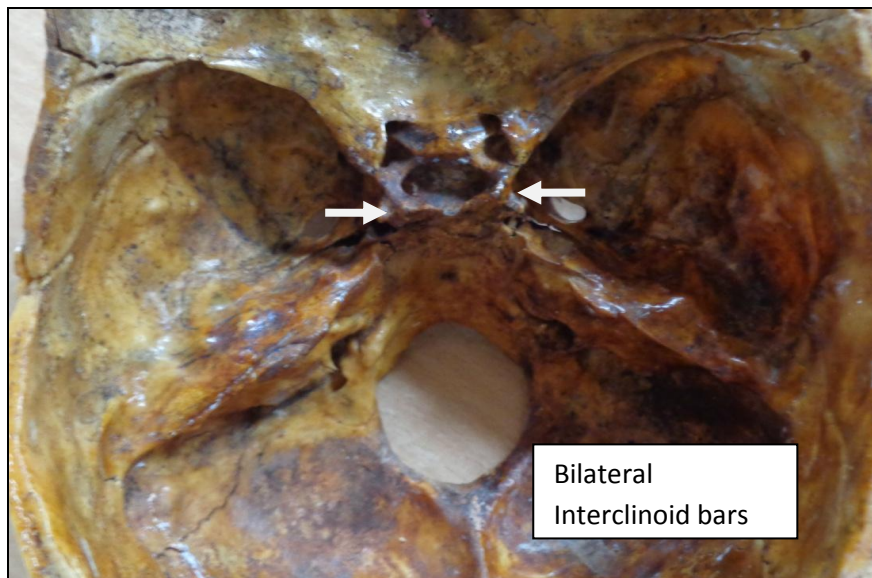
The carotico-clinoid foramen is the result of ossification either of the fibrous carotico-clinoid ligament or of a dural fold extending between the anterior and the middle clinoid processes of the sphenoid bone. When there is no ossification of the fibrous ligament, only a space between the anterior and middle clinoid processes is observed which is known as clinoid space [4]. The presence of the carotico-clinoid foramen causes morphological changes in the internal carotid artery in almost all cases [5]. In the present study we have observed presence of carotico clinoid foramen bilaterally along with interclinoid bars in dry human skull (Figure-1).

Figure -1: Presence of bilateral carotico clinoid foramen (CCF) pointing with arrows



The fusion of interclinoid bars and the foramen and completely ossified. Due to the ossified interclinoid bars between the clinoid processes there was deeper hypophyseal fossa in the tuberculum sella (Figure-2).

Figure-2: Completely ossified interclinoid bars and the carotico clinoid foramen



Freire et.al studied 80 dry human skulls and found 2.5% of the skulls with bilateral foramen [6]. Lee H. Y's study in 73 dried Korean skulls, complete carotico clinoid foramen was observed in 4.1% and an incomplete type was observed in 11.6%[7].The incidence of complete type of carotico-clinoid foramen in our study is 5%; which is in agreement with previous literatures and also having high significance due to bilateral formation[7,8]. Carotico clinoid foramen may cause compression and narrowing of the internal carotid artery, located medially to the anterior clinoid process[9].Due to the presence of carotico-clinoid foramen

there is a high possibility of induced headache caused by compression of the internal carotid artery[3,10].

CONCLUSION

Carotico-clinoid foramen may cause changes in the internal carotid artery which may cause compression of cavernous sinus due to its medial position [11]. Our study provides a guide to neurosurgeons in surgical approaches to prevent fatal complications while performing regional surgeries.

Acknowledgement

Authors acknowledge the great help received from **Krupakaran** during this work. The authors are also grateful to

authors, editors and publishers of all those articles, journals and books from where the literature for this article has been reviewed and discussed.

REFERENCES

1. Williams PL, Warwick R, Dyson M, Bannister L. Gray's Anatomy. 37th Ed., Edinburgh, Churchill Livingstone. 1989; 373–377.
2. Dr. S.D. Desai, Dr. Sunkeswari Sreepadma. Study of carotico-clinoid foramen in dry human skulls of North Interior Karnataka. NJBMS Oct-Dec 2010; vol 1:2, 60-4.
3. Ozdogmus O, Saka E, Tulay C, Gurdal E, Uzun I, Cavdar S. The anatomy of the carotico-clinoid foramen and its relation with the internal carotid artery. Surg Radiol Anat 2003; 25(3-4):241-6.
4. Gupta N, Ray B, Ghosh S. A study on anterior clinoid process and optic strut with emphasis on variations of carotico-clinoid foramen. Nepal Med C J. 2005; 7(2):141-4.
5. Das S., Suri R., Kapur V. Ossification of carotico-clinoid ligament and its clinical importance in skull based surgery. Sao Paulo Med. J. Nov 2007; 125(6): 351-3.
6. Freire, A.R., Rossi, A.C., Prado, F.B. Groppo, F.C., Caria, P.H.F. and Botacin, P.R. The carotico-clinoid foramen in the human skull and its clinical correlations. Case Report. IJAV, 2010; 3:149-50.
7. Lee H.Y., Chung I.H., Choi B.Y. Anterior clinoid process and optic strut in Koreans. Yonsei Med J, 1997; 38:151-4.
8. Erturk M., Kayalioglu G., Gousa F. Anatomy of the clinoidal region with special emphasis on the carotico-clinoid foramen and interclinoid osseous bridge in a recent Turkish population. Neuro surg Rev 2004; 27:22-6
9. Inoue T, Rhoton AL Jr, Theele D, Barry ME. Surgical approaches to the cavernous sinus: a microsurgical study. Neurosurgery. 1990; 26: 903–932.
10. Narolewski R. Significance of anatomic variants of bony surroundings of the internal carotid artery and their significance for lateral surgical approaches to the cavernous sinus. Ann Acad Med Stetin. 2003; 49: 205–229. (Polish)
11. Sekhar, L.N. and Akin, O. Anatomical study of the cavernous sinus emphasizing operative approaches and related vascular and neural reconstruction. J. Neuro surg, 1987; 21: 806-16.