

---

## **Dyke-Davidoff-Mason Syndrome: An unusual cause of focal seizure**

Ayush Dubey<sup>1</sup>, Om Prakash Lekhra<sup>2</sup>

### **ABSTRACT**

Dyke-Davidoff-Mason syndrome (DDMS) is characterized by atrophy and cerebral hemisphere, contralateral hemiplegia, focal seizures and mental retardation. The salient radiologic features are cerebral hemiatrophy and calvareal changes. We report a case of uncontrolled right focal seizures and mental retardation in which the cause was found to be DDMS.

**Key words:** Dyke-Davidoff-Mason, Hemiatrophy DDMS, seizure

<sup>1</sup>Senior Resident, <sup>2</sup>Professor

Department of Neurology, Sri Aurobindo Medical College & PG Institute, Indore, INDIA.

Corresponding author mail:olekhra63@gmail.com

Conflict of interest: None

---

### **INTRODUCTION**

Dyke-Davidoff-Mason syndrome (DDMS) refers to atrophy or hypoplasia of any of the cerebral hemispheres (hemiatrophy), which is caused usually due to an insult to the developing brain in fetal or early childhood period. [1] The clinical features are variable and depend on the extent of brain injury present. More commonly they present with recurrent seizures, facial asymmetry, contralateral hemiplegia, mental retardation, learning disabilities and language problems. Sensory loss and psychiatric manifestations like schizophrenia have been reported rarely. [2, 3] The typical radiological features include cerebral hemiatrophy with ipsilateral compensatory hypertrophy of

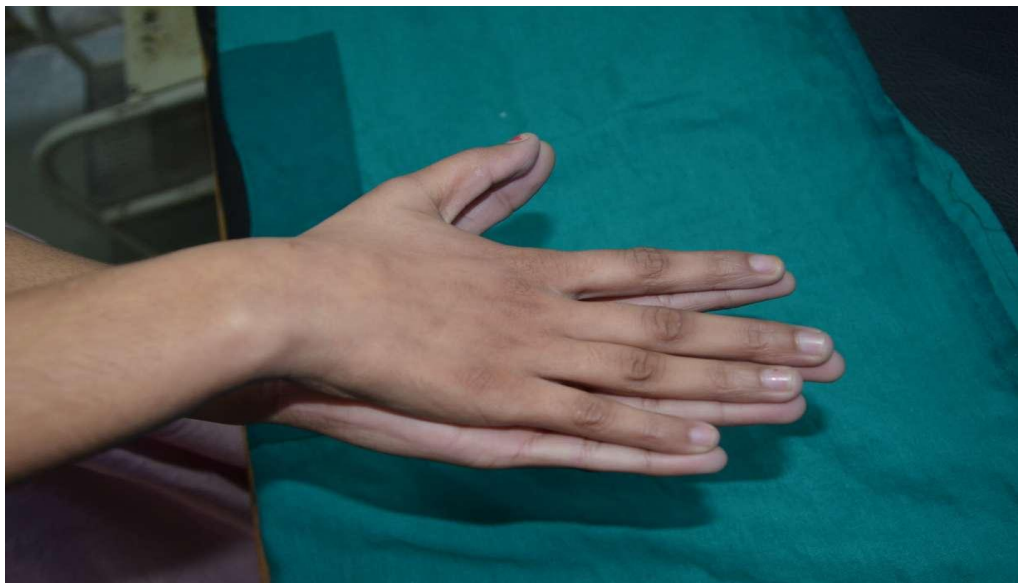the skull and sinuses. This syndrome has been documented mainly in children and adolescents. [4, 5, 6,] .We report a case with typical clinical and imaging features of DDMS.

### **CASE REPORT**

A 15 year old female presented to the outpatient department with seizures since early childhood followed by weakness in the right half of body. She was born through a full term normal vaginal delivery and had normal cry after birth .She remained well for the next 6 months but then developed focal seizures in the right upper limb with secondary generalization. She had 3 similar episodes and was admitted in a hospital for 4 days. Since

then she had weakness in the right upper as well as the lower limbs and faced difficulties in doing her daily activities. She also had delayed milestones during her childhood. On examination she was found to have reduced IQ (57) with mental age of

8 years. Right sided limbs showed significant wasting with grade 4 power. She had an extensor plantar with hemiplegic gait. She also demonstrated limb length discrepancy in right upper and lower limbs (Figure 1).



**Figure 1** Both hands of the patient showing wasting and discrepancy in the size of right hand (upper one )

Her MRI brain revealed cerebral atrophy in the left half of brain with bony changes in the skull in the form of thickening of the skull margins (Figure 2, 3). EEG showed mild asymmetry with diminished voltage

on the left side. On the basis of her clinical presentation and the typical MRI findings, a diagnosis of Dyke Davidoff Mason Syndrome was made.

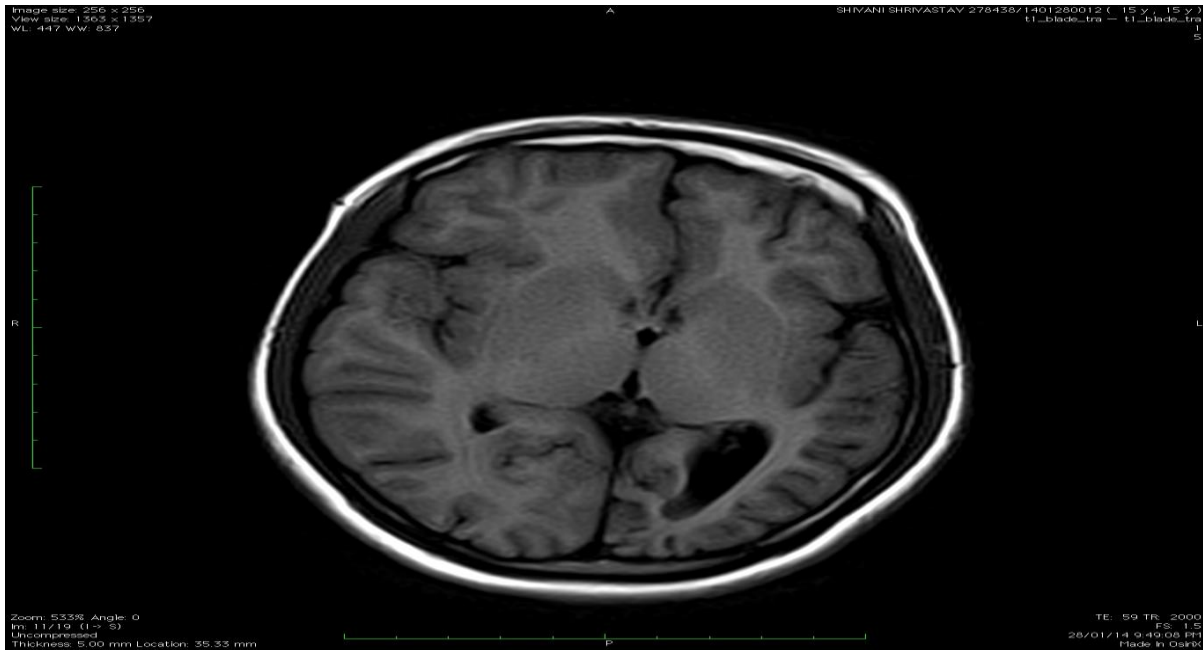


Figure 2 Brain MRI axial T1 image shows atrophy of the entire left hemisphere and calvarial thickening..

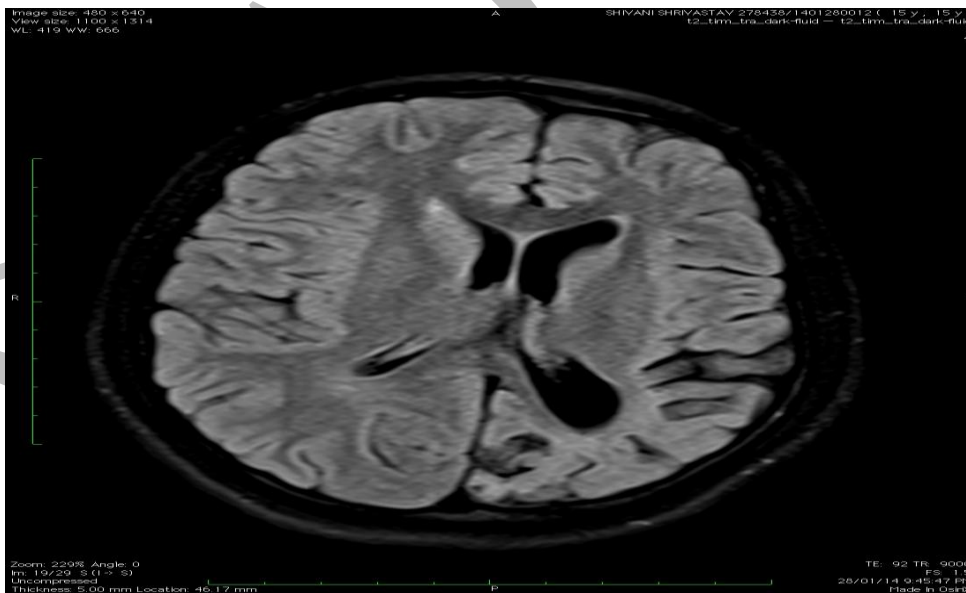


Figure 3 Brain MRI axial FLAIR image show left cerebral atrophy and ipsilateral dilatation of the ventricles

**DISCUSSION**

In 1933, Dyke, Davidoff and Mason firstly described the syndrome in plain radiographic and pneumoencephalographic changes in one series of nine patients.[7] DDMS is characterized by asymmetry of cerebral hemispheric growth with atrophy or hypoplasia of one side, ipsilateral osseous hypertrophy with hyperpneumatization of sinuses mainly frontal and mastoid air cells with contralateral paresis.[8] Other features include enlargement of ipsilateral sulci, dilatation of ipsilateral ventricle and cisternal space, decrease in the size of ipsilateral cranial fossa, and unilateral thickening of the skull. Clinical presentations include variable degree of facial asymmetry, seizures, contralateral hemiparesis, mental retardation, learning disabilities and in few cases impaired speech. Focal seizures are commonly seen and but in some cases secondary generalization may occur. Either sex and hemisphere may be affected, but male sex and left side involvement are more commonly reported. [9]

The human brain reaches half of its adult size during the first year of life and three fourth of the adult size is attained by the end of 3 years. The surface of the

hemisphere remains smooth and uninterrupted until early in the fourth month of gestation. By the end of the eighth month, all the important sulci can be recognized. [10] The developing brain press outward on the bony skull table resulting in gradual increase in head size and shape. When the brain fails to grow properly, the other structures grow inward resulting in increased width of diploic spaces, enlarged sinuses, and elevated orbital roof.[11] These changes can occur only when brain damage is sustained before 3 years of age..[12]

Cerebral hemiatrophy can be of two types, infantile (congenital) and acquired.[13] The infantile variety results from various etiologies such as infections, neonatal or gestational vascular occlusion involving the middle cerebral artery, unilateral cerebral arterial circulation anomalies, and coarctation of the mid-aortic arch.[13,14] The patient becomes symptomatic in the perinatal period or infancy. The main causes of acquired type are trauma, tumor, infection, ischemia, hemorrhage, and prolonged febrile seizure. Age of presentation depends on time of insult and characteristic changes may be seen only in adolescence or adult.

In our case, the findings of left cerebral hemiatrophy with enlarged cortical sulci, microcephaly, calvarial changes, mental retardation and presentation at the age of 15 years reflect an onset of silent vascular brain insult after the completion of sulci formation in perinatal period .A proper history, thorough clinical examination, and radiologic findings provide the correct diagnosis. [15] The condition needs to be differentiated from Sturge Weber syndrome and Rasmussen encephalitis. Rasmussen encephalitis is a chronic progressive immune mediated disorder thought to be secondary to viral infections. It usually presents with intractable focal epilepsy and cognitive defects in children. The imaging features include unilateral hemispheric atrophy without any calvarial changes. [15]

Patients with DDMS usually present with refractory seizures and the treatment should focus on control of the seizures with suitable anticonvulsants. In our case appropriate anticonvulsants were prescribed and the needful rehabilitation was done. Sometimes multiple anticonvulsants are in use. Along with drugs, physiotherapy, occupational therapy, and speech therapy play a significant role in long-term management

of the child. Prognosis is better if the onset of hemiparesis is after 2 years of age and in absence of prolonged or recurrent seizure. [9] Hemispherectomy is the treatment of choice for children with intractable disabling seizures and hemiplegia with a success rate of 85% in selected cases. [7]

As hemispherectomy is not available even in many urban tertiary care centers, it is very important for a neurologist or pediatrician practicing in semi-urban or rural setup to diagnose the condition early by means of suitable imaging and the treatment should focus on optimum control of seizures, revision of drug doses from time to time, and domiciliary physiotherapy.

#### **REFERENCES**

1. Sharma S, Goyal I, Negi A, Sood RG, Jhobta A, Surya M. Dyke-Davidoff-Masson Syndrome. *Ind J Radiol Imag.* 2006;16:165–6.
2. Ono K, Komai K, Ikeda T. Dyke-Davidoff-Masson Syndrome manifested by seizure in late childhood: A case report. *J Clin Neurosci.* 2003;10:367–71. [[PubMed](#)]
3. Amann B, Garcia de la Iglesia C, Mckenna P, Pomarol-Clotel E, Sanchez-Guerra M, Orth M. Treatment- refractory Schizoaffective disorder in a patient with

- Dyke-Davidoff Masson Syndrome. *CNS Spectr.* 2009;14:36–9. [[PubMed](#)]
4. Singh P, Saggar K, Ahluwalia A. Dyke-Davidoff-Masson Syndrome: Classical imaging findings. *J Pediatr Neurosci.* 2010;5:124–5. [[PMC free article](#)] [[PubMed](#)]
5. Shetty DS, Lakhkar BN, John JR. Dyke-Davidoff-Masson Syndrome. *Neurol India.* 2003;51:136. [[PubMed](#)]
6. Narain NP, Kumar R, Narain B. Dyke-Davidoff-Masson Syndrome. *Indian Pediatr.* 2008;45:927–8. [[PubMed](#)]
7. Dyke CG, Davidoff LM, Masson CB. Cerebral hemiatrophy and homolateral hypertrophy of the skull and sinuses. *Surg Gynecol Obstet.* 1933;57:588–600.
8. Pendse NA, Bapna P, Menghani V, Diwan A. Dyke-Davidoff-Masson Syndrome. *Indian JPediatr.* 2004;71:943. [[PubMed](#)]
9. Unal O, Tombul T, Cirak B, Anlar O, Incesu L, Kayan M. Left hemisphere and male sex dominance of cerebral hemiatrophy(DDMS) *Clin Imaging.* 2004;28:163–5. [[PubMed](#)]
10. Graham A, Molnar Z. Development of the Nervous system. In: Standring S, editor. *Gray's Anatomy.* 40th ed. London, Churchill Livingstone: Elsevier; 2008. p. 385.
11. Parker CE, Harris N, Mavalwala J. Dyke-Davidoff-Masson Syndrome: Five case studies and deductions from dermatoglyphics. *Clin Pediatr.* 1972;11:288–92. [[PubMed](#)]
12. Solomon GE, Hilal SK, Gold AP, Carter S. Natural history of acute hemiplegia of childhood. *Brain.* 1970;93:107–20. [[PubMed](#)]
13. Sener RN, Jinkins JR. MR of craniocerebral hemiatrophy. *Clin Imaging.* 1992;16:93–7. [[PubMed](#)]
14. Stred SE, Byrum CJ, Bove EL, Oliphant M. Coarctation of midaortic arch presenting with monoparesis. *Ann Thorac Surg.* 1986;42:210–12. [[PubMed](#)]
15. Jacoby CG, Go RT, Hahn FJ. Computed tomography in cerebral hemiatrophy. *AJR Am J Roentgenol.* 1977;129:5–7. [[PubMed](#)]
16. Sheybanl L, Schaller K, Seeck M. Rasmussen encephalitis: An update. *Schweizer Archiv fur Neurologie und Psychiatrie.* 2011;162:225–31.