

Morgagnian hernia in adults and its laparoscopic management- A Case reportDr. Arjun Rao Y S¹, Dr. Lakshman Agarwal², Dr. Sumita A Jain³, Dr Prasant Maskara⁴**Abstract**

Congenital diaphragmatic hernias are a rare form of diaphragmatic hernias during adult life. Incidence of CDH is 1/5,000 in every live birth. 98% of congenital diaphragmatic hernias are Bochdalek (poster lateral), and 2% are Morgagni (retrosternal or parasternal) hernias.

We have reported a case of 56 yr old female with small intestinal obstruction. Diagnosed to be morgagnian hernia by CT scan. Patient was successfully treated with laparoscopic mesh hernioplasty. We have discussed the diagnosis and laparoscopic management of morgagnian hernia.

Keywords: Adult congenital diaphragmatic hernias, Laparoscopic management, Morgagni
^{1,4}Resident, ^{2,3} Professor, Department of Surgery, S M S Medical College, Jaipur (India)
Corresponding author mail: drarjunrao@gmail.com

Introduction:

Morgagni hernia occurs through a weakness in the anterior fibres of the diaphragm between its costal and sternal part, in the muscle free triangular space called the Larrey space thus also called Morgagni - Larrey type of congenital diaphragmatic hernia. It is also called retrosternal, parasternal, substernal and subcostosternal hernia. Through this space, pass the superior epigastric vessels, which is usually filled with fat. The pressure difference between the abdomen and the chest accelerate the hernia formation^[1].

In 1761, Giovanni Morgagni gave the earliest clear description of parasternal hernia through the foramina of Morgagni

(spaces of Larrey) through muscular hiatus on either side of the xiphoid process.

It occurs more commonly on the right, bilateral hernias are not unknown. It is more in women and obese people.^[1]

Sac is present at first but may rupture later, leaving no trace. It most commonly contains liver in Infants and omentum in adults however both colon and stomach can herniated later on.

The condition is often asymptomatic and is diagnosed incidentally during the investigation of other conditions. Most frequent symptoms are cramping pain, constipation from partial colonic obstruction. Gastric volvulus and small intestinal obstruction are less frequent.

Complete obstruction, incarceration, or strangulation is rare^[1]. Cardiorespiratory symptoms are less common than GI symptoms. Trauma, exercise and pregnancy can be the cause of its occurrence.

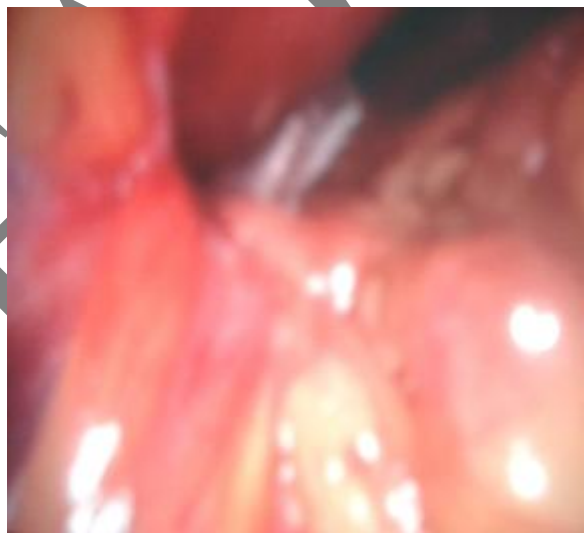
Case report

A 56 year female presented with history of Constipation and pain upper abdomen from 8 days. There was no history of similar complaints in the past. No past history of hospital admissions.

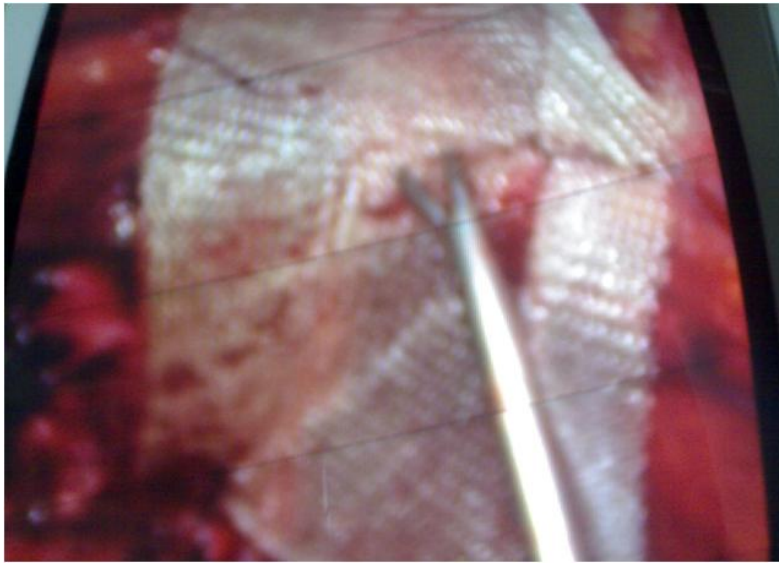
On clinical examination her abdomen was distended with moderate tenderness all over the abdomen.

Haematological and biochemical parameters were within normal limits. Chest radiograph showed elevated right diaphragm. On CT scan reported that small bowel loops were seen over the antero-medial part of right lobe of liver and it probably was Morgagnian Hernia.

We decided to reduce the morgagnian hernia laproscopically and repair the defect with a mesh. Surgery was performed through 3 ports one 10 mm port and two 5mm ports. After creating a pneumoperitoneum, the presence of diaphragmatic hernia on the right substernal region was confirmed.



It contained jejunum and omentum. The contents were reduced. The defect was approximately 4cms × 6cms. A proliene mesh of size 7cms x10cms was used to cover the defect in the diaphragm.



In the immediate post operative period Patient was shifted to ward .Patient was mobilized on the evening of the day of operation. Patient was given orally on POD 2. Patient was discharged on POD 3. Pt was followed up 1 week, 2 weeks, 1 month and 2 months after discharge. She is well and free of symptoms.

Discussion

The diagnosis of morgagnian hernia is made incidentally during routine investigations or during investigating for some other disorder presenting with similar signs and symptoms. A good chest X ray film will make you think in terms morgagnian hernia. CT or MRI clinches the diagnosis. Sensitivity of CT and MRI approaches 100% ^[2]. Barium meal or barium meal follow through is rarely needed.

Pericardial cyst, lobulated pneumothorax, lower lobe pneumonia, fat pad, mediastinal tumor or bronchogenic carcinoma may mimic the hernia. Thus CT and MRI scans are helpful in differentiating them from morgagnian hernia.

Surgery is indicated in all cases of morgagnian hernia.various approaches and modalities have been used including laparotomy, thoracotomy, laparoscopic, thoracoscopic, and combination of these. Presently laparoscopic mesh hernioplasty is the surgery of choice ^[3]. Though a thoracic approach is preferred in cases where there are lots of adhesions^[4].

Some authors advise the excision of the hernia sac so as not to leave an endothelial-lined cavity in the chest. However, this is controversial ^[5]. Others do not recommend this, believing that this

may result in massive bleeding and pneumomediastinum with subsequent circulatory and respiratory compromise [6, 7]

Smaller defects can be closed primarily but the large ones (larger than 20-30 cm²) have to be repaired using a prosthetic patch [8].

References:

1. Thomas W. Shields, Joseph LoCicero, Carolyn E. Reed, Richard H. Feins, General Thoracic Surgery, Volume 1.
2. Hussong RL Jr, Landreneau RJ, Colo FH Jr. Diagnosis and repair of Morgagni hernia. *Ann Thorac Surg* 1997; 63:1474-1475.
3. Yavuz N, Yigitbasi R, Sunamak O, As A, Oral C, Erguney S Laparoscopic repair of Morgagni hernia. *Surg Laparosc Endosc Percutan Tech*. 2006 Aug;16(4)
4. Nakashima S, Watanabe A, Hashimoto M, Mishina T, Obama T, Higami T. Advantages of video-assisted thoracoscopic surgery for adult congenital hernia with severe adhesion: report of two cases *Ann Thorac Cardiovasc Surg*. 2011;17(2):185-9.
5. Orita M, Okino M, Yamashita N, *et al*. Laparoscopic repair of a diaphragmatic hernia through the foramen of Morgagni. *Surg Endosc* 1997; 1:668-670.
6. Akin Tarim, Tarik Zafer Nursal, *et al*. Laparoscopic repair of bilateral Morgagni hernia. *Surg Laparosc Endosc Percut Tech* 2004; 14:96-97.
7. Newman L, Eubanks S, Me Farland B, *et al*. Laparoscopic diagnosis and treatment of Morgagni hernia. *J Laparoendosc Surg* 1997; 5 :27- 31.
8. Terrosu G, Brizzolari M, Intini S, Cattin F *et al*. Morgagni hernia: technical variation in the laparoscopic treatment. *Annali Italiani di Chirurgia*. 2012 Feb 6.