

**Plexiform Neurofibroma of Submandibular gland: A Case Report in Young Adult**Dr Anjana Arya<sup>1</sup>, Dr Ramesh Narula<sup>2</sup>, Dr Som Dutt Singh<sup>3</sup>, Dr Kusum Narula<sup>4</sup>**Abstract**

**Background:**-Tumours of neurogenic origin are rare in submandibular gland. Plexiform neurofibroma of the salivary glands is a rare benign tumour of submandibular salivary gland. **Case report:** - We present a rare case plexiform neurofibroma of submandibular gland. This patient presented with history of right side facial swelling for last 10 years .Initially ultrasound was done. A provisional diagnosis of salivary gland tumour was made. Later on Fine needle aspiration cytology (FNAC) was reported as chronic sialadenitis. An excisional biopsy was done and case diagnosed as plexiform neurofibroma of submandibular gland. **Conclusion:** - Clinicians have an important role in early diagnosis and alerting the patient about its future complications.

**Keywords:** Plexiform neurofibroma, sialadenitis, submandibular gland

<sup>1</sup>Associate Professor Pathology, <sup>2</sup>Associate Professor Orthopaedics, <sup>3</sup>Senior Resident Orthopaedics, <sup>4</sup>Demonstrator Community Medicine

Rohilkhand Medical College, Bareilly. (U.P), India

Corresponding author mail: [anjanaarya.singh15@gmail.com](mailto:anjanaarya.singh15@gmail.com)

**Introduction:** Neurofibroma is a benign peripheral nerve sheath tumour developed from nonmyelinating Schwann cells. Usually found in individuals with neurofibromatosis type 1 (NF-1), an autosomal dominant genetically inherited disease. They are locally infiltrative benign tumors that tend to grow slowly. Neurofibromas constitute only 0.4% of all salivary neoplasms. <sup>(1)</sup> It is subdivided into two broad categories: dermal and plexiform.

**Case report**

A 20 years old female visited the outpatient department of Surgery in our tertiary care centre with a complaint of a swelling in the right side of face. The patient first noticed the

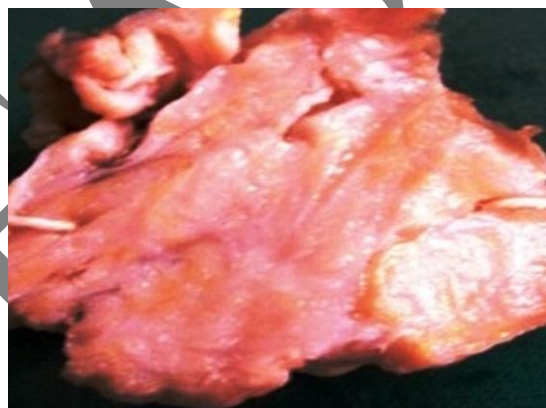Plexiform neurofibromas uncommon tumors of the salivary glands and extremely rare occurrence in the submandibular salivary gland. <sup>(2-5)</sup> It occurs earlier in life and are thought to be congenital defects. In our knowledge, only six cases are reported. We are presenting this case because of its rarity of presentation and mimic other salivary gland tumour.

swelling ten years back, which had an insidious onset and since then it had grown slowly to attain the present size. There was no history of fever, weight loss and any regression in size of swelling.

On examination, a firm swelling in the submandibular region of size 3x4cm, with irregular shape and irregular border was present. On palpation there was no local rise in temperature, no tenderness, no pulsation. No other significant intra oral findings were noted. No lymphadenopathy. There were no external features suggestive of NF-1 / NF-2 like macules, lich nodules. Her haemogram, routine urine examination, C-reactive protein, and kidney function test were also within normal limits. The ultrasonograph revealed a uniform, loculated hyperechoic mass. There was no evidence of calcification, cystic degeneration or

**Pathological findings:**

Gross specimen (Figure1) was unencapsulated, nodular, and white to grey in colour. On cut –cremish-white in colour.



**Figure1:- Gross specimen of Plexiform neurofibroma**

Representative sections (Figures 2a, 2b) from the tissue showed well-delineated, unencapsulated lesion predominantly showing fascicular arrangement. The lesion composed of nerve cell, fibroblast and perineural cells arranged in fascicles, cells having elongated serpentine

cervical lymphadenopathy. Based on the history and clinical presentation working diagnosis of salivary gland tumour was made. For the facial swelling however, patient was subjected to FNAC. Provisional diagnosis of FNAC was chronic sialadenitis due to sparely cellular.

The patient was then referred for excisional biopsy to the surgery department of RMCH, which was performed under general anaesthesia. After surgery, specimen sent to pathology department for histopathological examination.

manner and a scanty infiltrate of chronic inflammatory cells.

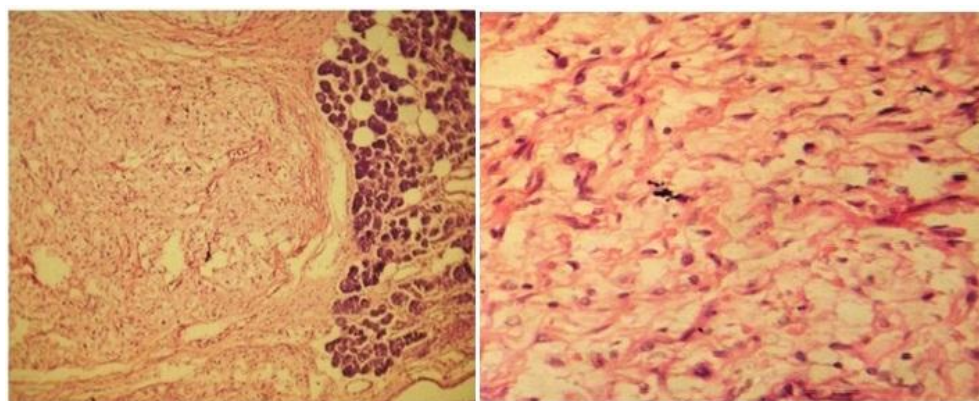
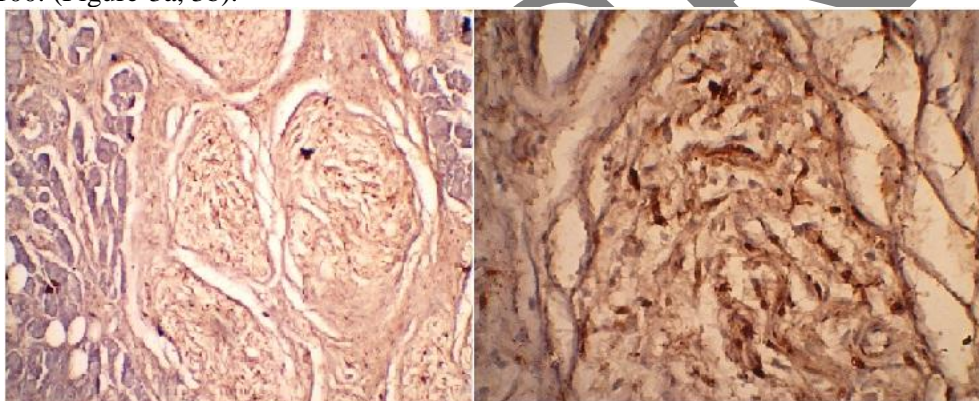


Figure:-2a, 2b

Hence histopathological diagnosis of plexiform neurofibroma was established. Immunohistochemical stain show positive of S-100. (Figure-3a, 3b).



**Table 1:** Compilation of different Authors studies

Author and year	Age of patient	Gender	Symptoms	Histopathological Diagnosis
Weitzner S.(1980)	3year	F	Submandibular mass with multiple neurofibromatosis	Plexiform neurofibroma
Tsutsumi T,Komat Suzaki A(1996)	29 year	F	Submandibular mass	Plexiform neurofibroma
Derekoy S, Sefali M ( 2000)	21 year	M	Submandibular mass with multiple neurofibromatosis	Plexiform neurofibroma
Bourgeois J.M, Radhi J,Den Ei L (2001)	3year	M	Submandibular mass with multiple neurofibromatosis	Plexiform neurofibroma
Aribandi M,Wood W.E, Elsten D.M and Weiss D.L (2006)	6year	F	Submandibular mass with multiple neurofibromatosis	Plexiform neurofibroma
TY Shekar, Gautam Gole, Shailaja Prabhala, Sheetal Gole(2010)	15 year	M	Submandibular mass	Plexiform neurofibroma
In this study	20 year	F	Submandibular mass	Plexiform neurofibroma

**Discussion:** Neurofibromas are benign nerve sheath tumors and subdivided into two broad categories: dermal and plexiform. Dermal neurofibromas are associated with a single peripheral nerve, while plexiform neurofibromas are associated with multiple nerve bundles. Neurofibromas constitute only 0.4% of all salivary neoplasms.<sup>1</sup> Plexiform neurofibromas of salivary glands are rare found in the submandibular gland. Most often had been described in the parotid gland.<sup>2-5</sup> They represent 14% of all benign mesenchymal tumors and 10% of non-epithelial salivary gland tumors.<sup>1,8</sup> Plexiform neurofibromas associated with 5-15% patients with neurofibromatosis-I.<sup>9</sup> Plexiform neurofibroma consistency appears as 'bag of worms' because of presence of soft areas interspersed with firm nodular mass.

The observation in our study was correlate and compared with study of different Authors. In our knowledge only 6 cases of plexiform neurofibroma of submandibular salivary gland have been reported. In our case patient was young adult. Similar age was reported by Tsutsumi T et al<sup>4</sup>, Derekoy S et al<sup>5</sup>. Whereas Bourgeois JM et al<sup>2</sup>, Aribandi M et al<sup>6</sup>, Weitzner S et al<sup>3</sup> reported that neurofibroma occurred in children and Shekar TY et al<sup>7</sup> reported that submandibular plexiform neurofibroma occur in adolescent.

Submandibular plexiform neurofibroma occurs in female patient in our case. Similarly Weitzner S et al<sup>3</sup>, Tsutsumi T et al<sup>4</sup>, Aribandi M et al<sup>6</sup> in all cases patient was female. Whereas Derekoy S et al<sup>5</sup>, Bourgeois JM et al<sup>2</sup>, Shekar TY et al<sup>7</sup> reported submandibular plexiform neurofibroma in male patient.

Derekoy S et al<sup>5</sup>, Bourgeois JM et al<sup>2</sup>, Aribandi M et al<sup>6</sup>, Weitzner S et al<sup>3</sup> all reported that patient presented with submandibular mass with multiple neurofibromatosis. Whereas Tsutsumi T et al<sup>4</sup>, Shekar TY et al<sup>7</sup> reported patients presented with only submandibular mass without multiple neurofibromatosis similar to our case.

In our case diagnosis of submandibular plexiform neurofibroma is made on histopathological examination similar to study by all cases.<sup>2-7</sup>

**Conclusion:** Plexiform neurofibromas cause pain, hypertrophy, functional abnormality and may turn malignant. The diagnostic yield of FNAC appears to be low so diagnosis of submandibular gland plexiform neurofibroma was based on histopathological examination. Neurofibroma has a neurogenic origin rather than a salivary gland and must be considered in the differential diagnosis of a submandibular mass. Clinicians have an important role in early diagnosis and alerting the patient about its future complications.

**References:**

1. Seifert.G, Miehke.A, Haubrich.J, et al. Pathology, Diagnosis, treatment, facial nerve surgery. Stuttgart: Georg Thieme verlag 1986:171-301.
2. Bourgeois JM, Radhi J, Den EiL. Plexiform neurofibroma of the submandibular gland in child. Can J Gastroenterol 2001; 15:835-37.
3. Weitzner S. Plexiform neurofibroma of the submandibular gland in children. Oral Surg oral Med Oral pathol 1980; 50:53-7
4. Tsutsumi T, oku T, Komazaki A. Solitary plexiform neurofibroma of the submandibular salivary gland. J Laryngol otol 1996;110:1173-75.
5. Derekoy S, Sefali M. Plexiform neurofibroma of the submandibular gland. J Laryngol Otol.2000; 114:643-5.
6. Aribandi M, Wood WE, Elston DM, Weiss DL. CT features of plexiform neurofibroma of the submandibular gland. AJNR Am J Neuroradiol 2006; 27:126-8.
7. Shekar TY, Gautam G, Prabhala S and Gole S. Plexiform neurofibroma: A rare tumor of submandibular salivary gland. J Surg Tech Case Rep 2010; 2(2): 81-3.
8. McDaniel RK. Benign mesenchymal neoplasms. In: Ellis GL, Auclair PL, Gnepp DR, editors. Surgical pathology of the salivary glands. Philadelphia: WB Saunders; 1991.pp.496-496.6.
9. Neurofibroma plexiform tumors. Available from: <http://www.madisonfoundation.org/content/3/4/display.asp>. [Last accessed on 2005 Dec 11].