

Apert's Syndrome- A Rare Craniofacial Anomaly

Gazi Sakina Rauf¹, Manu Prasad S², Vijayalakshmi Subramaniam³

Abstract

Introduction: Apert's Syndrome is a rare autosomal dominant disorder characterized by craniosynostosis, craniofacial anomalies, and severe symmetrical syndactyly (cutaneous and bony fusion) of the hands and feet. Other craniosynostosis syndromes such as Carpenter syndrome, Crouzon disease (craniofacial dysostosis), Pfeiffer syndrome and Saethre-Chotzen syndrome have clinical features that are similar to Apert's syndrome. **Case Presentation:** The case of a 10 month old infant with Apert's syndrome is presented here. The characteristic features of Apert's Syndrome are discussed. **Conclusion:** A multidisciplinary team approach comprising of neurosurgeons, craniofacial surgeons, plastic surgeons, otolaryngologists, orthodontists, orthopaedic surgeons ophthalmologists, radiologists, geneticists, paediatricians, clinical psychologists, speech and language pathologists is needed for the effective management of this condition.

Key words: Craniofacial anomaly, premature synostosis, syndactyly

¹Undergraduate resident, ²Consultant Craniofacial and Cleft surgeon, Centre for Craniofacial Anomalies, ³Associate Professor, Department of Otorhinolaryngology

Yenepoya Medical College, Yenepoya University, Deralakatte, Mangalore-575018 Karnataka, India

Corresponding Author mail address: yijisubbu@gmail.com Conflicts of Interest: None

Introduction

Apert's Syndrome (Acrocephalosyndactyly Type I), is a rare congenital disorder characterized by premature fusion of cranial sutures (craniosynostosis), malformations of skull, hands, face and feet [1, 2]. It is a branchial arch syndrome affecting the first branchial arch, the precursor of maxilla and mandible. Apert's syndrome is caused by mutations in a gene called fibroblast growth

factor receptor 2 which is located on chromosome 10 [3, 4]. The mode of inheritance is reported to be autosomal dominant and associated with advanced paternal age. However, sporadic occurrence of many cases has been reported, possibly representing new mutations [5]. This rare clinical abnormality has to be differentiated from other craniofacial syndromes such as

Carpenter syndrome (Kleeblattschadel, cloverleaf skull deformity), Crouzon disease (craniofacial dysostosis), Pfeiffer syndrome and Saethre-Chotzen syndrome^[6]. The case of a 10 month old infant with Apert's syndrome is reported here. The characteristic clinical features as well as multidisciplinary approach in the management of the case are discussed.

Case Report

A 10 month old infant presented with increased distension of head and fused digits of the hands and feet. The infant was a premature baby born at 8 months of gestation.

The baby developed impaired vision, abnormal shape of the skull, with mild exophthalmos of eye, and delayed milestones. The child failed to recognize objects. There was a delay in gross and fine motor skills as well as speech and language development. On examination there was facial disfigurement with frontal bossing.

Facial dysmorphic features such as beaked nose, short upper lip, hypoplastic maxilla, relative mandibular prognathism, crowding of teeth, frontal bossing, depressed nasal bridge, broad nasal bone, low set ears, long philtrum were present. Ophthalmological anomalies such as antimongoloid slant were present bilaterally. Orbits were shallow and displaced downwards and outwards. There was restriction of eye movement in elevation. Hypertelorism was present. There was simple hypermetropia in vertical meridian in right eye suggestive of astigmatism. Left eye had mixed type of astigmatism i.e myopia in vertical meridian and hypermetropia in horizontal meridian. Examination of digits of hands and feet revealed a grade III syndactyly. Examination of the oral cavity revealed a high arched palate and submucous cleft of the soft palate which extended till the hard palate (Figure 1). Examination of cardiovascular, respiratory system and abdomen was normal.

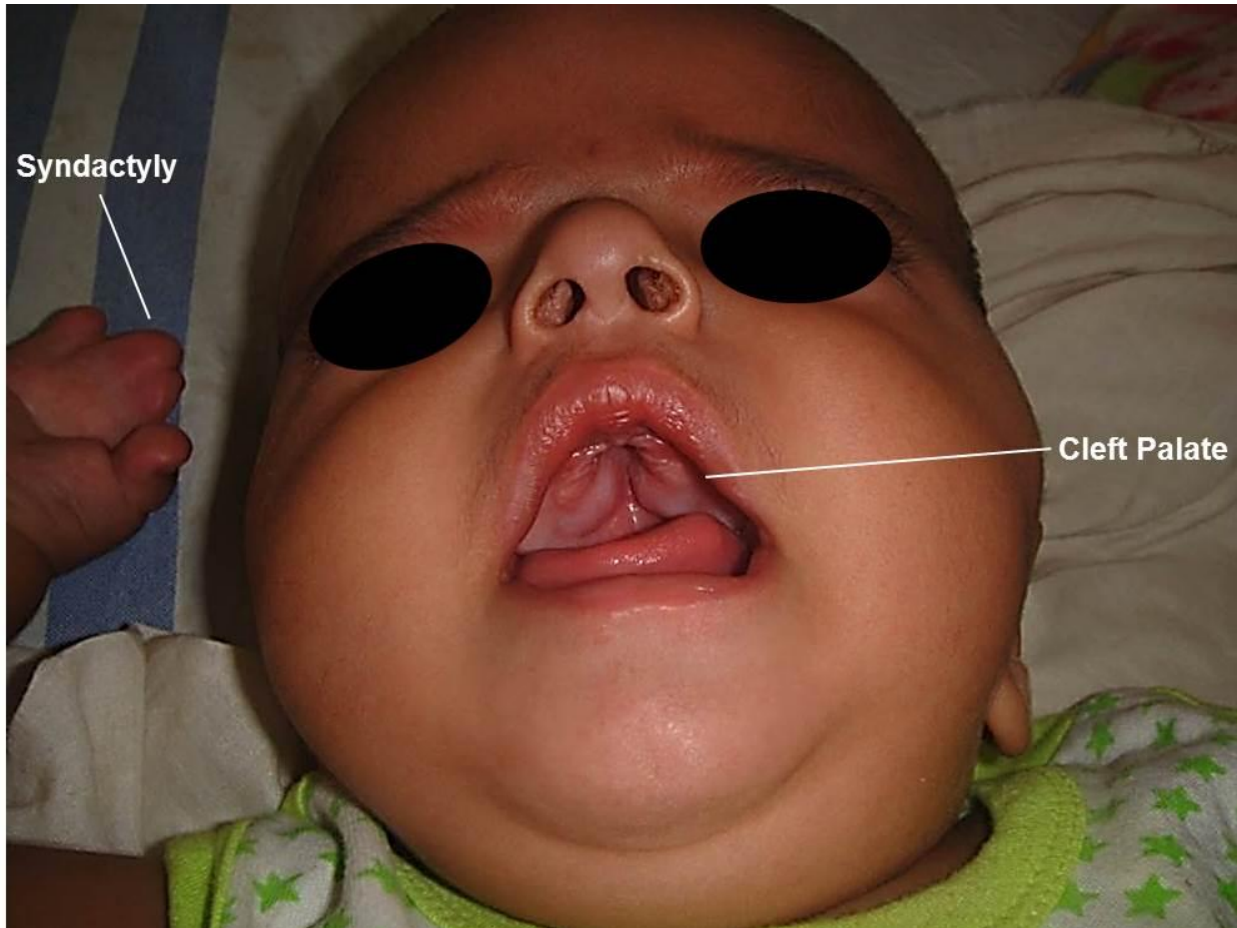


Figure 1: Clinical Photograph of the infant showing high arched palate, cleft of soft palate extending till the hard palate and syndactyly

Plain X-ray of the skull anteroposterior (AP) view showed obliteration of coronal and lambdoid suture lines with obvious bony continuity, mild ocular hypertelorism and crowding of teeth, Plain X-ray of the hand

AP view showed the fusion of the phalanges. Plain X-ray of the feet revealed the bony fusion of first and second metatarsals (Figure 2).

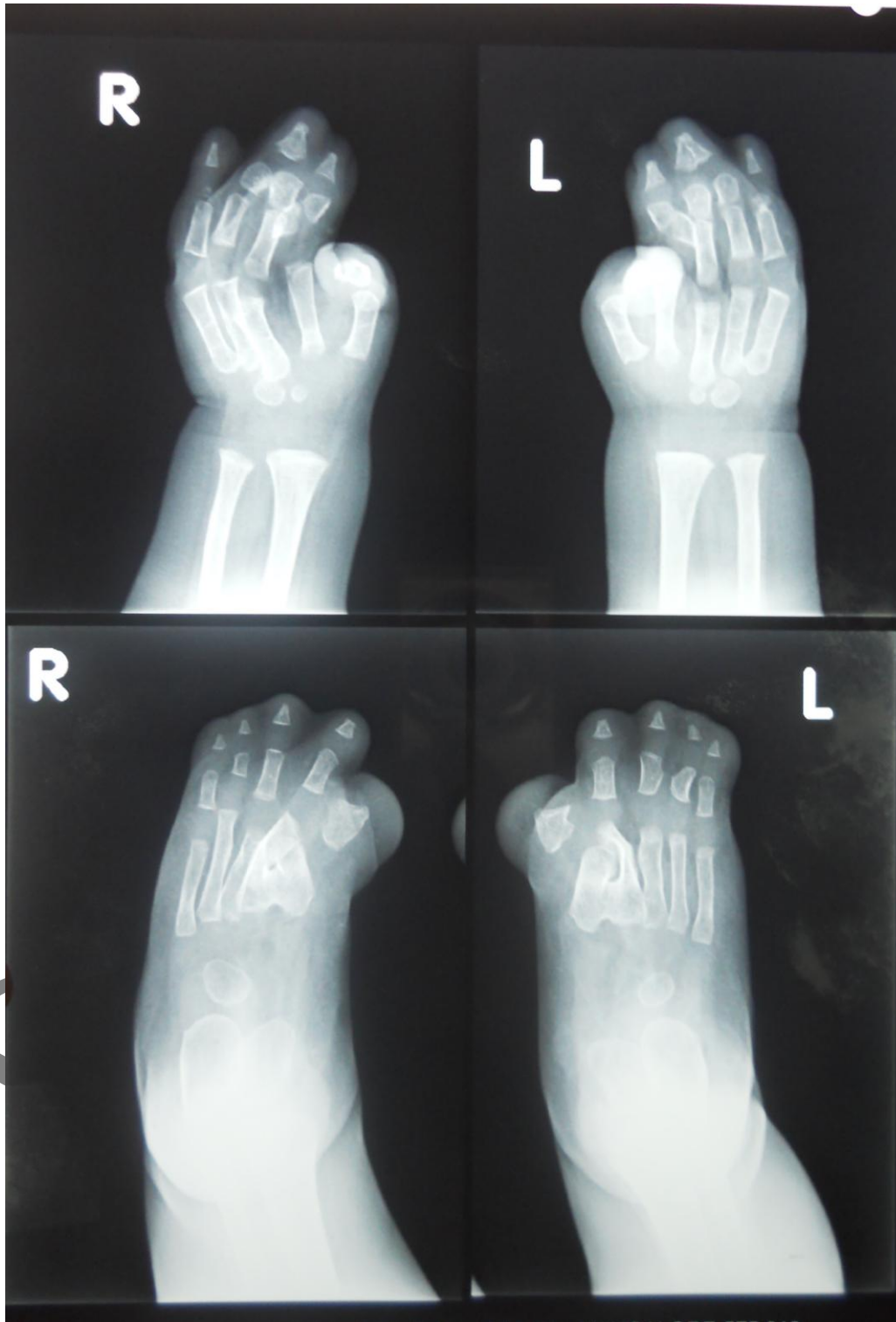

Figure 2: Plain X-ray of hands and feet showing fusion of phalanges and metatarsals

Computerized tomography (CT) scan of the skull with 3 –dimensional reconstruction showed increase in biparietal diameter with fusion of coronal sutures and partial fusion of lambdoid sutures suggestive of craniosynostosis causing brachycephaly. Partial agenesis of corpus callosum was also seen. Anterior and Posterior fontanella were widely separated (Figure 3, 4, 5). Mild prominence of frontal horn of lateral ventricle was also seen.

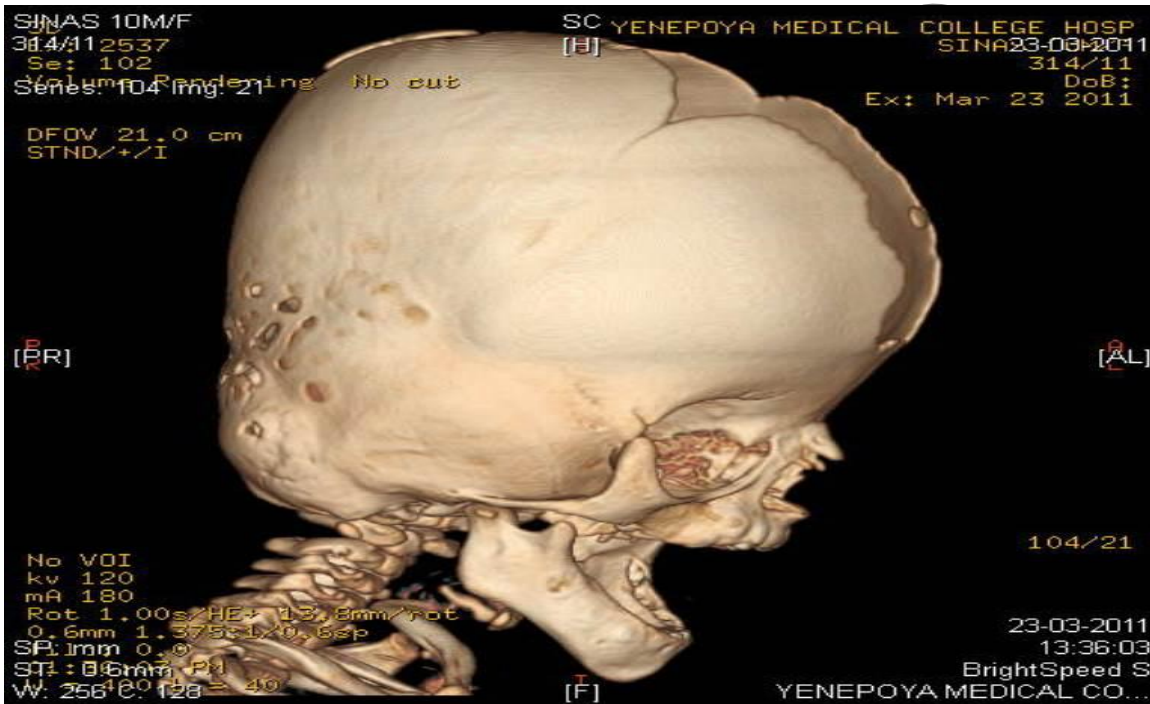


Figure 3: CT scan of the skull with 3–dimensional reconstruction showing flat occiput with fusion of coronal sutures and partial fusion of lambdoid sutures

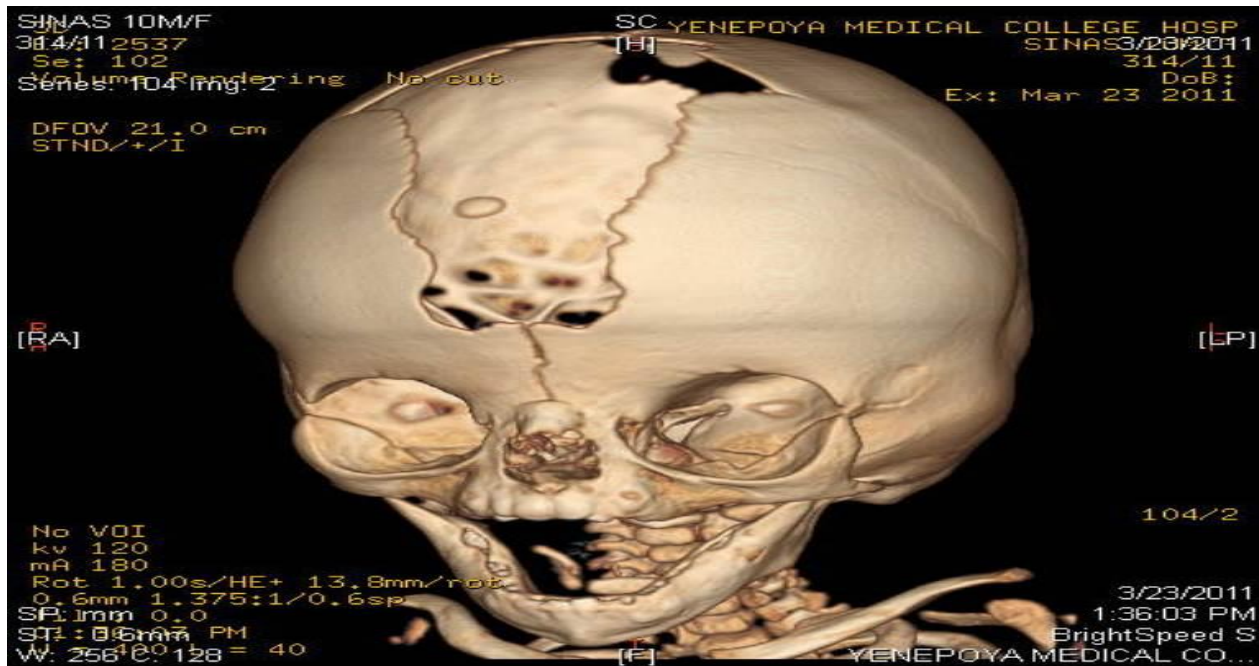


Figure 4: CT scan of the skull with 3-dimensional reconstruction showing craniosynostosis with wide anterior fontanelle

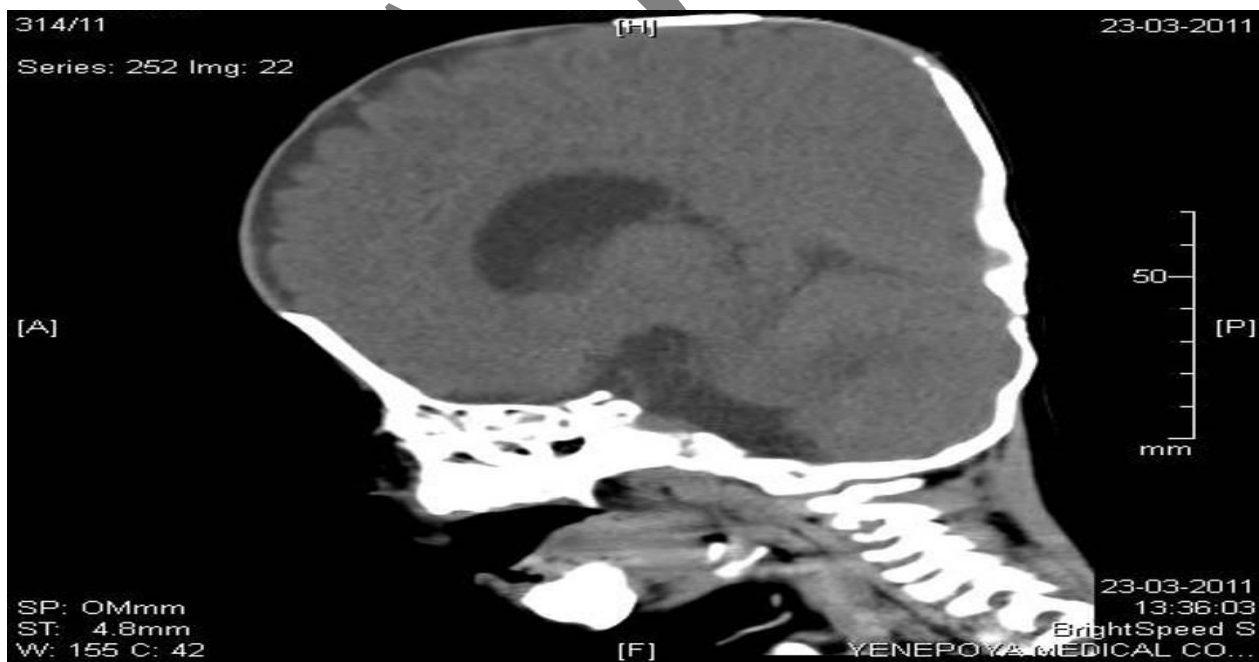

Figure 5: CT scan of brain showing partial agenesis of corpus callosum

Surgical management has been planned in several stages in order to (i) prevent further closure of coronal sutures and damage to the developing brain (ii) facilitate proper speech and (iii) to provide aesthetically and functionally acceptable life.

In this case, fronto-orbital advancement was done along with the release of the coronal and lambdoid sutures to permit normal growth of the brain and ventriculoperitoneal shunt was done to reduce hydrocephalus in **Stage 1**. This was followed by two flap palatoplasty (Bardach's technique) for management of cleft palate in **Stage 2**.

The following treatment is being further planned:

Stage 3: Le Fort III osteotomy and maxillary distraction advancement to correct the midfacial hypoplasia

Stage 4: Management of syndactyly by releasing the first and fourth web space early. This will be followed by lengthening of the thumb to increase the first web space. The second and third web spaces will be then released in order to establish a fully functioning hand. The aim is to make it possible for the child to grasp with his hands.

Stage 5: Correction of Ophthalmic and ear anomalies

The patient has improved with frontoorbital advancement and ventriculoperitoneal shunt. Patient is having proper growth of skull subsequent to surgery. The child has started to develop normal speech. Surgery for mid facial hypoplasia and syndactyly is being planned in the near future.

Discussion

Apert's syndrome (Acrocephalosyndactyly Type I) is a rare congenital anomaly described by Eugène Charles Apert, a French pediatrician, in 1906, in nine people sharing similar attributes and characteristics^[1]. It has a prevalence of 15.5 per million live births and accounts for 4.5% of all cases of craniosynostosis^[7].

There is a considerable overlap between the features of Apert's syndrome and other craniofacial syndromes particularly Carpenter syndrome (Kleeblattschadel, cloverleaf skull deformity), Crouzon disease (craniofacial dysostosis), Pfeiffer syndrome and Saethre-Chotzen syndrome^[6].

In Apert's syndrome, a unique fibroblast growth factor receptor 2 (*FGFR2*) gene mutations, that map to chromosome bands 10q25-q26 has been described. These mutations lead to an increase in the number

of precursor cells that enter the osteogenic pathway. Premature osteogenesis leads to fusion of sutures and the characteristic skeletal abnormalities. Once a suture becomes fused, growth perpendicular to that suture becomes restricted, and the fused bones act as a single bony structure. Compensatory growth occurs at the remaining open sutures to allow continued brain growth. However, complex, multiple sutural synostosis frequently extends to premature fusion of the sutures at the base of the skull, causing midfacial hypoplasia, shallow orbits, a foreshortened nasal dorsum, maxillary hypoplasia, and occasional upper airway obstruction^[3,4,9,10].

The diagnosis of Apert's syndrome is mainly dependent upon the clinical and the radiological findings since the molecular analysis for detection of the specific mutation is expensive. Apert's syndrome is characterized by craniosynostosis, midfacial hypoplasia and syndactyly of hands and feet with a tendency for fusion of bony structures. Premature fusion of coronal sutures results in an acrocephalic (cone-shaped) head with flat occiput, short anterior-posterior diameter, prominent elongated forehead and a short broad nose with a bulbous tip and reduced nasolabial

angle. Midfacial hypoplasia leads to retrusion of the middle third of the face and relative mandibular prognathism. Shortening of the bony orbit contributes to ocular features such as hypertelorism, proptosis, strabismus and down-slanting palpebral fissures^[8]. The patient reported here had most of these features.

The oral manifestations of Apert's syndrome include lateral swelling of the palatine processes, a cleft uvula, tooth crowding, bulging/thickened alveolar processes, and delayed dental eruption. The palatine process swelling may be due to accumulation of mucopolysaccharides which sometimes leads to pseudoclefting of the palate^[11]. The prevalence of a real cleft palate is reported to be seen in 25-75% of Apert syndrome subjects^[12]. In this case, the patient had submucous cleft in the soft palate which extended to the hard palate.

Skull radiography reveals craniosynostosis which usually involves coronal sutures^[13]. In this case, apart from fusion of coronal sutures, partial closure of lambdoid sutures was also present at 10 months itself. Hand radiography shows characteristic finding of complete syndactyly involving the second and fifth digits (mitten hands). Radiography of the feet can be

performed to evaluate for cutaneous and osseous syndactyly. The characteristic finding is complete syndactyly involving the second and fifth digits (sock feet). The patient reported here had syndactyly of both hands and feet.

Computerised tomography (CT) scan with comparative 3-dimensional reconstruction analysis of the calvaria and cranial bases has become the most useful radiological examination in identifying skull shape and presence or absence of involved sutures. CT scan precisely reveals the pathological anatomy and permits specific operative planning. Magnetic Resonance Imaging is the imaging modality of choice for detecting intracranial abnormalities. The intracranial malformations reported on neuroimaging include ventricular enlargement, corpus callosum hypoplasia, septum pellucidum hypoplasia, cavum vergae and arachnoid cysts. Many patients develop normal intelligence although mental retardation has been reported in some. This has been attributed to intracranial malformations, increased intracranial pressure or family environment [14, 15]. Partial agenesis of corpus callosum with prominence of lateral horn of ventricle was

noted in the CT scan in the case reported here.

Presence of cleft palate could predispose patients to recurrent ear infections besides causing speech difficulties. Psychosocial, speech and hearing assessment is important in patients with Apert's syndrome to undertake rehabilitative measures to prevent cognitive impairment and delay in speech and language development.

The main modality in the management of Apert's syndrome is surgery. The main aims of surgery in Apert's syndrome are to:

- Release the cranial sutures in order to permit a proper brain development
- Prevent hydrocephalus due to raised intracranial tension
- Repair the cleft in order to prevent nasal regurgitation as well as facilitate proper speech
- Correct midface hypoplasia to facilitate proper breathing and improve aesthetic appearance
- Release of syndactyly to provide a better grasp.

The other modalities of treatment include application of tear drops to prevent corneal ulcer and correct the refractive errors. The overall aim is to give the patient a functional

and socially acceptable life. Although. The timing of surgery is controversial, early surgical treatment for cranial malformations before the first year of life is suggested to minimize cognitive loss and maximize normal development ^[15,16]. A strong multidisciplinary team comprising of neurosurgeons, craniofacial surgeons, plastic surgeons, otolaryngologists, orthodontists, orthopedic surgeons, ophthalmologists, radiologists, geneticists, paediatricians, clinical psychologists, speech and language pathologists is necessary for the care of these patients to improve their quality of life.

Conclusion

It is essential to be aware of the clinical manifestations of Apert's syndrome so as to facilitate diagnosis and initiate appropriate treatment strategies in order to give the patient better quality of life. Effective management needs the collective efforts of a multidisciplinary team comprising of health care professionals. Counseling of parents regarding the necessity for treatment and motivating them to provide necessary support and family environment for the psychosocial development of these patients is also essential.

References

1. Apert M. De l'acrocephalosyndactylie. Bull Mem Soc Med Hop Paris. 1906; 23: 1310-1313.
2. Cohen MMJ. Craniosynostosis: diagnosis, evaluation and management. New York: Raven Press; 1986.
3. Wilkie AO, Slaney SF, Oldridge M, Poole MD, Ashworth GJ, Hockley AD, Hayward RD, David DJ, Pulleyn LJ, Rutland P, et al. Apert syndrome results from localized mutations of FGFR2 and is allelic with Crouzon syndrome. Nat Genet. 1995; 9(2):165-72.
4. Ibrahimi OA, Eliseenkova AV, Plotnikov AN, Yu K, Ornitz DM, Mohammadi M. Structural basis for fibroblast growth factor receptor 2 activation in Apert syndrome. Proc Natl Acad Sci U S A. 2001 19; 98(13):7182-7.
5. Chang CC, Tsai FJ, Tsai HD, Tsai CH, Hsieh YY, Lee CC, Yang TC, Wu JY. Prenatal diagnosis of Apert syndrome. Prenat Diagn. 1998; 18(6):621-5.
6. GeneReviews: FGFR-Related Craniosynostosis Syndromes <http://www.ncbi.nlm.nih.gov/books/NBK1455/> (Accessed on 18 December,2013)
7. Cohen MM Jr, Kreiborg S, Lammer EJ, Cordero JF, Mastroiacovo P, Erickson JD,

- Roeper P, Martínez-Frías ML. Birth prevalence study of the Apert syndrome. *Am J Med Genet.* 1992 1; 42(5):655-9.
8. Cohen MM Jr, Kreiborg S. A clinical study of the craniofacial features in Apert syndrome. *Int J Oral Maxillofac Surg.* 1996; 25(1):45-53.
9. Fanganiello RD, Sertié AL, Reis EM, Yeh E, Oliveira NA, Bueno DF, Kerkis I, Alonso N, Cavalheiro S, Matsushita H, Freitas R, Verjovski-Almeida S, Passos-Bueno MR. Apert p.Ser252Trp mutation in FGFR2 alters osteogenic potential and gene expression of cranial periosteal cells. *Mol Med.* 2007; 13(7-8):422-42.
10. Ibrahim OA, Chiu ES, McCarthy JG, Mohammadi M. Understanding the molecular basis of Apert syndrome. *Plast Reconstr Surg.* 2005; 115(1):264-70.
11. Kreiborg S, Cohen MM Jr. The oral manifestations of Apert syndrome. *J Craniofac Genet Dev Biol.* 1992; 12(1):41-8.
12. Letra A, de Almeida AL, Kaizer R, Esper LA, Sgarbosa S, Granjeiro JM. Intraoral features of Apert's syndrome. *Oral Surg Oral Med Oral Pathol Oral Radiol Endod.* 2007; 103(5):e38-41.
13. Cohen MM Jr, Kreiborg S. Suture formation, premature sutural fusion, and suture defect zones in Apert syndrome. *Am J Med Genet.* 1996 24; 62(4):339-44.
14. Yacubian-Fernandes A, Palhares A, Giglio A, Gabarra RC, Zanini S, Portela L, Plese JP. Apert syndrome: analysis of associated brain malformations and conformational changes determined by surgical treatment. *J Neuroradiol.* 2004; 31(2):116-22.
15. Renier D, Arnaud E, Cinalli G, Sebag G, Zerah M, Marchac D. Prognosis for mental function in Apert's syndrome. *J Neurosurg.* 1996; 85(1):66-72.
16. Marchac D, Renier D, Broumand S. Timing of treatment for craniosynostosis and facio-craniosynostosis: a 20-year experience. *Br J Plast Surg.* 1994; 47(4):211-22.