

## **Eyelid Cysticercosis - A Rare Case**

Kate Madhuri S.<sup>1</sup> Gawai Amita R.<sup>2</sup> Patne Shailesh<sup>3</sup>

### **Abstract**

Reports of orbital cysticercosis are uncommon despite high incidence of brain and ocular involvement. There are 24 cases of eyelid cysticercosis on record.<sup>1</sup> Here we report a case of eyelid cysticercosis in a 27 years old Hindu vegetarian female due to its rarity. The lesion was excised and the diagnosis of cysticercosis was given after histopathologic examination.

**Key words:** eyelid, cysticercosis, histopathology

<sup>1</sup>Professor and Head, <sup>2</sup>Senior Resident, <sup>3</sup>Junior Resident

Department of Pathology, ESI-PGIMS and Model Hospital cum ODC, Andheri (E). Mumbai, India.

Corresponding author mail: [dramita23gawai@gmail.com](mailto:dramita23gawai@gmail.com)

Source of support: Nil

Conflict of interest: None declared

### **Introduction**

Human cysticercosis is a parasitic infestation caused by cysticercus cellulosae, the larval form of cystode, Taenia solium (T. Solium). Cysticercosis in humans is acquired by ingestion of faecally contaminated food, water and vegetables containing ova of T. solium. The condition is endemic in Mexico, Africa, South East Asia, Eastern Europe, Central and South America and India.<sup>2,3,4</sup> Human cysticercosis predominantly affects central nervous system causing neurocysticercosis and also the eye causing ocular cysticercosis.<sup>5</sup> While intraocular infections by Cysticercus cellulosae are often found as part of a generalised systemic infestation, ocular adnexal involvement is rare.<sup>6</sup>

### **CASE HISTORY**

A 27 years old Indian female presented with gradually increasing swelling over right lower eyelid since 4 months. There was mild lower eyelid discomfort but no history of decreased vision. Her ophthalmic and medical histories were unremarkable. Her

visual acuity was 6/6 in the right and left eyes. Both pupils were symmetric and reactive to light with no relative afferent pupillary defect; colour vision was normal. No lid erythema or edema was present. Extraocular movements were full in all directions of gaze. Local excision of the lower eyelid swelling was done.

Gross examination of the tissue revealed 1.5cms diameter soft tissue mass. External surface was covered with fibro-fatty tags. Cut section was unremarkable.

Histopathologic examination of the eye lesion showed an inflammatory reaction around the cyst wall comprising of three distinct layers the outermost zone formed by dense fibrovascular connective tissue. The middle layer showing large histiocytes intermingled with fibroblasts and an inner layer containing neutrophils and eosinophils. The scolex and suckers and double row of hooklets was a prominent feature. (Figure 1)

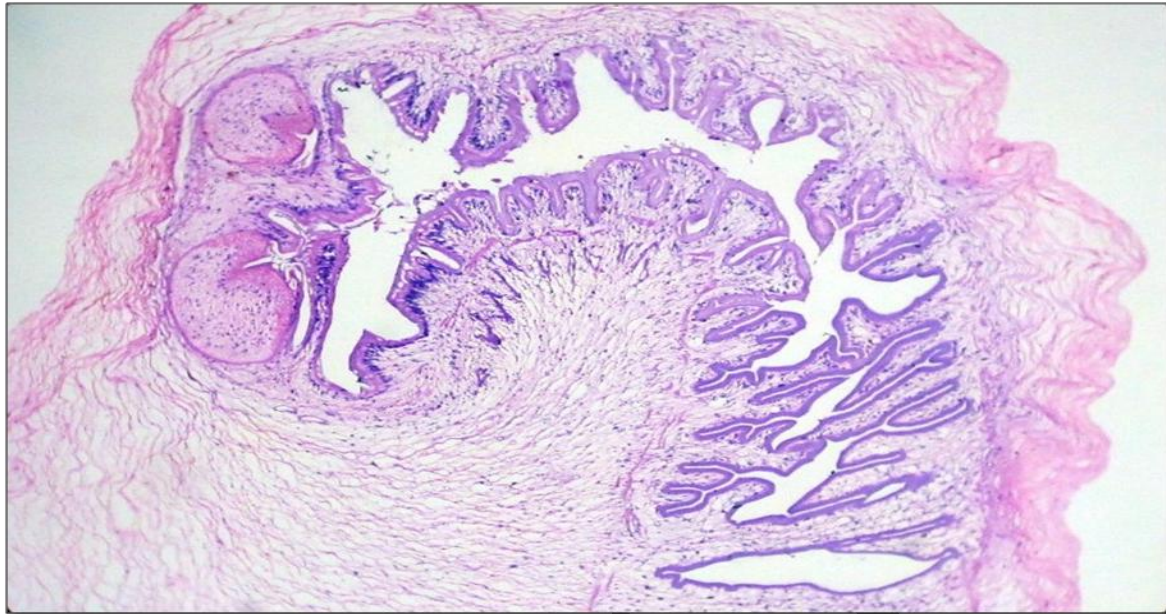
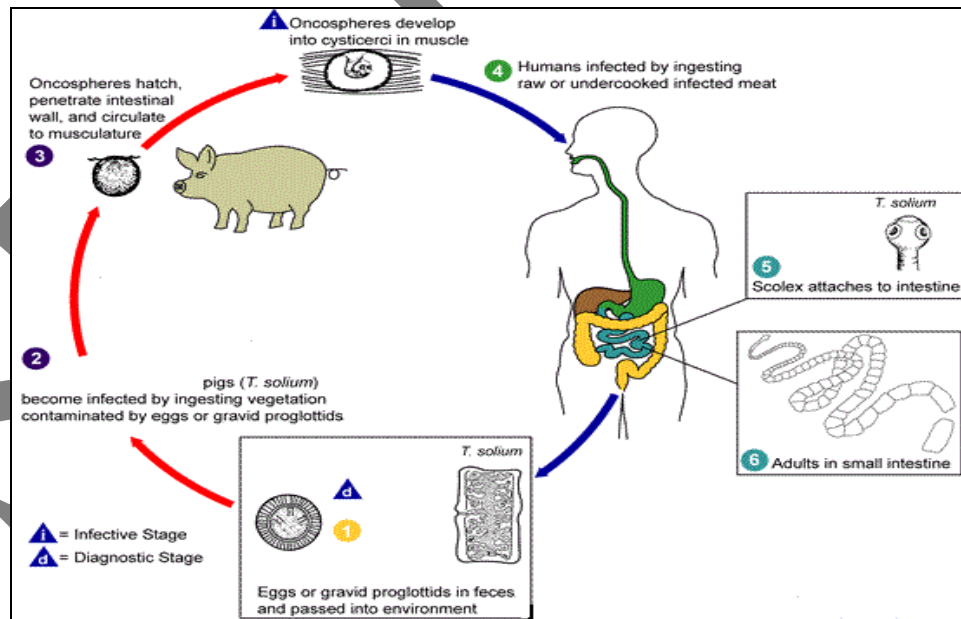


Figure 1:-Body of larva shows cuticular layer, prominent sucker and translucent hooklets (H&E x 40).

**Life Cycle**



source: [www.dpdcdc.gov/pdx](http://www.dpdcdc.gov/pdx).

The life cycle of *T. Solium* consists of mainly six steps;<sup>14</sup>

1. Infected humans (definitive hosts) excrete eggs or gravid proglottids in their faeces. In egg or proglottid form, *T. solium* is able to remain viable anywhere from days to months. *T. solium* can be diagnosed at this point in the life cycle. Autoinfection can also occur at this point via fecal-oral route. In this case, eggs or gravid proglottids re-enter the body through the mouth and often travel to the central nervous system, the muscles or eye, where they develop into cysticerci. The presence of cysticerci in these locations leads to the pathogenesis of cysticercosis.
2. Pigs (intermediate host) acquire infection by eating and digesting the eggs or gravid proglottids along with the parasitized vegetation.
3. The eggs or gravid proglottids migrate to pig's intestine and as oncospheres, break through the intestinal wall. Then, via the circulatory system, they embed themselves in the muscles of the pig and develop into cysticerci (the infective form of *T. solium*). Cysticerci have ability to persist in the muscle for many years.
4. Humans acquire the infection by eating the undercooked or raw flesh of an infected animal.
5. & 6 Cysticerci migrate to the small intestine of human host and develop into adult tapeworm form normally within two months. By attaching to the intestinal wall

with their scolices, these adult tapeworms may persist for long periods of time, even year.

### **Discussion**

Soemmering reported the first case of ocular cysticercosis in 1830.<sup>7</sup> The larva was demonstrated and extracted by Scott in 1836.<sup>8</sup> Ocular or adnexal involvement occurs in 13-46% of infected patients. While the most common site of localisation reported in Western Studies is posterior, in Indian literature the ocular adnexa is the most common site.<sup>9,10</sup>

Cysticercosis affects an estimated 50 million people worldwide. Ocular cysticercosis is endemic in tropical areas, such as sub-Saharan Africa, India, and East Asia. Other endemic areas include Mexico, Latin America, China, Indonesia and Eastern Europe.<sup>11</sup> In India, cysticercosis appears to be more prevalent in the North especially Bihar, Uttar Pradesh and Punjab. There are only few reports from the State of Kerala probably due to the high level of education and standards of hygiene and from Jammu and Kashmir, a Muslim majority State due to prohibition of pork consumption by religion.<sup>12,13,14</sup>

The most common form of systemic involvement is neurocysticercosis. Ocular and adnexal cysticercosis represents 13% to 46% of systemic disease.<sup>14</sup> Ocular cysticercosis can involve any part of the eye: approximately 4% involve the eyelid or orbit, 20% involve the subconjunctival space, 8% involve the anterior segment, and 68% involve the posterior segment (subretinal and intravitreal).<sup>14</sup>

*T. solium* is reported to be more common in younger age group with no sex predilection. Involvement of the left eye is more common as compared to the right, as the left internal carotid artery arises directly from the arch of aorta and disseminates the parasites more towards left eye.<sup>9</sup> However, in our case right lower eyelid was affected. Clinically patients of eyelid cysticercosis presents with subcutaneous, painless, enlarging mass.

Diagnosis of cysticercosis is usually made on history, clinical examination and by histopathology. The clinical manifestations of ocular cysticercosis, like elsewhere in the body are determined by the location, size and by the host's immune status and inflammatory reactions.<sup>15</sup> It is believed that the viable cysts, evoke little inflammatory response, while the degenerating cyst rapidly increases in size due to osmotic regulation and causes compression of the surrounding tissues and release of antigens into the surrounding tissue inducing inflammatory response.<sup>15</sup> In the present case clinical findings were nonspecific, hence non-diagnostic. However, the histopathological examination of the excised lesion confirmed the diagnosis of eyelid cysticercosis.

### **Conclusion**

Cysticercosis is a global public-health problem, especially in developing countries including India. Since cysticercosis is a preventable and eradicable disease, appropriate measures like health education, mass awareness, better medical facilities, mass treatment of *T. solium* carriers, and restriction on sale of contaminated pork may help to reduce the

disease burden in the endemic areas. It is important to carry out a detailed medical evaluation in every case, in order to exclude the presence of the parasite at other sites especially while examining biopsies from the eye. Increased awareness of typical and atypical presentation of orbital cysticercosis, coupled with high index of clinical suspicion, may help in early diagnosis.

### **References**

1. Nath K, Gogi R, Krishna G. Orbital Cysticercosis. *Indian J Ophthalmol*.1977;25:24-27.
2. Cano MR. ocular cysticercosis. In:Ryan SJ, editors. *Retina*. CV Mosby: St. Louis;1989.p.583-587.
3. Parija SC, Sahu PS. A serological study of human cysticercosis in Pondicherry. *J communicable diseases*. 2003;35:234-237.
4. Veliath AJ, Ratnakar C, Thakur LC. Cysticercosis in South India. *J Trop Med Hyg*.1985;88:25-29.
5. Brown J, Voge M. Cysticercosis. A modern day plague. *Pediatr Clin North Am*.1985;32:953-969.
6. DiLoreto DA, Kennedy RA, Neigel JM, Rootman J. Infestation of extraocular muscle by cysticercus cellulosae. *Bri J Ophthalmol* 1990;74:751-752.
7. S Kaliaperumal, VA Rao, S C Parija. Cysticercosis of the eye in South India-a case series. *Indian J Med Microbiol* 2005;23(4):227-230.
8. Duke-Elder S, editors. *Cysticercosis, System of Ophthalmology*. CV Mosby: St Louis;1978. P. 40.

9. Malik SRK, Gupta AK, Choudhry S. Orbital cysticercosis. *Am J Ophthalmol.* 1968;66:1168.
10. Sivareddy P, Satyendram OM. Ocular cysticercosis. *Am J Ophthalmol.* 1964;57:664.
11. Pushkar N, Bajaj MS, Chandra M. Ocular and orbital cysticercosis. *Acta Ophthalmol Scand.* 2001;79(4):408-413.
12. Prasad KN, Prasad A, Verma A and Singh AK. Human cysticercosis and Indian scenario: a review; *J. Biosci.* 2008; 33(4): 571-82.
13. Prasad KN, Chawla S, Jain D, et al Human and porcine *Taenia solium* infection in rural north India. *Trans R Soc Trop Med Hyg.* 2002; 96: 515-16.
14. Sonam A. B Saurabh K. Sushil K. Ruchi G. et al . Orbital cysticercosis. *Delhi Journal of Ophthalmology.* 2012;23(2):99-103.
15. Madigubba S, Vishwanath K, Reddy G, Vemuganti G K. Changing trends in ocular cysticercosis over two decades: An analysis of 118 surgically excised cysts. *Indian J Med Microbiol* 2007;25:214-9.

**Acknowledgement** – We are grateful to Dr. Meenakshi Mathur, Dean, ESIPGIMSR, Andheri(e) for her encouragement and support.