

Aggressive Management Of Ameloblastoma In Mandible: A Case Report

Dr Sanjay Byakodi*, Dr Anirudha Varekar**, Dr Shridevi Adaki***

* Associate Professor Dept of Oral & Maxillofacial Surgery, ** Associate Professor Dept of Oral & Maxillofacial Pathology,

*** Associate Professor dept of Oral Medicine, Bharati Vidyapeeth Dental College and Hospital Sangli. Maharashtra, India.

Abstracts: Background: Ameloblastoma is a rare, benign tumor of odontogenic epithelium much more commonly appearing in the lower jaw than the upper jaw. These tumors are rarely malignant or metastatic and progress slowly, the resulting lesions can cause severe abnormalities of the face and jaw. There are various treatment modalities available, here we present a case of aggressive Ameloblastoma treated by segmental resection of mandible. We have discussed the various treatment modalities suitable for treatment. [Byakodi S NJIRM 2015; 6(5):115-117]

Key Words: Ameloblastoma, Carnoy's solution, odontogenictumour.

Author for correspondence: Dr Sanjay Byakodi, Associate Professor Dept of Oral & Maxillofacial Surgery, Bharati Vidyapeeth Dental College and Hospital Sangli. Maharashtra, India. Email: sanjaybyakodi@gmail.com

Introduction: Ameloblastoma is a rare, benign tumor of odontogenic epithelium much more commonly appearing in the lower jaw than the upper jaw^[1]. This type of odontogenic neoplasm was designated as an adamantinoma in 1885 by the French physician Louis-Charles Malassez^[2]. It was finally renamed to the modern name ameloblastoma in 1930 by Ivey and Churchill^[3]. While these tumors are

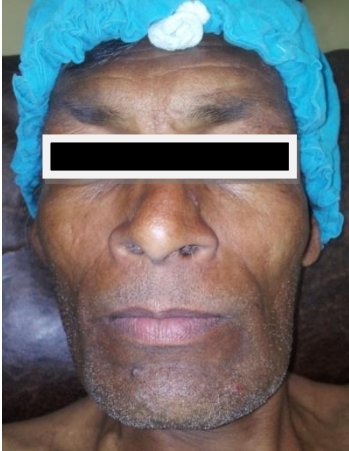rarely malignant or metastatic and progress slowly, the resulting lesions can cause severe abnormalities of the face and jaw. Additionally, because abnormal cell growth easily infiltrates and destroys surrounding bony tissues, wide surgical excision is required to treat this disorder. There are three main clinical subtypes of ameloblastoma: unicystic, multicystic, peripheral.^[7] The peripheral subtype composes 2% of all ameloblastomas.^[2] Of all ameloblastomas in younger patients, unicystic ameloblastomas represent 6% of the cases.^[2] Ameloblastomas are often associated with the presence of unerupted teeth. Symptoms include painless swelling, facial deformity if severe enough, pain if the swelling impinges on other structures, loose teeth, ulcers, and periodontal disease. Lesions will occur in the mandible and maxilla, although 75% occur in the ascending ramus area and will result in extensive deformities of the mandible. The lesion has a tendency to expand the bony cortices because slow growth rate of the lesion allows time for periosteum to develop thin shell of bone ahead of the expanding lesion. This shell of bone cracks when palpated and this phenomenon is referred to as "Egg Shell Cracking" or crepitus, an important diagnostic feature. Ameloblastoma is tentatively diagnosed

through radiographic examination and must be confirmed by histological examination. Radiographically, it appears as radiolucency in the bone of varying size and features sometimes it is a single, well-demarcated lesion whereas it often demonstrates as a multiloculated "soap bubble" appearance. Resorption of roots of involved teeth can be seen in some cases, but is not unique to ameloblastoma. Treatment options include conservative:-Enucleation and Carnoy's solution, Curettage and Carnoy's solution or Marsupialization. Radical treatment options include: Marginal Mandibulectomy, Segmental Resection, Hemimandibulectomy, Total Resection. Here we present a case of extensive Unicystic Ameloblastoma involving left body and ramus of mandible which required segmental resection.

Case Report: 56 year old male patient visited the department of Oral and Maxillofacial Surgery Bharati Vidyapeeth Dental College and Hospital Sangli with chief complaint of swelling in the left side of the face since 6 months. Patient was apparently alright 6 months back then he noticed swelling in the left lower side of the face. Initially it was small in size and gradually increased to the present size. It was not associated with pain. He visited dentist 2-3 months back and got his mandibular left posterior teeth extracted which were mobile. But swelling did not subside. 1 month back biopsy was done and tissue was taken from the same region for the histopathologic examination and histopath diagnosis of Ameloblastoma was made. Presently when he visited us Extraoral examination revealed diffuse swelling in the left lower third of the face. Overlying skin appears to be normal. On palpation

swelling was hard in consistency and non tender [Fig 1].

Figure 1: Extra Oral Photograph showing diffuse swelling in the left lower mandible



Intra-oral examination revealed unhealed area distal to 36 which was due to prior biopsy [Fig2].

Figure 2: Intra-oral photograph showing unhealed area distal to 36 which was due to prior biopsy

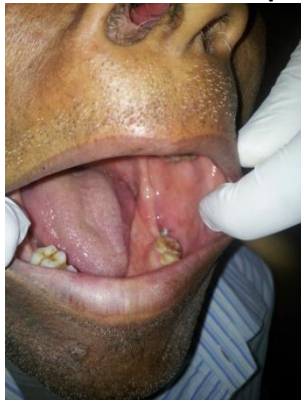
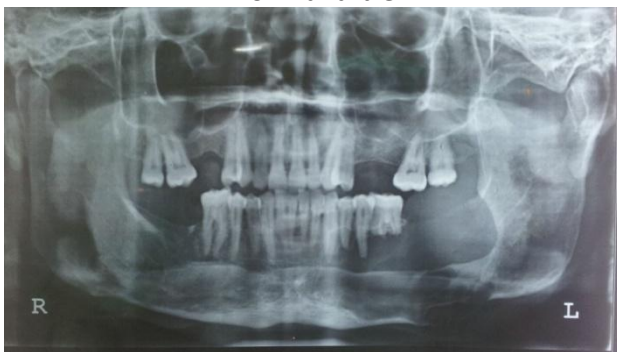
Figure 3: Panoramic radiograph showing huge ill-defined radiolucency involving body and ramus of mandible.

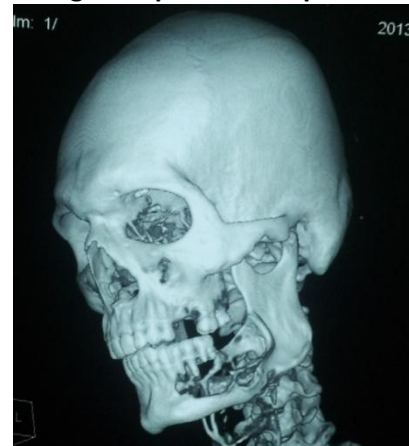

Panoramic radiograph revealed huge ill-defined radiolucency extending from apical region of 34 till

midramus of the mandible and from alveolar crest of 37, 38 region to inferior border of mandible. Discontinuity of the inferior border seen. Complete radiolucency seen along with septae in some areas. External root resorption seen with 36 along with interdental bone loss with 34 and 35 [Fig3].

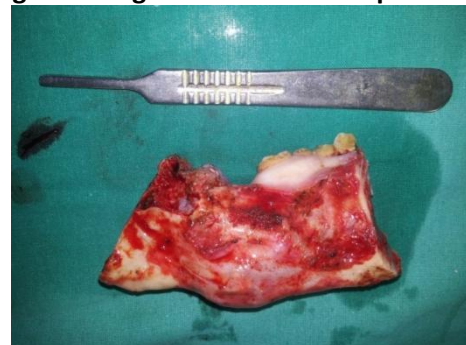
3D reconstruction of the mandible revealed osteolytic lesion extending from premolar region to midramus region of mandible with extensive loss of buccal and lingual cortical plates. There were extensive regions of perforation of buccal as well as lingual cortical plates and loss of continuity in the lower border [Fig4].

Figure 4: 3D reconstruction of the mandible showing multiple areas of perforation



The radiographic findings were strongly in support of segmental resection, so segmental resection of the left mandible was done and specimen was submitted for histopathology [Fig5]. Histopathological diagnosis was Unicystic ameloblastoma – mural variant.

Figure 5: Segmental Resection specimen



Discussion: It is considered to be the most common odontogenic tumor. It is a tumor of the enamel organ without formation of enamel. Robinson has

defined it as: Unicentric, nonfunctional, intermittent in growth, anatomically benign and clinically persistent^[4]. The importance of this tumor lies in its common occurrence, locally invasive behavior which causes marked deformity and serious debilitation. They also demonstrate increased recurrence rate after surgery. Unicystic ameloblastoma typically presents as a unilocular radiolucency containing an impacted tooth. They typically infiltrate through the medullary bone, therefore the radiographic margins are not accurate indicators of the extent of involvement. Expansion of buccal and lingual cortical plates, displacement and root resorption may also be seen. Ameloblastoma is highly recurrent lesion. Reasons for reoccurrence of Ameloblastoma are inadequate removal of primary, Presence of island tissue in medullary spaces, Implantation during enucleation or curettage or Soft tissue reoccurrence. Treatment options include conservative: -Enucleation and Cornoy's solution, Curettage and Cornoy's solution or Marsupialization. Radical treatment options include: Marginal Mandibulectomy, Segmental Resection, Hemimandibulectomy, Total Resection. Conservative treatment should be considered whenever the lesion is small or the patient is young. Radical treatment should be considered whenever the lesion is Large, Thinning of lower border of mandible, extensive perforation of buccal or lingual cortices, Involvement of inferior alveolar canal or a large solid or multicystic Ameloblastoma is found. In a detailed study of 345 patients, chemotherapy and radiation therapy seemed to be contraindicated for the treatment of ameloblastomas.^[1] In the previous reports, conservative treatments for ameloblastoma appeared to have failed to control local recurrences. Sehdev *et al*,^[5] reported recurrence after the conservative approach (curettage) in more than 90% of 92 ameloblastomas. Shatkin and Hoffmeister^[6] reported that 86% of 20 mandibular ameloblastomas recurred after curettage compared with a 14% recurrence rate after en bloc resection.

Conclusion: As the reoccurrence rate is high any case of ameloblastoma treated by conservative method should be followed for atleast 10 years and doubtful patients for follow up should be better treated by radical approach.

References:

1. Reichart PA, Philipsen HP, Sonner S. (March 1995). "Ameloblastoma: biological profile of 3677 cases". *Eur J Cancer B Oral Oncol*. **31B** (2): 86–99. PMID 7633291.
2. L. Malassez (1885). "Sur Le role des debris epitheliaux papdentaires". *Arch Physiol Norm Pathol* **5**: 309–340 6:379–449.
3. R.H. Ivey, H.R. Churchill, (1930). "The need of a standardized surgical and pathological classification of tumors and anomalies of dental origin,". *Am Assoc Dent Sch Trans* **7**: 240–245.
4. W. G. Shafer, M. K. Hine, and B. M. Levy, Shafer's Textbook of Oral Pathology, Elsevier, 5th edition, 2006.
5. Sehdev MK, Huvos AG, Strong EW, Gerold FP, Willis GW. Ameloblastoma of maxilla and mandible. *Cancer*. 1974;33:324–33. [PubMed]
6. Shatkin S, Hoffmeister FS. Ameloblastoma: A rational approach to therapy. *Oral Surg Oral Med Oral Pathol*. 1965;20:421–35. [PubMed]

Conflict of interest: None

Funding: None

Cite this Article as: Byakodi S, Varekar A, Adaki S Aggressive Management Of Ameloblastoma In Mandible: A Case Report <i>Natl J Integr Res Med</i> 2015; 6(5): 115-117
--