

## Systemic Associations of Branch Retinal Vein Occlusion

Nitin Nema\*, Abha Verma\*, Smita Patel\*, Prakhar Singhai\*, Rajendra Malviya\*\*

Department of Ophthalmology\*, Department of Ophthalmology and Consultant, Saraswati Eye Hospital\*\*

**Abstracts:** Background: Retinal vein occlusion is a commonly encountered vascular disorder affecting the retina. Systemic diseases have been implicated in the pathogenesis of branch retinal vein occlusion (BRVO). Many systemic risk factors of BRVO are reported from studies done in various countries. However, there is scarcity of reports of systemic associations of BRVO in Indian population. Purpose: To find the systemic associations of BRVO. Materials and Methods: Medical records of patients of BRVO visiting the tertiary eye care center of a medical college during the past two years were retrieved. Their demographic presentations and systemic associations were analyzed. Results: One hundred and fourteen patients of BRVO with male:female ratio of 2.3:1 and having a mean age of  $58 \pm 9.5$  years were analyzed. Seventy-five (65.8 %) patients were hypertensive, 32 (28.1 %) had hyperhomocysteinemia, 26 (22.8 %) were suffering from diabetes mellitus and 20 (17.5 %) were dyslipidemic. Twenty (17.5 %) patients were addicted to tobacco in some or the other forms whereas 18 (15.8 %) patients were smokers. Conclusion: The first step in the management of BRVO is to identify the risk factors associated with the disease in order to correct them. A joint effort is needed between the ophthalmologist and the physician to treat this sight-threatening retinal condition. [Nema N NJIRM 2015; 6(2):31-36]

**Key Words:** Retinal vein occlusion; Hypertension; Hyperhomocysteinemia; Arteriosclerosis; Tobacco; Smoking

**Author for correspondence:** Nitin Nema, Department of Ophthalmology, Saraswati Eye Hospital, Sri Aurobindo Medical College & PG Institute, Indore. E-mail: nemanitin@yahoo.com

**Introduction:** Branch retinal vein occlusion (BRVO) is the second most common retinal vascular disease after diabetic retinopathy. It mainly affects the elderly persons over the age of 70 years.<sup>1</sup> It is three times more common than central retinal vein occlusion.<sup>2</sup>

The exact etiology of BRVO is still presumptive, it is most likely due to thrombotic event.<sup>3</sup> Systemic diseases play an important role in the pathogenesis of BRVO. Hypertension, diabetes mellitus, dyslipidemia, systemic vasculitis and hypercoagulable diseases are some of the commonly encountered systemic conditions associated with BRVO. These conditions enhance the process of arteriosclerosis; the hardened artery ultimately causes occlusion of a branch of central retinal vein at the arterio-venous crossing. A plethora of treatment modalities are available for managing BRVO. They all become ineffective if the underlying associated systemic condition is not addressed properly. Therefore, the treating clinician must be aware of the systemic risk factors of BRVO so that the condition can be treated efficiently.

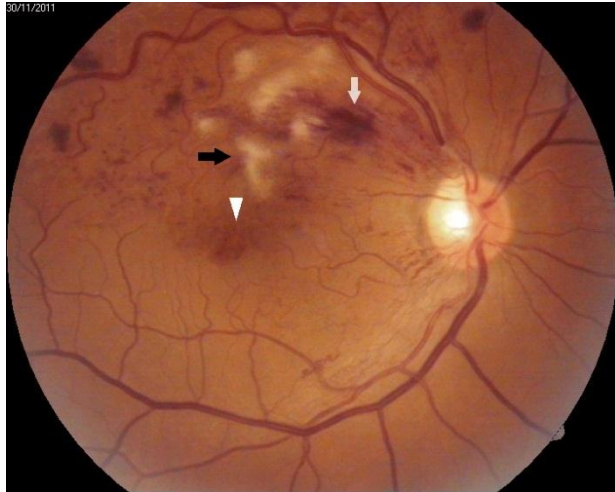
Most of the studies to find an association between the systemic risk factors and retinal vein occlusion are done in Caucasians.<sup>4-7</sup> There are only a few

studies from Asia and particularly from India.<sup>8-12</sup>

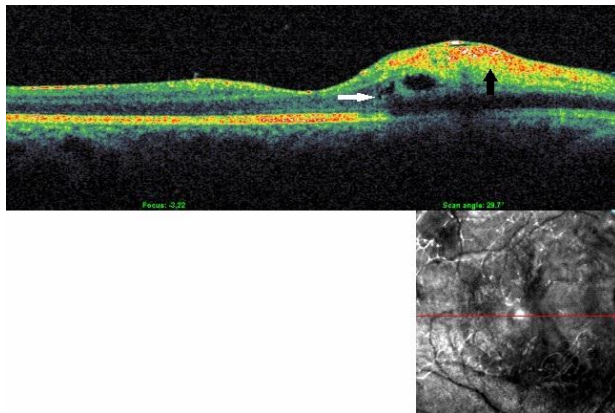
We embarked on the study to find the systemic risk factors of BRVO that were prevalent in patients visiting the tertiary care hospital.

**Material and Method:** The medical records of all patients of BRVO who visited the department of Ophthalmology during the past two years were retrieved. Ethical clearance was obtained from the Institutional Ethical Committee. A detailed history was recorded that included the demographic characteristics, duration of ocular complaints and associated systemic diseases. Ocular examination included recording of visual acuity, anterior segment examination on slit-lamp, intraocular pressure measurement by applanation tonometry and dilated fundus examination. Fundus details were charted and photographic documentation was done using digital fundus camera. BRVO was characterized by intraretinal hemorrhages with or without exudates in the sector of the retina drained by the occluded vein (**Figure 1**). Optical coherence tomography was performed to detect macular edema and thickness and monitor the response to the treatment instituted (**Figure 2**). Fluorescein angiography was done when needed to document macular edema and/or macular ischemia (**Figure 3**).

**Figure 1: Fundus image of right eye showing superotemporal branch vein occlusion with multiple intraretinal hemorrhages (white arrow), cotton-wool spots (black arrow) and macular edema (arrow head)**



**Figure 2: OCT image showing increased retinal thickness with cystoid spaces (white arrow) and multiple superficial intraretinal hemorrhages (black arrow) causing backscattering in a case of branch retinal vein occlusion**

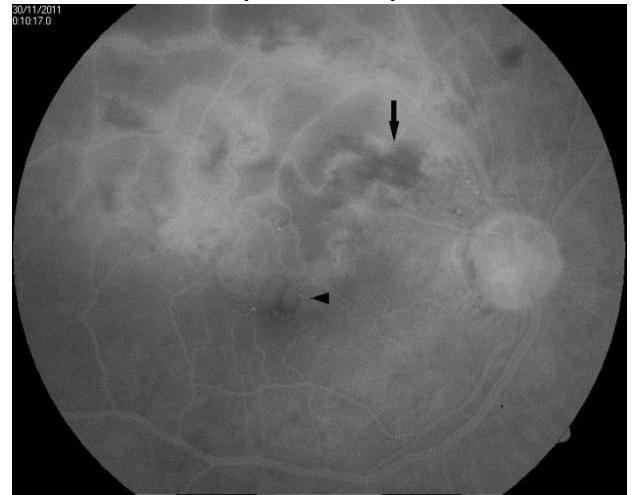

All patients were examined by a physician to diagnose the systemic co-morbidities and to treat them. The patients underwent blood investigations that included blood sugar estimation (both fasting and post prandial), glycosylated hemoglobin, complete blood count, lipid profile, and serum homocysteine.

The patients were given treatment in the form of intravitreal injections of anti-vascular endothelial growth factor agents (bevacizumab or ranibizumab) or corticosteroids (dexamethasone or triamcinolone acetonide) and laser photocoagulation. They were also educated and

motivated to manage their systemic conditions properly, as advised by the physician.

**Figure 3 : Late phase fluorescein angiogram of same patient as in figure 1 showing areas of blocked fluorescence (black arrow) corresponding to intraretinal hemorrhages and cotton-wool spots and leakage of dye in macular area (arrow head)**



**Results:** Over a period of two years, from September 2012 to September 2014, 114 patients of BRVO were examined in the out-patient department of Ophthalmology. Nine (7.9 %) patients had bilateral ocular involvement.

Out of 114 patients, there were 80 (70.1 %) males and 34 (29.9 %) females (**Figure 4**). The male to female ratio was 2.3:1. The age of the patient ranged from 37 to 80 years with a mean age  $58 \pm 9.5$  years (**Table 1**).

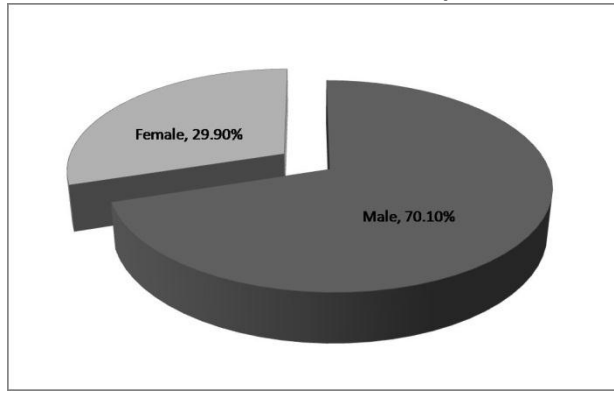
**Table 1: Age and sex distributions of Branch Retinal Vein Occlusion patients**

Age group (in years)	Male	Female	Total no. of patients (n)
<40	4	-	4
41-50	12	16	28
51-60	36	8	44
61-70	18	8	26
>70	10	2	12
<b>Total</b>	<b>80</b>	<b>34</b>	<b>114</b>

A number of systemic risk factors were found to be associated with BRVO (**Figure 5**). The most strong relationship of BRVO was with systemic

hypertension. 75 (65.8 %) patients were hypertensive while 39 (34.2 %) were non-hypertensive (Table 2)

**Figure 4 : Pie-chart showing gender distribution of branch retinal vein occlusion patients**



Hyperhomocysteinemia was found in 32 (28.1 %, n=114) patients. Diabetes mellitus was present in 26 (22.8 %) and dyslipidemia in 20 (17.5 %) patients. Tobacco addiction also had a relationship with BRVO. 18 (15.8 %) patients were current smokers or former smokers whereas 20 (17.5 %) had a dependence on tobacco in various forms. Arteriosclerosis was seen in 8 (7 %) patients and inflammatory cause was found in 4 (3.5 %) out of 114 patients of BRVO.

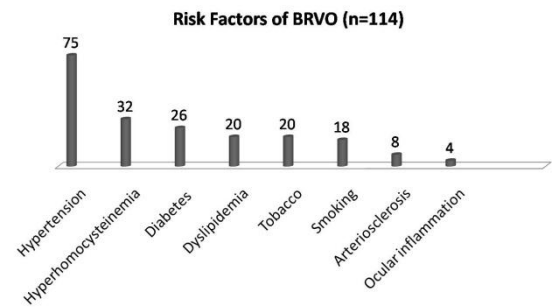
**Table 2: Systemic associations of Branch Retinal Vein Occlusion**

Systemic Risk Factors	Present n (%)	Absent n (%)
Hypertension	75 (65.8)	39 (34.2)
Hyperhomocysteinemia	32 (28.1)	82 (71.9)
Diabetes mellitus	26 (22.8)	88 (77.2)
Dyslipidemia	20 (17.5)	94 (82.5)
Tobacco	20 (17.5)	94 (82.5)
Smoking	18 (15.8)	96 (84.2)
Arteriosclerosis	8 (7.0)	106 (93.0)
Ocular inflammation	4 (3.5)	110 (96.5)

**Discussion:** Branch retinal vein occlusion is the second most common retinal vascular condition that causes diminution of vision. The visual loss occurs due to macular edema, hemorrhage or capillary non-perfusion.<sup>13</sup>The patients sometime may have only a sectorial visual field loss or remain

symptom-free in the event of sparing of macula by the occlusion.

**Figure 5 : Histogram showing systemic risk factors of branch retinal vein occlusion**



BRVO is a disease of older population.<sup>1,10,14</sup>BRVO occurs due to a combination of hemodynamic changes (venous stasis), degenerative changes in the blood vessel wall and blood hypercoagulability.<sup>15</sup> However, the age-related stiffening of the overlying arterial wall that causes venous compression in the common adventitial sheath is the most probable mechanism for development of BRVO.<sup>16</sup> The degenerative changes in endothelium and hypertrophy of intima media, as they follow venous compression from the artery, are the initial events in the pathogenesis of BRVO. They are followed by thrombus formation.<sup>17</sup> The superotemporal branch retinal vein is more frequently involved than the inferotemporal.<sup>18</sup>

The most common risk factor for BRVO is advancing age and metabolic syndrome (hypertension, diabetes mellitus and hyperlipidemia).<sup>19</sup> Rogers et al found that BRVO was most prevalent in sixth decade of life, and the prevalence of the disease was seven times more in patients older than 80 years than those who were in their forties.<sup>14</sup>

Cheunget al found no sex predilection in patients of BRVO.<sup>7</sup> However, others reported a male preponderance in cases of retinal vein occlusion.<sup>1,10,20</sup>In a study from Korea the authors noted higher number of female patients in BRVO group.<sup>9</sup> Fiebai and Nwosu also found a higher female to male ratio in their studies in Nigerian

population.<sup>21,22</sup> It was hypothesized that the higher health consciousness in female population and the use of oral contraceptive pills by females were responsible for it.

Hypertension, diabetes mellitus, hyperlipidemia and hematological disorders are systemic conditions with which BRVO is usually associated.<sup>21-23</sup> Hypertension was reported to be the strongest risk factor.<sup>23-25</sup> It was followed by hyperlipidemia and diabetes mellitus. The risk factors (hypertension, hyperlipidemia and high body mass index) for BRVO were found to be the same in patients younger than 50 years and those above fifty.<sup>25</sup>

Diastolic blood pressure is closely associated with retinal vein occlusion.<sup>12</sup> Retinal vein occlusion is more seen with elevated diastolic blood pressure than with elevated systolic blood pressure. Mere presence of hypertension or well-controlled hypertension is not a risk factor for vein occlusion but uncontrolled hypertension has a definite risk. Systemic hypertension, diabetes mellitus, atherosclerosis and smoking are more common in patients with retinal vein occlusion.<sup>4,5</sup> These conditions exaggerate the arterial sclerosis resulting in compression of underlying vein. The compressed vessel causes turbulent blood flow in the vein leading to damage to endothelium and intima media and subsequent occlusion.<sup>26</sup>

Hypertension (75 out of 114 patients) was the commonest associated risk factor in the present study. It was followed by hyperhomocysteinemia, diabetes mellitus and dyslipidemia. Lee et al reported 48.2 % (n=354) prevalence of hypertension and 9.9 % of diabetes in Korean population suffering from BRVO.<sup>9</sup> O'Mahoney et al noticed diabetes mellitus to be weakly associated with retinal vein occlusion.<sup>24</sup> They also reported hyperlipidemia to be twice as common in retinal vein occlusion cases compared to controls. There is a close relation between systemic arteriosclerosis and BRVO which leads to blockage at the site of arteriovenous crossing.<sup>27</sup> Eight out (7 %) of 114 patients of BRVO had arteriosclerotic changes visible in their retinal vessels on funduscopy in the current study. All these patients

were elderly (> 50 years old) and did not have other associated risk factors.

Hyperhomocysteinemia has an adverse effect on the vascular endothelium and may cause increased platelet aggregation and thrombosis.<sup>28</sup> Increased level of homocysteine is considered as an independent risk factor for retinal vein occlusion. Dietary habits especially vegetarian diet, certain therapeutic agents and enzymatic mutations affecting homocysteine metabolism may increase the level of plasma homocysteine.<sup>29</sup> Low plasma vitamin B12 level was found to be related to increased level of homocysteine.<sup>30</sup> Oral hypoglycemic agent (metformin), anti-hypertensive drug (thiazide), lipid lowering agent (fibrates) and methotrexate intake lead to hyperhomocysteinemia.<sup>31</sup> Genetic mutation in the enzyme methylenetetrahydrofolate reductase (MTHFR), whose impaired activity leads to hyperhomocysteinemia, was found to be higher in patients with retinal vein occlusion as compared to incidence of MTHFR mutation in general population.<sup>32</sup> However, Cahill et al reported no association between hyperhomocysteinemia and MTHFR mutation, although they found direct relationship of increased blood level of homocysteine to retinal vein occlusion.<sup>33</sup>

Systemic inflammatory conditions like vasculitis (tuberculosis and sarcoidosis) and Behcet disease increase the risk of retinal vein occlusion.<sup>4</sup> Systemic vasculitis generally causes retinal vein occlusion in relatively younger patients.

In the group of 354 patients of BRVO, Lee et al observed 28% patients to be either current or former smokers.<sup>9</sup> 20 out of 114 patients of BRVO were addicted to tobacco in various forms (chewing, snuffs, chewing gums and tooth paste) in the present study. Additional 18 patients were smokers. Tobacco abuse in any form exaggerates arteriosclerotic changes and stiffening of the vessel wall ultimately predisposing to BRVO. These patients had one or another systemic risk factors for BRVO along with tobacco addiction and/or history of smoking. To the best of our knowledge, no previous study has reported addiction to tobacco as a risk factor for BRVO.

The management of BRVO requires a multidisciplinary approach. The systemic risk factors must be addressed to before starting the specific therapy for the condition. Patient must be counselled to change the lifestyle and quit smoking and tobacco addiction. Collaboration between the ophthalmologist, physician, endocrinologist and cardiologist is needed to manage this multifactorial sight threatening condition.

## References

1. Cugati S, Wang JJ, Rochtchina E, et al. Ten-year incidence of retinal vein occlusion in an older population: the Blue Mountains Eye Study. *Arch Ophthalmol* 2006;124:726–732.
2. Klein R, Moss SE, Meuer SM, Klein BE. The 15-year cumulative incidence of retinal vein occlusion: the Beaver Dam Eye Study. *Arch Ophthalmol* 2008;126:513–518.
3. Karia N. Retinal vein occlusion: pathophysiology and treatment options. *Clin Ophthalmol* 2010; 4: 809-816.
4. Klein R, Klein BE, Moss SE, Meuer SM. The epidemiology of retinal vein occlusion: the Beaver Dam Eye Study. *Trans Am Ophthalmol Soc* 2000; 98: 133-141.
5. Mitchell P, Smith W, Chang A. Prevalence and associations of retinal vein occlusion in Australia: the Blue Mountains Eye Study. *Arch Ophthalmol* 1996; 114: 1243-1247.
6. Wong TY, Larsen EK, Klein R, Mitchell P, Couper DJ, Klein BE, et al. Cardiovascular risk factors for retinal vein occlusion and arteriolar emboli: the atherosclerosis risk in communities & cardiovascular health studies. *Ophthalmology* 2005; 112: 540-547.
7. Cheung N, Klein R, Wang JJ, Cotch MF, Islam AF, Klein BE, et al. Traditional and novel cardiovascular risk factors for retinal vein occlusion: the multiethnic study of atherosclerosis. *Invest Ophthalmol Vis Sci* 2008; 49: 4297-4302.
8. Jonas JB, Nangia V, Khare A, Sinha A, Lambat S. Prevalence and associations of retinal vein occlusions: the CentralIndiaEye and MedicalStudy. *Retina*. 2013; 33:152-159.
9. Lee JY, Yoon YH, Kim HK, Yoon HS, Kang SW, Kim JG, et al. Baseline characteristics and risk factors of retinal vein occlusion: a study by the Korean RVO Study Group. *J Korean Med Sci* 2013;28:136-144.
10. Lim LL, Cheung N, Wang JJ, Islam FM, Mitchell P, Saw SM, et al. Prevalence and risk factors of retinal vein occlusion in an Asian population. *Br J Ophthalmol* 2008; 92: 1316-1319.
11. Liu W, Xu L, Jonas JB. Vein occlusion in Chinese subjects. *Ophthalmology* 2007; 114: 1795-1796.
12. Arakawa S, Yasuda M, Nagata M, Ninomiya T, Hirakawa Y, Doi Y, et al. Nine-year incidence and risk factors for retinal vein occlusion in a general Japanese population: the Hisayama Study. *Invest Ophthalmol Vis Sci* 2011; 52: 5905-5909.
13. Barbazetto IA, Schmidt-Erfurth UM. Quantification of functional retinal damage in branch retinal vein thromboses. *Ophthalmologie* 1999;96:159–65.
14. Rogers S, McIntosh RL, Cheung N, Lim L, Wang JJ, Mitchell P, et al. The prevalence of retinal vein occlusion: Pooled data from population studies from the United States, Europe, Asia, and Australia. *Ophthalmology* 2010;117:313-391.
15. Zhou JQ, Xu L, Wang S, Wang YX, You QS, Tu Y, et al. The 10-year incidence and risk factors of retinal vein occlusion: the Beijing eye study. *Ophthalmology* 2013;120:803-808.
16. Rehak J, Rehak M. Branch retinal vein occlusion: pathogenesis, visual prognosis, and treatment modalities. *Curr Eye Res* 2008;33:111-131.
17. Frangieh GT, Green WR, Barraquer-Somers E, Finkelstein D. Histopathologic study of branch retinal vein occlusion. *Arch Ophthalmol* 1982;100:1132-1140.
18. Lang GE, Freissler K. Clinical and fluorescein angiography findings in patients with retinal vein occlusion. A unicenter study of 211 patients. *Klin Monatsbl Augenheilkd*. 1992; 201: 234-239.
19. Kolar P. Risk factors for central and branch retinal vein occlusion: a meta-analysis of published clinical data. *J Ophthalmol* 2014. doi: 10.1155/2014/724780. Epub 2014 Jun 9.
20. Hayreh SS, Zimmerman B, Podhajsky P. Incidence of various types of retinal vein occlusion and their recurrence and

- demographic characteristics. *Am J Ophthalmol* 1990;117:429-441.
21. Fiebai B, Ejimadu CS, Komolafe RD. Incidence and risk factors for retinal vein occlusion at the University of Port Harcourt Teaching Hospital, Port Harcourt, Nigeria. *Niger J Clin Pract* 2014;17:462-466.
  22. Nwosu SN. Pattern and risk factors for retinal vein occlusion in Onitsha, Nigeria. *Nig J Ophthamol* 2008;16:30-32.
  23. Sperduto RD, Hiller R, Chew E, Seigel D, Blair N, Burton TC, et al. Risk factors for hemiretinal vein occlusion: comparison with risk factors for central and branch retinal vein occlusion: the eye disease case-control study. *Ophthalmology* 1998;105:765-771.
  24. O'Mahoney PR, Wong DT, Ray JG. Retinal vein occlusion and traditional risk factors for atherosclerosis. *Arch Ophthalmol* 2008;12:692-699.
  25. Lam HD, Lahey JM, Kearney JJ, Ng RR, Lehmer JM, Tanaka SC. Young patients with branch retinal vein occlusion: a review of 60 cases. *Retina* 2010; 30:1520-1523.
  26. Christoffersen NL, Larsen M. Pathophysiology and hemodynamic of branch retinal vein occlusion. *Ophthalmology* 1999;106:2054-2062.
  27. Staurenghi G, Lonati C, Aschero M, Orzalesi N. Arteriovenous crossing as a risk factor in branch retinal vein occlusion. *Am J Ophthalmol* 1994;117:211-213.
  28. Clarke R, Daly L, Robinson K, Naughten E, Cahalane S, Fowler B, et al. Hyperhomocysteinemia: An independent risk factor for vascular disease. *N Engl J Med* 1991;324:1149-1155.
  29. Welch GN, Loscalzo J. Homocysteine and atherothrombosis. *N Engl J Med* 1998;338:1142-1150.
  30. Kalita J, Mishra UK, Srivastava AK, Bindu IS. A study of homocysteine level in North Indian subjects with special reference to their dietary habit. *The European e-Journal of Clinical Nutrition and Metabolism* 2007; 2:116-119.
  31. Dierkes J, Luley C, Westphal S. Effect of lipid-lowering and anti-hypertensive drugs on plasma homocysteine levels. *Vasc Health Risk Manag* 2007; 3:99-108.
  32. Loewenstein A, Goldstein M, Winder A, Lazar M, Eldor A. Retinal vein occlusion associated with methylenetetrahydrofolate reductase mutation. *Ophthalmology* 1999;106: 1817-1820.
  33. Cahill MT, Stinnett SS, Fekrat S. Meta-analysis of plasma homocysteine, serum folate, serum vitamin B12, and thermolabile MTHFR genotype as risk factors for retinal vascular occlusive disease. *AmJ Ophthalmol* 2003;136:1136-1150.

Conflict of interest: None
Funding: None
Cite this Article as: Nema N, Verma A, Patel S, Singhai P, Malviya R. Systemic associations of Branch retinal vein occlusion. <i>Natl J Integr Res Med</i> 2015; 6 (2):31-36