

## Variations of Mastoid Foramen in North Indian Population

Soubhik Debbarma\*, Alok Kumar Singh\*, Preeti Agarwal\*, Nishtha Singh\*\*, Aruna Sinha\*

\*Department of Anatomy, Rohilkhand Medical College & Hospitals, Bareilly, Uttar Pradesh, India, \*\* Department of Anatomy M. L. N. Medical College, Allahabad, Uttar Pradesh, India

**Abstracts: Background:** Non metric cranial variants have always been a topic of considerable interest for research workers, as they possess racial, regional and sex dimorphic differences. These variants are also of anthropometric, genetic, morphological and forensic importance. **Material and Methods:** 71 skulls from north indian region were studied to analyse the prevalence of variations in number and location of mastoid foramen and to draw significant inferences. **Results:** Prevalence of absent mastoid foramen is 5.19%, while bilateral prevalence of absent mastoid foramen is only 1.29%, however unilaterally mastoid foramen is absent in 3.9%. Prevalence of single, double, triple and quadruple mastoid foramina was 75.97%, 19.48%, 1.95% and 2.6% respectively. Amongst all mastoid foramina in 71 skulls, 23.38% foramina were exsutural, out of which 20.13% were present on temporal bone and 3.25% were present on occipital bone. **Conclusions:** Findings are discussed and compared with other global studies and are found to be of considerable racial and regional significance. Knowledge of this variant can be valuable in some neurosurgical procedures. [Debbarma S NJIRM 2014; 5(6):49-52]

**Key Words:** absent mastoid foramen, exsutural mastoid foramen, sutural mastoid foramen

**Author for correspondence:** Soubhik Debbarma Department of Anatomy Rohilkhand Medical College & Hospitals, Bareilly, Uttar Pradesh, India 243006 **Mo:** 9997194783 **Email:** soubhikdebbarma@yahoo.in

**Introduction:** Mastoid foramen is a large foramen in posterior border of temporal bone. It transmits an emissary vein from sigmoid sinus and also a small dural branch of occipital artery.<sup>1</sup> It is said to be present on the suture between mastoid part of temporal bone and the occipital bone.<sup>2</sup> Number and location of mastoid foramen often show variability. This foramen may not be present always or at some instances, there are multiple mastoid foramina present. Less frequently, this foramen lies exsuturally piercing the mastoid part of temporal bone or more rarely, the occipital bone.<sup>2</sup> Present study was undertaken to analyse the prevalence of variations in number and location of mastoid foramen and to draw significant inferences.

**Material and Methods:** The present study was conducted in the Department of Anatomy of Rohilkhand Medical College, Bareilly in collaboration with Department of Anatomy of M L N Medical College, Allahabad. For this study, a total number of 71 dried adult north indian human crania were observed. Out of which 39 human crania were taken from museum of Anatomy and Forensic Medicine department of Rohilkhand Medical College & Hospital, Bareilly and 32 human crania from Anatomy department of M. L. N. Medical College, Allahabad.

Each crania was inspected on both side for the presence or absence of mastoid foramen. In case of presence of foramen, exact number of foramen was also noted on both sides.

Though many small foramina are also seen in this region, foramen/ foramina <1 mm diameter were not taken into consideration. Care was exercised to differentiate mastoid foramen from mastoid canal as opening of mastoid canal might be confused as mastoid foramen.<sup>3</sup>

Information regarding location of each foramen was noted, whether it was sutural or exsutural. In case of an exsutural foramen, it was also noted whether it lied on temporal bone or occipital bone.

All the findings were compiled and tabulated followed by calculation of prevalence of foramen according to their number, location and laterality. Findings were also compared to available data from other ethnics.

**Results:**

**Table 1: Variation in the Number of Mastoid Foramen**

Number of mastoid foramen	Number of skull showing Bilateral mastoid foramen	Number of skull showing unilateral mastoid foramen		
		Right Sided	Left Sided	Total
0	1	3	3	6
1	54	5	4	9
2	5	2	3	5
3	0	0	1	1
≥4	0	1	0	1
Total number of skull= 71				
Total number of mastoid foramen= 154 (77 on right side and 77 on left side)				

**Table 2: Variation in the Location of Mastoid Foramen in 71 Crania**

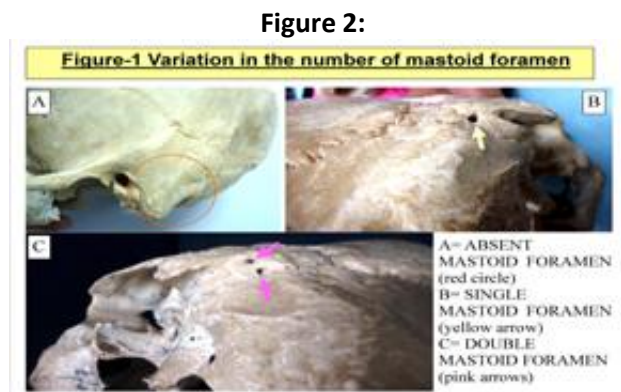
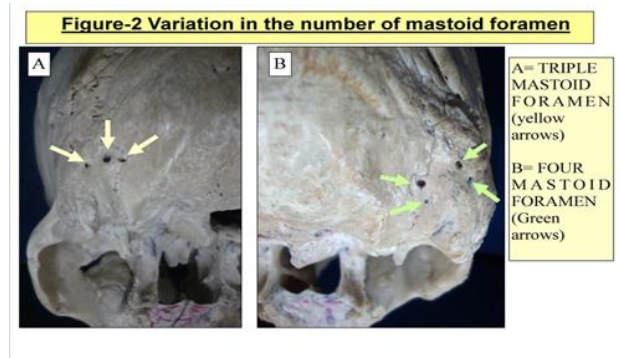
Location of mastoid foramen		Right	Left	Total
Sutural mastoid foramen		59	59	118
Exsutural mastoid foramen	Total exsutural	18	18	36
	Temporal	15	16	31
	Occipital	3	2	5

**Discussion:** Out of 71 human crania (142 sides), mastoid foramen was absent only in 8 sides (1 bilateral, 3 on left side and 3 on right side) (Figure-1A) (Table-1). Thus over all prevalence of absent mastoid foramen is 5.19%, while bilateral prevalence of absent mastoid foramen is only 1.29%, however unilaterally mastoid foramen is absent in 3.9%. (1.95% on right side and 1.95% on left side). It is less than the prevalence noted by Berry et al (1967)<sup>2</sup> in South American population (7.5%), Burmese population (7.8%), Egyptian population (12.5%), Nigerian population (15.3%), Punjabi Indian population (17.9%) and in modern Paletine population (19.4%). Kaur et al (2012)<sup>4</sup> found absence of mastoid foramen in 28% crania in their study in north Indian population. The prevalence of absent mastoid foramen was also found higher in the study of Kim et al (2000)<sup>5</sup> in

Korean population (11.94%) and in Turkish anatolian population (21.5%) studied by Turgut et al (1998)<sup>6</sup>.

Out of 71 human crania (142 sides), single mastoid foramen was present only in 117 sides (54 bilateral, 4 on left side and 5 on right side) (Table-1). Prevalence of single mastoid foramen is 75.97%, out of this it is bilateral in 70.13 %, however unilaterally it is present in 5.84 %. (3.25% on right side and 2.6% on left side) (Figure-1B).

Out of 71 human crania (142 sides), double mastoid foramen was present only in 15 sides (5 bilateral, 3 on left side and 2 on right side) (Table-1). Prevalence of double mastoid foramen is 19.48 %, out of this it is bilateral in 12.99%, however unilaterally it is present in 6.5 %. (2.6% on right side and 3.9 % on left side) (Figure-1C)

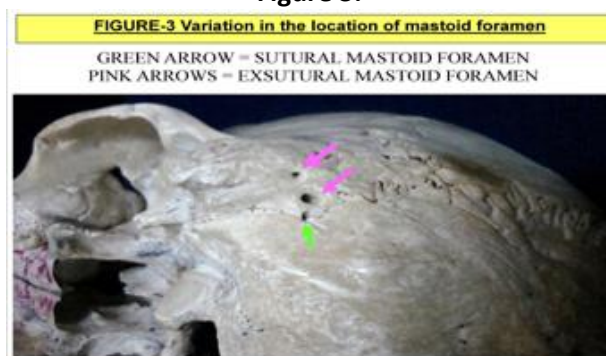


Out of 71 human crania (142 sides), triple mastoid foramen was present only in 1 crania in its left side. (Table-1). Prevalence of triple mastoid foramen is 1.95%, out of this it is bilateral in 0%, however unilaterally it is present in 1.95%. (0% on right side and 1.95% on left side) (Figure-2A)

Out of 71 human crania (142 sides),  $\geq 4$  mastoid foramen was present only in 1 crania in its right side. (Table-1). Prevalence of  $\geq 4$  mastoid foramen is 2.6%, out of this it is bilateral in 0%, however unilaterally it is present in 2.6%. (2.6% on right side and 0% on left side) (Figure-2B)

Amongst all mastoid foramina in 71 skulls, 23.38% foramina were exsutural, out of which 20.13% were present on temporal bone and 3.25% were present on occipital bone (Figure-3). Exsutural mastoid foramen on temporal bone were more frequent on left, while exsutural mastoid foramen on occipital bone were commoner on left side, though these differences were not found to be statistically significant. (Table-2)

**Figure 3:**



Berry et al (1967)<sup>2</sup> found frequency of exsutural mastoid foramen 38.3% in Egyptians, 36.9% in Nigerians, 33.3% in modern Palestine, 46.3% in Punjabi Indians, 46% in Burmese, 42% in north Americans and 39.6% in south Americans.

Kaur et al (2012)<sup>4</sup> found in their study on 100 north Indian skull that 58% mastoid foramen were exsutural. Kim et al (2000)<sup>5</sup> found that 64.0% of mastoid foramina located on the temporal bone, 28.5% were on the occipitomastoid suture, 5.2% were on the occipital bone and 1.9% foramina were on parietomastoid suture.

Both sutural and exsutural mastoid foramen showed equal frequency on either side, though results were not found statistically significant. (Table-2) Kaur et al (2012)<sup>4</sup> documented the higher frequency of exsutural mastoid foramen on left side.

Mastoid emissary vein courses through mastoid foramen, connecting the sigmoid sinus to posterior auricular and occipital veins<sup>7</sup>. Under normal circumstances, the blood that runs through this vein is slow. However, in cases of intracranial venous hypertension, the mastoid emissary vein can become a resource for blood drainage<sup>8</sup>.

**Conclusion:** Hence the current study provides valuable information regarding mastoid foramen from north indian region and compares the same with the data of different global regions. Of course, these variations would have great clinical significances during the neurosurgical and otolaryngeal surgery.

These data would also contribute to study epigenetic study of minor variations of skull and anthropological study.

#### References:

1. Williams PL, Bannister LH, Berry MM, Collins P, Dyson M, Dussek JE, Ferguson MWJ. Gray's Anatomy, 38th ed. : Churchill Livingstone. 1995: 58
2. Berry AC, Berry RJ. Epigenetic variation in human cranium. *J Anat.* 1967; 101: 361-380
3. Shaik HS, Shepur MP, Desai SD, Thomas ST, Maavishettar GF, Haseena S. Study of mastoid canals and grooves in south indian skulls. *Indian Journal of Medicine and Healthcare.* 2012; 1(1) :32-33
4. Kaur J, Choudhry R, Raheja, S, Dhissa NC. Non metric traits of the skull and their role in anthropological studies. *J. Morphol. Sci.* 2012; 29(4): 189-194
5. Kim WS, Kim SI, Kim S, Zheng GD, Yang EJ, Han SR. "Mastoid Foramen and Superficial Mastoid Canals of Korean Men. *Korean J Phys Anthropol.* 2000 Mar;13(1):11-19
6. Turgut HB, Anil A, Peker T, Pelin C, Sevim A The incidence and localization of mastoid foramen and superficial parietomastoid canal and their relations with each other. *Anatomical Science International* 1998; 73(3): 223-231
7. El Kettani C, Badaoui R, Fikri M, Jeanjean P, Montpellier D, Tchaoussov J. Pulmonary edema after venous air embolism during craniotomy. *Eur. J. Anaesthesiol.* 2002; 19:846-848

8. Reis C, Deshmukh V, Zabramski JM, Crusius M, Desmuskh P, Spetzler RE, Preul MC. Anatomy of the mastoid emissary vein and venous system of the posterior neck region: neurosurgical implications. *Neurosurg.*2007; 61:193-201

Conflict of interest: None
Funding: None