

## Idiopathic Granulomatous Mastitis-A Case Report

Dr. Madhuri S. Kate, Dr. Pruthviraj D. Jaybhaye, Dr. Ramesh J. Awari

Dept Of Pathology, Esi-Pgimsr & Model Hospital, Andheri (E), Mumbai-93, India

**Abstracts:** Idiopathic granulomatous mastitis (IGM) is an uncommon and curious condition of unknown etiology. However, its association with the use of oral contraceptive pills, autoimmune disorders, hyperprolactinaemia and *Corynebacterium* species has been proposed. It occurs in young parous women and presents as a firm tender lump that may be mistaken for carcinoma. Histopathologically proven IGM initially show breast masses which were suspected of having breast carcinoma. So, detailed histopathological examination of the cases which are suspected as carcinoma is mandatory. We present a case of painless breast lump with radiological suspicion of malignancy and diagnosed as Idiopathic Granulomatous mastitis without any underlying cause. Correct diagnosis requires the exclusion of infectious etiologies, other causes of granulomatous mastitis and malignancy combined with definitive histopathological confirmation. [Kate M NJIRM 2014; 5(4):108-111]

**Key Words:** Idiopathic Granulomatous Mastitis (IGM ), Granuloma, Carcinoma, Langhan's giant cells .

**Author for correspondence:** Dr. Madhuri S. Kate. Professor & Head, Department of Pathology, ESI-PGIMSR & Model Hospital, Andheri ( E ). Mumbai-93. Email: madhurikate65@gmail.com

**Introduction:** Idiopathic granulomatous mastitis, first described by Kessler and Wolloch in 1972, is a rare benign inflammatory disease of the breast in young women. Clinically and histologically, it is a mimicker of acute infection or carcinoma of the breast. Its etiology is unknown, and autoimmunopathogenesis has been advocated. Histologically, the disease is characterized by the occurrence of numerous granulomatous lesions with multinucleated cells of the Langhans type and focal central necrosis<sup>1</sup>. All specific infectious, granulomatous and neoplastic diseases must be excluded for a correct therapeutical approach<sup>2</sup>. Idiopathic granulomatous mastitis (IGM) characterized by non-caseating granuloma and microabscesses limited to breast lobules. The disease is presented mostly by multiple and recurrent breast abscesses or a firm mass that is clinically and radiologically not distinguished from breast cancer<sup>3</sup>.

**Case Details:** A 41 year old female presented with a painless lump in right breast since 2 months duration. There was no history of trauma or breast feeding. Clinically, lump measured 2X1 cm, was mobile, firm, non-tender and located in the retroareolar region. Overlying skin showed 'peau-de-orange' appearance. The lump was not fixed to underlying chest wall or muscle. Contralateral breast and axillary lymph nodes were unremarkable.

**Radiology:** USG of the right breast showed a solid cystic lesion of 2 x 2 cm in the retro-areolar region. Dilated ducts were seen with echogenic material and the lesion was labeled as ACR- BIRADS Category 4. Further, CT scan revealed asymmetrically enlarged breast with 1.7x 1.2 cm well defined focal lesion with soft tissue, fat and eccentric dense calcific foci within it, likely to represent benign etiology.

**FNAC:** Fine needle aspiration yielded creamish aspirate. Alcohol fixed smears were stained with Papanicolaou stain and the air dried smears by Giemsa stain. Smears showed numerous non-caseating granulomas and multinucleate giant cells admixed with neutrophils and ductal epithelial cells. There was lobular distribution of mixed chronic inflammatory cells composed of lymphocytes, plasma cells, giant cells, the presence of neutrophil infiltration and lack of caseation. Occasional Langhan's types of giant cells were also noted. Stain for AFB was negative. Special stains like PAS and GMS were non contributory. Provisional diagnosis of granulomatous mastitis ?tuberculous infection was offered. Patient was given Anti Koch's treatment. However patient stopped the medicine of her own after 2 months with little improvement. Lumpectomy was performed and specimen sent for histopathological examination. Figure 1,2,3 Microphotograph showing numerous non-caseating granulomas and multinucleate giant cells and perilobular inflammation

Figure 1

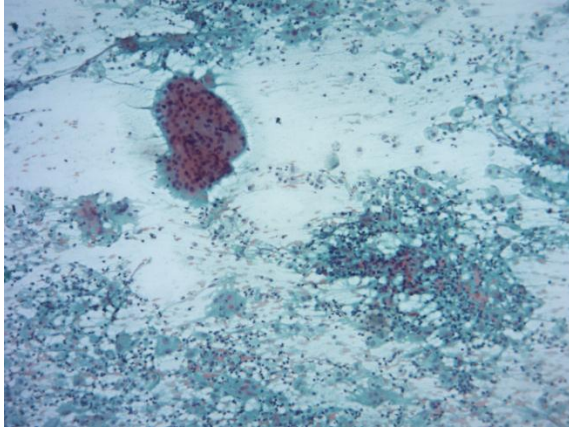


Figure 2

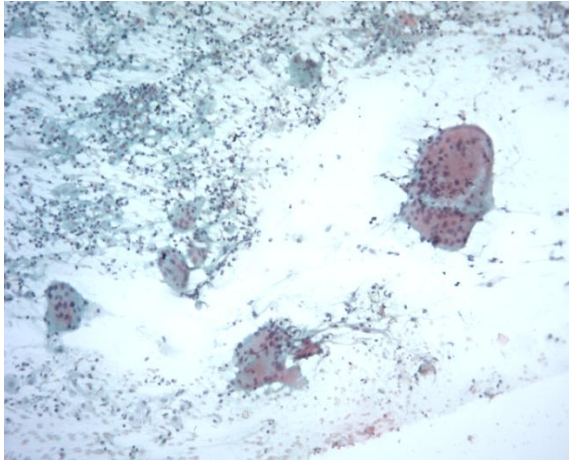
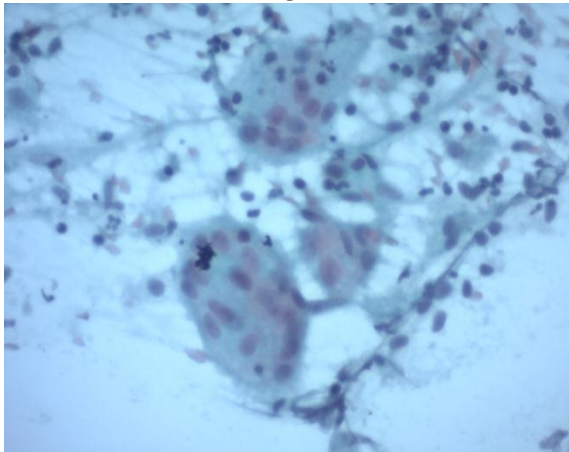


Figure 3



Histology showed multiple non-caseating granulomas with microabscess formation, which were confined to the breast lobules. A diagnosis of Idiopathic granulomatous mastitis was made.

Figure 4: Showing Multiple Granulomas Confined To Breast Lobules, Microabscess Formation

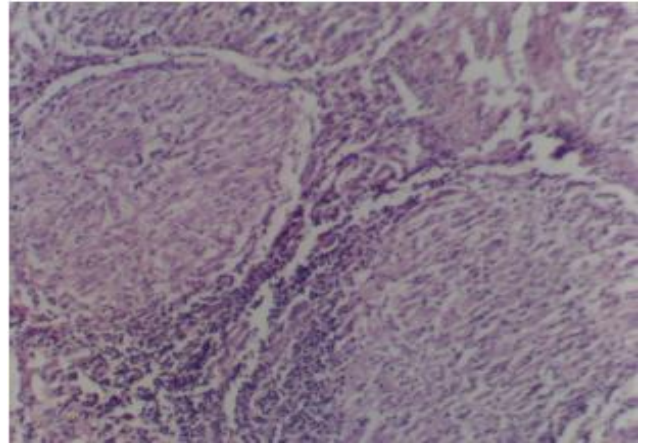
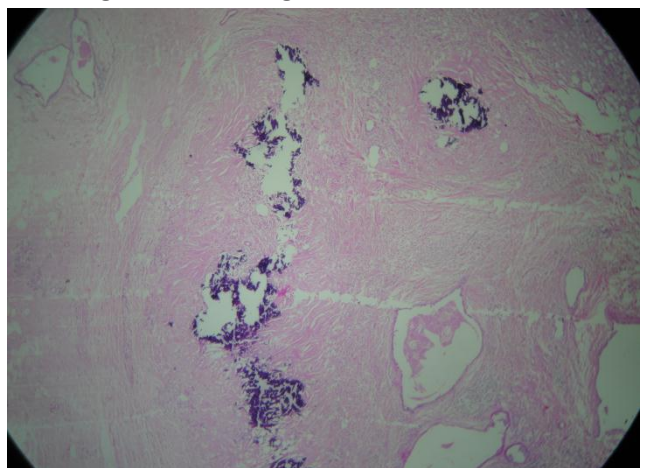


Figure 5: Showing areas of calcification



**Discussion:** Idiopathic granulomatous mastitis (IGM) was first described as a specific entity in 1972 by Kessler and Wolloch<sup>4</sup>. However, its association with the use of oral contraceptive pills, autoimmune disorders, hyperprolactinaemia and *Corynebacterium* spp has been proposed<sup>5,6,7,8,9</sup>. Studies show that women who are affected by IGM, belong to third decade of life<sup>5,6,10</sup>. All the cases described by Kessler and Wolloch [1972] and Fletcher 1982, occurred within 6 years of pregnancy. Studies show conflicting data associating the role of oral contraceptives in patients diagnose as IGM range from 0 to 33 %<sup>5, 11, 12</sup>. It occurs in young parous women and presents as a firm tender lump that may be mistaken for carcinoma<sup>4, 13</sup>. In a study, all cases with histopathologically proven IGM initially showed breast masses which were suspected of having breast carcinoma<sup>14</sup>. So, detailed histopathological examination of the cases which

are suspected as carcinoma is mandatory. Histopathologically, IGM may mimic tubercular mastitis showing well defined granuloma, caseous type secretions, epithelioid cells and langhans giant cells and can result in a misdiagnosis of tuberculosis. Treating tuberculosis with steroids would aggravate the infection, whereas unnecessary antitubercular drugs may cause numerous side effects. So, the differential diagnosis of tubercular mastitis needs to be considered<sup>15,16</sup>. The only diagnostic proof of tubercular mastitis is the demonstration of tubercle bacilli in amicroscopic smear or culture or by PCR formycobacterium tuberculosis. A case study by KB Sriram and D. Moffat highlight the difficulty in differentiating culture negative tuberculosis from granulomatous mastitis and the importance of a high index of clinical suspicion<sup>17</sup>. The presence of caseousnecrosis, langhans giant cells and granuloma favour the diagnosis of TB mastitis, whereas IGM represents a lobular distribution of mixed chronic inflammatory processes which are composed of lymphocytes, plasma cells, giant cells, the presence of neutrophilinfiltationand lack of caseation. Additionally, micro abscess formation and squamous metaplasia of the lobular and ductularepithelium may occur.Farhan Abbas and Anwal in their study, found that fat necrosis was the most predominant feature. Fat damage was the main cause of the formation of granuloma and giant cells which were surrounded by lymphocytes, plasma cells and neutrophils<sup>19</sup>. Because the IGM is essentially a diagnosis of exclusion, other differential diagnoses are rare specific causes of granulomatous inflammation, including fungal infections or non infectious causes, sarcoidosis, Wegner's granuloma, granulomatous angiopanniculitis of the breast, fat necrosis, foreign body granuloma, plasma cell mastitis, cholesterol granuloma and milk granuloma. Combination of any of the above mentioned conditions is also a possibility, which must be taken into consideration<sup>15,16</sup>. In this case, the diagnosis was made on clinical, cytological and histological judgment. This case appears to be a distinct disease entity, as neither organisms nor foreign body materials have been identified. IGM may occur due to exogenous hormones (oral contraceptives) or endogenous hormones

(prolactins). Oral contraceptives induce hyperplasia in the lobular ductule, thus leading to the obstructive desquamation of the ductules, distention of the ductules and perilobular inflammatory reactions. Prolactins lead to postlactational granulomatous mastitis and this is associated with pregnancy. Fletcher et al. (1982) suggested that the finding of polymorphs in some of the ductularlumina might indicate a primary damage to the epithelium by some unknown agent, resulting in a leakage of contents and a subsequent granulomatous response in the surrounding stroma. In the recently reported cases, immunostaining showed that the lesions contained predominantly stromal T lymphocytes which favoured the possibility of a local immune response. This condition may respond to steroids and be associated with a high incidence of postoperative wound infections<sup>13</sup>. In this patient, the lesion resolved with steroid treatment. IGM can recur in up to 50% of the cases, usually within 6 weeks to 11 months after stopping treatment<sup>8</sup>. . In refractory cases or in those with persistent collection, immunosuppressants like methotrexate have been utilized along with surgical excision.

**Conclusion:** IGM is rare and benign inflammatory process which is commonly mistaken for malignancy and other disease entities which is why it is often treated incorrectly .Correct diagnosis requires the exclusion of infectious etiologies, other causes of granulomatous mastitis and malignancy combined with definitive histopathological confirmation. One must not accept granulomatous mastitis as tuberculosis, even in the area where tuberculosis is common, until and unless there is a clear history of tuberculosis with positive indicators and the involvement of other organs like the lymphnodes, in order to avoid the pitfall of prolonged treatment.

**Acknowledgement:** We are grateful to the Dean, Dr Meenakshi Mathur for her support and encouragement.

#### References

1. Dixon JM, Breast Infection. ABC of breast diseasesBMJ 1994;309-946.



2. Going JJ, Anderson TJ, Wilkinson S, Chetty U. Granulomatous lobular mastitis. *J Clin Pathol* 1987;40:535.
3. Farzaneh E., Arash N., Ali Kavyani, Amir H. Idiopathic granulomatous mastitis: report of 3 cases. *MJIRI*. Vol.23, No.4, February 2010. pp.233-237.
4. Kessler E, Wolloch Y: Granulomatous mastitis: A lesion clinically simulating Carcinoma. *Am J Clin Pathol* 1972;58(6):642-46. [2] Kessler EI, Katzav JA. Lobular granulomatous mastitis: *Surg Pathol* 1990;3:115-20.
5. Bani-Hani KE, Yaghan RJ, Matalka, Shatnawi NJ: Idiopathic granulomatous mastitis: time to avoid unnecessary mastectomies. *Breast J* 2004, 10:318-322.
6. Galea MH, Robertson JF, Ellis IO, Elston CW, Blamey RW: Granulomatous lobular mastitis. *Aust N Z J Surg* 1989, 59:547-550.
7. Newnham MS, Shirley SE, McDonald AH: Granulomatous lobular mastitis. A case report and review of the literature. *West Indian Med J* 2001, 50:236-238.
8. Diesing D, Axt-Flidner R, Hornung D, Weiss JM, Diedrich K, Friedrich M: Granulomatous mastitis. *Arch Gynecol Obstet* 2004, 269:233-36.
9. Taylor GB, Paviour SD, Musaad S, Jones WO, Holland DJ. A clinicopathological review of 34 cases of inflammatory breast disease showing an association between corynebacteria infection and granulomatous mastitis.
10. Erhan, VeralA Kara E, Ozdemir N, Kapkac M, Ozdedeli E, Yilmaz R, Koyuncu A, Ozbal O: A clinicopathologic study of a rare clinical entity mimicking breast carcinoma: idiopathic granulomatous mastitis *Breast* 2000, 9:52-56.
11. Imoto S, Kitaya T, Kodama T, Hasebe T, Mukai K: Idiopathic granulomatous mastitis: case report and review of the literature. *Salam IM, Alhoms MF, Daniel MF, Sim AJ: Diagnosis and treatment of granulomatous mastitis. Br J Surg* 1995, 82:214.
12. Lai EC, Chan WC, Ma TK, Tang AP, Poon CS, Leong HT: The role of conservative treatment in Idiopathic granulomatous mastitis *Breast J* 2005, 11: 454-56.
13. *Biopsy Pathology of the Breast*, 2nd ed.- by John P. Sloane, 2001. Arnold: p(280-282).
14. Tse GMK, Poon CSR, Ramachandram K, Ma TKF, Pang L-M, Law BKB, Chu WCW, Tang APY, Cheung HS. Granulomatous mastitis: a clinicopathological review of 26 cases. *Pathology*. 2004;36:254-57. doi: 10.1080/00313020410001692602. [PubMed].
15. *Fine Needle Aspiration Cytology* by Svante R. Orell et al. 4th ed. 2005, Elsevier Ltd.: p(179-180).
16. Cheung VCC, Yew WW, Yuen KY. Molecular diagnostic in tuberculosis. *Eur J Clin Microbiol Infect Dis*. 2005;24:711-720. doi: 10.1007/s10096-005-0039-1.
17. Faehan Abbas Baloch and Anwar ul Haque Idiopathic granulomatous mastitis. Spectrum of morphological feature and potential pitfalls in pathology.
18. Goldberg, Jay MD; Baute, Lisa MD; et al.: Granulomatous mastitis in pregnancy. *Obstetrics and Gynecology*, Nov 2000, vol.96, Issue 5, part-2: p(813-815).

Conflict of interest: None
----------------------------

Funding: None
---------------