

## Fusion Of Main Trunks Of Median And Musculocutaneous Nerves (An Anatomic Variation)

Dr. Navita Aggarwal\*, Mrs. Navjot Kaur\*, Dr. Jaswinder Kaur\*\*, and Dr. Monika Gupta\*

\*Assistant Professor, \*\*Associate Professor, Department of Anatomy, Adesh Institute of Medical Sciences and Research, Bathinda

**Abstract:** Median nerve (MN) and Musculocutaneous nerve (MCN) around their origin from brachial plexus are known to have many variations. A unilateral variation in the course of MCN in 65 years male cadaver was observed during routine dissections for medical undergraduates. In the present case, MCN was observed to be formed by its normal pattern, as the continuation of lateral cord of brachial plexus. Thereafter instead of piercing coracobrachialis, it fuses for some distance with MN and then separates out to supply all the muscles of anterior compartment of the arm. It then ends as lateral cutaneous nerve of forearm. Such a case of fusion of main trunks of MN and MCN has not been clearly reported in literature. Knowledge of this variation is important owing to its numerous clinical implications. [Aggarwal N et al NJIRM 2013; 4(3) : 154-158]

**Key Words:** Musculocutaneous nerve (MCN), Median nerve (MN), Fusion, Variation.

**Author for correspondence:** Dr. Navita Aggrawal, Assistant Professor, Department of Anatomy, Adesh Institute of Medical Sciences and Research, Bathinda. (Punjab). E mail: navita22a@gmail.com

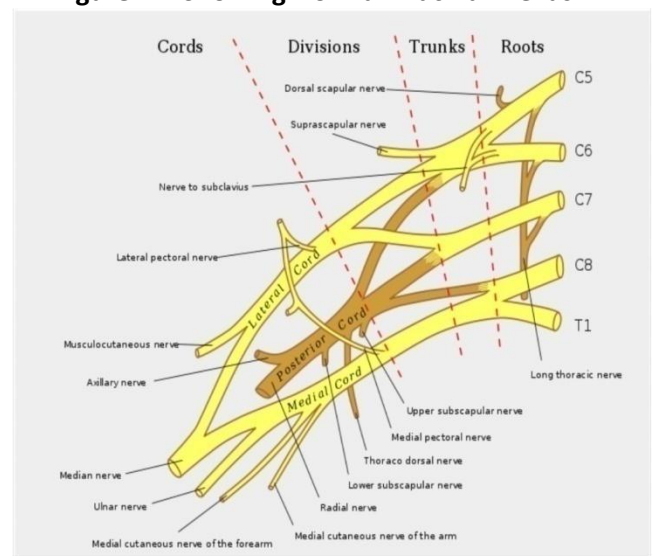
**Introduction:** In the arm, the MCN after arising from the lateral cord of brachial plexus pierces the coracobrachialis muscle and innervates the coracobrachialis itself, the biceps brachii and the brachialis muscles. It later continues as the lateral cutaneous nerve of the forearm without exhibiting any communication with the MN or other nerves.<sup>1</sup> Variations in the formation and branching of brachial plexus have been reported by several investigators and are more common in the terminal branches of brachial plexus.<sup>[2-5]</sup> The MN and MCN after their origin from the cords of brachial plexus, pass through the anterior compartment of the arm without receiving branches from any nerve in the neighborhood.<sup>[6,7]</sup> Although communications between the nerves in the arm are rare, the communications between the MN and MCN as variations were described from nineteenth century.<sup>8,9</sup> Variations of MCN, that it does not pierce coracobrachialis have also been reported.<sup>[10]</sup>

**Material And Methods :** A unilateral variation in the course of MCN was observed in the left arm of a 65 years male cadaver, during routine dissections for medical undergraduates in the Department of Anatomy, AIMSR, Bathinda. The area was dissected carefully and the variation from the normal pattern were noted and photographed. Length of the segment (trunk) where the two nerves remained fused before separating out was measured. The further course followed by the two nerves was carefully studied and the variations found are

discussed in relation to the already stated variations.

**Observations :** The present case report is about a variation in the left upper limb of a 65 year male cadaver. Brachial plexus formation was found to be normal till the branches arose from the cords. MN was formed by joining of two roots, one each from the medial and lateral cords of brachial plexus. The MCN was seen as a continuation of lateral cord of brachial plexus.

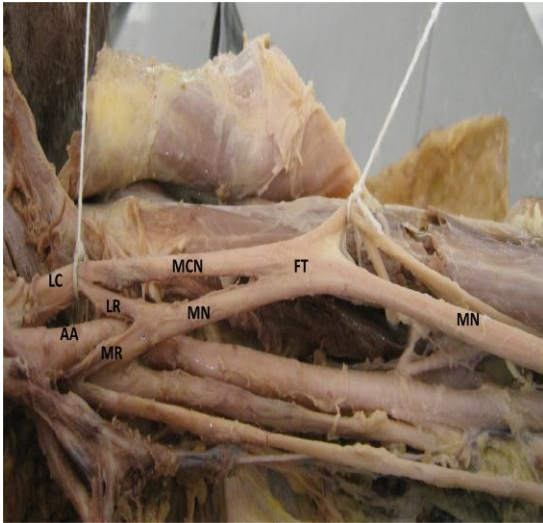
**Figure - 1. Showing Normal Brachial Plexus**



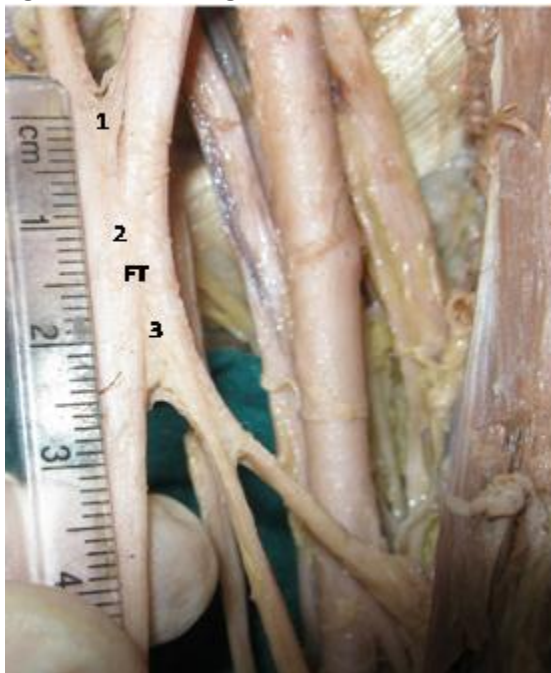The variation here is that, further down, instead of piercing the coracobrachialis, MCN runs along the lateral root of MN and then fuses (fig -2) with the main trunk of MN for a distance of about 2.52 cm (fig - 3). Attempts were made to separate out the two nerves but it was found that the nerve fibres

intermingled in the region where the two trunks fused. The whole fused trunk was enclosed in one connective tissue sheath. No branch was seen arising from this area of fusion of the two nerve trunks.

**Figure -2. Showing Formation And Fusion Of Main Trunks Of Median And Musculocutaneous Nerves**



**Figure – 3. Showing Fusion Of Mn And Mcn**



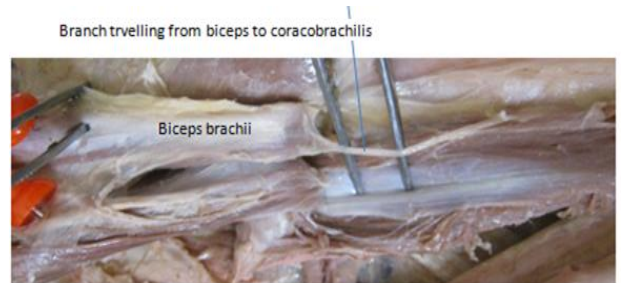
(1-Fibres Passing From Mcn To Mn, 2-Actual Trunks Fusing, 3- Fibres Passing From Ft To Mcn)

Subsequently, the MCN leaves the fusion trunk and gives off a branch which pierces the biceps brachii which then runs upwards and innervates the

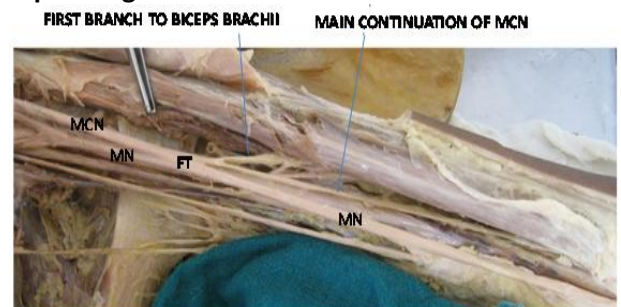
coracobrachialis muscle (fig -4). The continuation trunk of MCN then follows its normal course by supplying both heads of biceps brachii and brachialis muscle (fig -5). Thereafter it continues as lateral cutaneous nerve of forearm.

Hence in this cadaver it was observed that the MCN in the left arm does not pierce the coracobrachialis muscle which it normally does but fuses with MN for a certain distance and then separates out to innervate the structures it usually does.

**Figure – 4. Showing Branch Travelling From Biceps To Coracobrachialis.**



**Figure - 5. Showing Course Of Mcn After Separating From Fusion Trunk.**



(Lc- Lateral Cord, Aa- Axillary Artery, Ft- Fused Main Trunks, Mr- Medial Root Of Median Nerve, Lr- Lateral Root Of Median Nerve, Mn- Median Nerve, Mcn- Musculocutaneous Nerve.)

**Discussion:** MCN is a continuation of lateral cord of brachial plexus. The peculiarity of this nerve is that it pierces the coracobrachialis and then supplies the other two muscles of the anterior compartment of arm. The MN which is formed by two roots, one each from medial and lateral cords, passes through the arm to supply muscles of forearm and hand. The two nerves normally do not communicate with each other, but variations studied on these two nerves report different patterns of anastomosis between them.<sup>6</sup> Among

all the variations stated in the brachial plexus formation, the anastomosis is most commonly seen between the branches of MN and MCN and are in the form, that a branch from MN reaches the MCN or vice versa.

These have been classified into 5 types by Le minor as:

Type 1 - no communication between the MCN and MN

Type 2 - fibres of medial root of MN pass through the MCN and join the MN in the middle of arm

Type 3 - the fibres of lateral root of MN pass along the MCN and after some distance leave it to form the lateral root of MN

Type 4 - the MCN fibres join the lateral root of MN and after some distance the MCN arise from the MN

Type 5 - the MCN is absent and the entire fibres of MCN pass through the lateral root of MN and the fibres to the muscles supplied by MCN directly arise from the MN.<sup>11</sup>

Venieratos D et al have noted three types of communications between the MCN and MN in relation to the coracobrachialis muscle. In type I, communication between MCN and MN is proximal to the entrance of the MCN into the coracobrachialis, whereas in type II, the communication is distal to the muscle and in type III neither the nerve nor its communicating branch pierced the muscle.<sup>12</sup>

Four different patterns of communication given by Loukas et al are : Type I (54 communications, 45%) : the communications were proximal to the point of entry of the MCN into the coracobrachialis; type II (42 communications, 35%): the communications were distal to the point of entry of the MCN into the coracobrachialis; type III (11 communications, 9%): the MCN did not pierce the coracobrachialis; and Type IV (9 communications, 8%) : the communications were proximal to the point of entry of the MCN into the coracobrachialis and additional communication took place distally, out of 129 formalin-fixed cadavers.<sup>13</sup>The communications have been broadly classified by Choi D et al into, type I : the MCN and MN were

fused; in type II: there was one connecting branch between the MCN and MN and in type III: two connecting branches were present between the MCN and MN.<sup>14</sup>

So, the variation in the present case does not fall in any of the criteria's of Le minor, as it arises normally and separately from roots of MN and joins the main trunk of MN and not its roots. In Le minor's classification, there is no description about fusing of the main trunks of MN and MCN. The present variation can be said to be partly like that of third type described by Venieratos et al<sup>12</sup> and the third type of Loukas et al<sup>13</sup> which states that the MCN does not pierce coracobrachialis. Also the present case can be said to be type I of the categories mentioned by Choi et al.<sup>14</sup>

Therefore, it is suggested that with the finding of new types of communications and anatomical variations between MN and MCN, there may arise a need to modify the classification by various authors, which should be based not only on the communication between the MN and the MCN but also on the relationship of the MCN with the coracobrachialis muscle.

Embryonic Basis: The explanation for the origin of possibility of such anatomic variation can be given by understanding the embryonic development of brachial plexus. Communication between the MCN and MN is considered as a remnant from the phylogenetic point of view as both the nerves have a common origin during embryonic development. In the context that ontogeny replicates phylogeny; it is possible that the variation seen in the current study is the result of developmental anomaly. Alternatively, the variation could arise from circulatory factors at the time of fusion of the brachial plexus cords.<sup>1</sup>

Clinical Significance: Variations in MCN and MN are important to various fields of medical science. The orthopedic surgeons have to operate in these areas during fractures on surgical neck of humerus. Knowledge of this kind of variation can prevent injuries to these nerves in surgical interventions of the axilla and upper arm.

It can help neurophysicians to understand the weakness of specific pattern in relation to area of injury to nerve and also important for interpretation of results from nerve conduction studies. It is also important to physiotherapists in order to carry out electrotherapy and to radiologists as they should also be aware of variations in peripheral nerve for interpretation of radiographs of this area. Knowledge of such variations can be useful in nerve grafting and in neurophysiological evaluation for diagnosing peripheral neuropathies and in trauma surgeries.<sup>15</sup>

Such variations have clinical importance especially in post-traumatic evaluations and exploratory interventions of the arm for peripheral nerve repair and to some extent during flap dissections and regional nerve block.<sup>16</sup>

If the surgeon finds it necessary to isolate and trace the MN and MCN distally, it is essential to be alert to communications that may occur between them. The clinical relevance of such variations might be correlated to entrapment syndromes and to avoid an unnecessary carpal tunnel release<sup>12,17</sup>

Any manipulations in this region without the knowledge of existence of such variations may cause weakness of unknown pattern in the muscles supplied by MCN. Also the presence of this variation should be considered when the nerve conduction studies show the weakness of muscles of anterior compartment of arm, inspite of normal conduction at root formation level.

### References

1. Chouhan R and Roy TS. Communication between the median and musculocutaneous nerve-A case Report, J. Anat. Soc. India. 2002; 51 (1) : 72-75.
2. Kerr AT. The brachial plexus of nerves in man, the variations in its formation and branches. American Journal of Anatomy 1918; 23: 285-395.
3. Poynter CWM. Congenital anomalies of the arteries and veins of the human body with bibliography. University Studies.22nd ed. University of Nebraska; 1920.
4. Linell EA. The distribution of nerves in the upper limb, with reference to variabilities and their clinical significance. J Anat 1921; 55: 79-112.
5. Miller RA. Comparative studies upon the morphology and distribution of the brachial plexus. American Journal of Anatomy 1934; 54: 143-7.
6. Hollinshead WH. Functional anatomy of the limbs and back .4th Ed. WB Saunders: Philadelphia. 1976.
7. Williams PL, Bannister LH, Berry MM, Collins P, Dyson M, Dussek JE and Ferguson MWJ. Gray's Anatomy In: Nervous system. 38th Ed. Churchill Livingstone: Edinburgh. 1995.
8. Testut, Trait: d' Anatomies. 4th Ed. Vol 3.p76.1899.
9. Harris W. The true form of the brachial plexus. J Anat Physiol 1904; 38: 399-422.
10. Nakatani T, Mizukami S, Tanaka S. Three cases of musculocutaneous nerve not perforating coracobrachialis. Kaibogaku Zasshi 1997 ; 72(3): 191-4.
11. Le Minor JM .A rare variant of the median and musculocutaneous nerves in man. Arch Anat Histol Embryol 1992; 73: 33-42.
12. Venieratos D and Anagnostopoulou S. Classification of communications between the musculocutaneous and median nerves. Clin Anat 1998; 11: 327-31.
13. Loukas M and Aqueelah H. Musculocutaneous and median nerve connections within, proximal and distal to the coracobrachialis muscle. Folia Morphol 2005; 64: 101-8.
14. Choi D, Rodriguez- Niedenfuhr M, Vazquez T, Parkin I and Sanudo JR. Patterns of connections between the musculocutaneous and median nerves in the axilla and arm. Clin Anat 2002; 15: 11-17.
15. Sontakke YA, Fulzele RR, Tamgire DW, Joshi M, Gajbe U and Marathe RR. Unilateral variant origin of musculocutaneous nerve. International Journal of Anatomical variations 2010; 3: 59-80.
16. Shukla L, Soni G and Gaur N. Foyur communications between median and musculocutaneous nerves. International Journal of Anatomical variations 2010;3: 188-7.

17. Arora J, Kapur V, Suri RK and Khan RQ. Inter-Communications between median and musculocutaneous nerves with dual innervations of brachialis muscle-A case report. J Anat. Soc. India 2003; 52(1) : 66-8.

Conflict of interest: None
----------------------------

Funding: None
---------------