

A Study Of Various Clinical Pattern Of Cutaneous Manifestations In Endocrine Disorders

Dr. Dinesh Chaudhary*, Dr. Abhishek Bunker**, Dr. Bharti K Patel***, Dr. Neela V Bhuptani****

*Resident Doctor, **Senior Resident, ***Professor, ****Professor & Head, Department Of Dermatology, Venerology & Leprosy, PDU Government Medical College, Rajkot 360001.

Abstract: Background: The skin serves as a window for clinicians to understand, diagnose and monitor endocrine diseases. Endocrine disorders are known to involve all organ systems of the body, including the skin. These cutaneous symptoms can sometimes be the presenting symptoms or can even be pathognomonic of the underlying endocrine condition. Aims and objectives is to assess the various cutaneous manifestations of endocrine disorders and to help in early diagnosis of the underlying endocrine disorders so as to prevent morbidity. Material and Methods: A retrospective and cross-sectional study was carried out on 200 patients with endocrine disorders with mucocutaneous lesions who were receiving treatment at a tertiary care hospital. After receiving informed consent, a thorough history of the onset, progression, and triggering causes for the mucocutaneous lesions was recorded, along with the relevant laboratory tests. Results: Overall, most common age group affected was 31-40 years (31%). Female:male ratio was 1.7:1. Most common endocrine entity encountered in our study was diabetes mellitus(DM)(60%) followed by thyroid disorder (28%) and hyperandrogenism (11%). Most common dermatoses observed in DM were infections (51.4%) {fungal (28.6%), bacterial (17.8%), viral (5%)}. Among thyroid disorders 48 patients had hypothyroidism and 8 patients had hyperthyroidism. In hypothyroidism, commonest cutaneous manifestation was diffuse hair fall (70.8%). In hyperthyroidism, diffuse hair loss and pruritus were most common in (37.5%) patients each. Androgen excess in total 22 patients, in which 10 patients of acne vulgaris, 7 patients of hirsutism and 5 patients of PCOS. Conclusion: Cutaneous alterations might represent internal metabolic changes, therapeutic status or treatment-related side effects. Knowledge of the related skin lesions aids in the early detection of underlying endocrine abnormalities and hence timely treatment for the prevention of complications.[Chaudhary D Natl J Integr Res Med, 2023; 14(2):01-07, Published on Dated: 15/03/2023]

Key Words: Diabetes Mellitus, Thyroid, Androgen Excess

Author for correspondence: Dr. Dinesh Chaudhary, Department Of Dermatology, Venerology & Leprosy, PDU Government Medical College, Rajkot 360001. E-Mail: dineshchaudhary11177@gmail.com

Introduction: Many cutaneous diseases are associated with systemic manifestations and the skin can also be a mirror to many internal diseases. Cutaneous manifestations may provide important clues to the diagnosis of endocrine disorders¹. Diabetes mellitus is a very common medical condition that affects almost every organ system. Almost all patients with DM eventually develop skin manifestations due to the long-term effects of DM on the microcirculation and skin collagen. Thus skin manifestations may help in early detection and control of diabetes.

Infections may be a presenting feature of diabetes, particularly in type2 diabetes¹. Thyroid disease is also associated with a significant number of dermatologic disorders.

Thyroid hormones are known to regulate metabolic processes that are essential for normal growth and development¹. Hyperandrogenism in

women can be caused by various conditions, the most prevalent of which is polycystic ovary syndrome. Common dermatologic manifestations of hyperandrogenism include hirsutism, acne, acanthosis nigricans and androgenic alopecia.

Hirsutism reflects an increase in circulating androgens or an enhanced end-organ response to androgens¹.

The most common feature of cushing syndrome includes central adiposity involving the face, neck, trunk, and abdomen resulting in a typical cushingoid appearance.

The present study is undertaken to know the spectrum of dermatological manifestations in various endocrine disorders, which enables us to make an early diagnosis of the same. Recognition of systemic illness is important in order to ensure that appropriate treatment is provided at the

This is an Open Access article distributed under the terms of the Creative Commons Attribution 4.0 International License (<http://creativecommons.org/licenses/by/4.0/>), allowing third parties to copy and redistribute the material in any medium or format and to remix, transform, and build upon the material for any purpose, even commercially, provided the original work is properly cited and states its license.

earliest, thus preventing complications. This study was an attempt to ascertain the various clinical patterns of cutaneous manifestations in endocrine disorders.

Material and Methods: A retrospective and cross-sectional study was carried out on 200 patients with endocrine disorders with mucocutaneous lesions at P.D.U. Govt. Medical College and Hospital, Rajkot for 2 years from October 2019 to September 2021.

A detailed history was elicited and thorough clinical examination was done of every patient, which was recorded in a predesigned proforma.

Routine investigations like complete blood count, urine routine and microscopic examination, renal function test, liver function test, serum protein, serum glucose will be done in all patient and special investigation including FSH, LH, serum testosterone, TSH, T3, T4, serum HbA1c will be done in indicated cases.

Ethical approval was taken from institutional ethics committee.

Result: In the present study, 200 cases with endocrine disorders were examined for skin manifestations. Among the 200 patients, Maximum no of patients had diabetes (120), followed by thyroid disorders (56), Androgen excess (22) and 1 patient of cushing syndrome and hyperparathyroidism each (Table 1).

In our study, most common age group affected was 31-40 years(31%), followed by 41-50 years(19%)(FIGURE-1). There were 126 females and 74 males, with female: male ratio 1.7:1(FIGURE-2), suggestive of female preordance in overall prevalence of endocrine disorders.

Out of total 120 patients of DM, acute and gross metabolic conditions were most common (61.6%) followed by other manifestations frequently associated with DM(29.16%), chronic degenerative conditions(8.33%) and skin changes due to diabetic treatment(0.8%)(TABLE 2)

Table 1: Overall Pattern Of Endocrine Disorders (N=200)

Endocrine Disorders		Total No. Of Patients	% Of Total Patients
Diabetis Mellitus	Acute And Gross Metabolic	74	37.5
	Chronic Degenerative	10	5
	Other Manifestations Frequently Ssociated With DM	35	17.5
	Due To Diabetic Treatment	1	0.5
Thyroid Diseases	Hypothyroidism	48	24
	Hyperthyroidism	8	4
Parathyroid	Hyperparathyrodism	1	0.5
Adrenal Gland	Cushing Syndrome	1	0.5
Due To Androgen Excess	PCOS	5	2.5
	Hirsutism	7	3.5

Out of 74 patients of acute and gross metabolic conditions, most common were Infection (58.33%), followed by Xanthelasma (2.1%) and Infestation (1.35%).

In chronic degenerative conditions, most common manifestation was planter keratoderma (2.1%).

In 35 patients of other manifestations frequently associated with DM, highest incidence was of acrochordon (skin tags) in (12.14%) followed by

generalised pruritus(10%), xerosis(6.4%), acanthosis nigricans(6.4%) and granuloma annulare(2.1%).

Other manifestations comprised of perforating dermatosis, vitiligo vulgaris, psoriasis vulgaris in (1.67%) patients each.

There was 1 patient of lichen planus, alopecia areata, prurigo simplex, prurigo nodularis, necrobiosis lipodica, diabetes digital sclerosis and ear lobe crease each(TABLE 2).

Table 2: Cutaneous Manifestations Of Diabetes Mellitus

Diabetes Mellitus	% Of Total Pts Present Study (2021) N=120	% Of Total Pts Girish et al Study ⁴ (2013) (N=240)	% Of Total Pts Roslind et al Study ⁵ (2020)(N=100)
Acute And Gross Metabolic Conditions			
Fungal Infection	28.6	18	55
Bacterial Infection	22.5	22	36
Viral Infection	3.5	2	11
Infestation	1.35	-	-
Xanthelasma	2.1	-	5
Chronic Degenerative Conditions			
Plantar Keratoderma	2.1	-	-
Trophic Ulcer	1.42	-	2
Diabetic Bullae	0.7	-	3
Diabetic Dermopathy	0.7	8	16
Diabetic Gangrene	0.7	-	2
Lipodermatosclerosis	0.7	2.67	1
Callosity	0.7	-	-
Other Manifestations Frequently Associated With Dm			
Skin Tags	12.14	2	27
Generalised Pruritus	10	6	-
Acanthosis Nigricans	6.4	4	2
Xerosis	6.4	12	21
Granuloma Annulare	2.1	2.67	1
Perforating Dermatitis	1.67	-	2
Vitiligo Vulgaris	1.67	8	-
Psoriasis Vulgaris	1.67	-	-
Alopecia Areata	0.7	-	-
Lichen Planus	0.7	2.67	-
Diabetes Digital Sclerosis	0.7	-	-
Necrobiosis Lipoidica	0.7	-	1
Prurigo Simplex	0.7	-	-
Prurigo Nodularis	0.7	-	-
Ear Lobe Crease	0.7	-	10

Infections were most common cutaneous manifestation in 58.33% patients. Most common infection was fungal infection(28.6%) followed by bacterial infection(22.5%) and Viral infection (3.5%).

In present study, total 48 patients of hypothyroidism and 8 patients of hyperthyroidism were having cutaneous manifestations of thyroid disorders (TABLE 3).

In hypothyroidism, most common cutaneous manifestation was diffuse hair fall (70.8%) followed by xerosis (62.5%), planter keratoderma (16.66%), alopecia areata(12.5%), vitiligo(10.41%) and psoriasis (4.1%). Association of hypo thyroidism was seen in 1 patient each of lichen

planus, tinea corporis, tinea cruris, systemic sclerosis and myxedema facies.(TABLE 3)

In hyperthyroidism, diffuse hair loss and pruritus were most common manifestations in 37.5% patients each, other common manifestations were facial flushing, pretibial myxedema and melasma in 25% patients each.

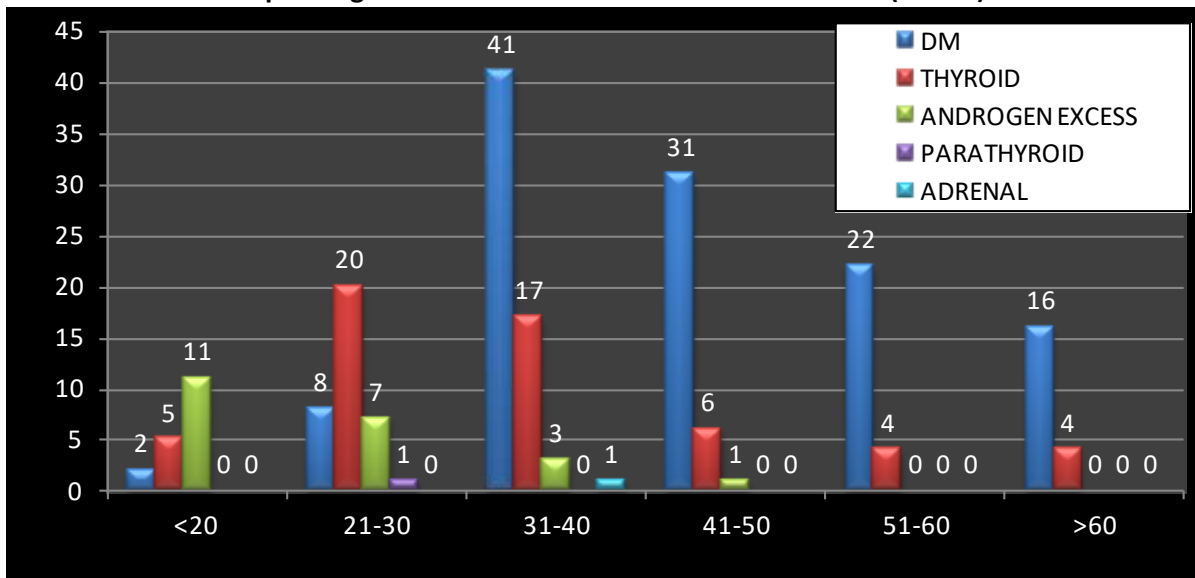
Androgen excess was seen in 22 patients, which included 45.5% patients of acne vulgaris, 31.8% patients of hirsutism and 22.7% patients of PCOS.

There was 1 patient of hyperparathyroidism having eczema. 1 patient of cushing syndrome showed striae over abdomen.

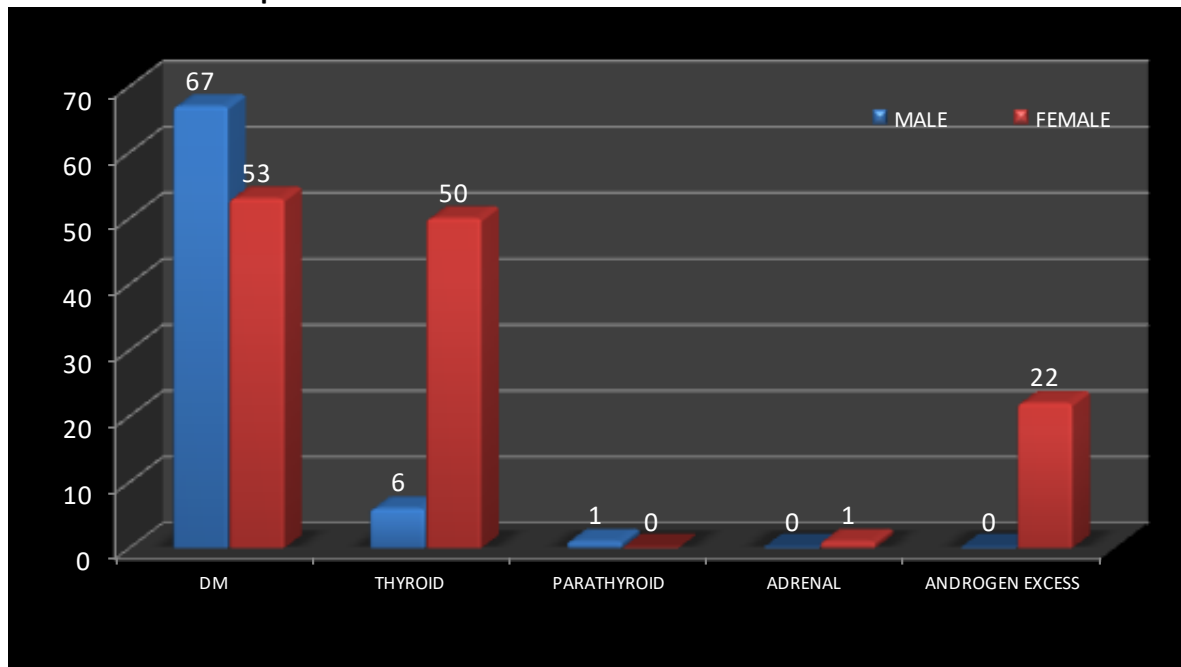
Table 3: Cutaneous Manifestations In Hypothyroidism

Hypo Thyroidism	% Of Total Pts Present Study(N=48)	% Of Total Pts Study Bains et al ⁹ (2019) (N=113)	% Of Total Pts Study Kambil Sm et al ⁸ (2015) (N=123)
Diffuse Hair Fall	70.8	47.78	40
Xerosis	62.5	67.25	54
Plantar Keratoderma	16.6	-	16
Alopecia Areata	12.5	5.30	4
Vitiligo	10.41	2.65	3
Psoriasis	4.1	2.65	-
Tinea Corporis	2.08	-	-
Tinea Cruris	2.08	-	-
Lichen Planus	2.08	0.88	-
Myxedema Facies	2.08	-	20
Systemic Sclerosis	2.08	-	-

Graph 1: Agewise Distribution Of Endocrine Disorders (N=200)



Graph 2: Sex Wise Distribution Of Various Endocrine Disorders



Discussion: In the present study, 200 cases with endocrine disorders were examined for skin manifestations. Among the 200 patients, Maximum no of patients had diabetes(120), followed by thyroid disorders(56), Androgen excess(22) and 1 patient of cushing syndrome and hyperparathyroidism each(Table 1).

There were 126 females and 74 males, with female:male ratio 1.7:1, suggestive of female preponderance. Kirthi Sampath K et al also reported female preponderance in their study.²

In cutaneous manifestations of DM most common age group affected was 41-60 years(44.16%). This is because of diabetes constituted the major study group and it is more common in this age group. This study correlated well with the study of Kirthi Sampath K et al, in which 56% of the patients belonged to 41-60 years age group.² Mahajan S et al also reported that frequency of skin disease in DM was more in 41-60 years age group.³

The various dermatological manifestations seen in patients of DM have been listed out in Table 2.

Infections were most common cutaneous manifestation(58.33%) which is comparable with Girish et al study⁴ in which 42% cases had infections.

In infections, most common was fungal infection(28.6%), which was comparable with Girish et al⁴ (18%). In fungal infection, dermatophytosis is most common cutaneous manifestation, which is similar to the data in current medical literatures. There is a huge change in clinical profile of patients presenting with dermatophytosis which is due to irrational use of combinations containing topical steroids.

Infection is having tendency to recur more frequently. Second most common fungal infection was candidiasis. Candidiasis is common in diabetic patients as raised blood sugar level favours growth of yeast.

Bacterial infections were second most common infections presented in DM (22.5%), which is comparable to Girish et al (22%) and Roslind et al(36%)⁵ studies. It is well known that diabetic patients were susceptible to infections probably due to hyperglycemia and defects in polymorphonuclear leucocyte function. Viral

infections were least common infection associated with DM (3.5%).

Xanthelesma was seen in 2.1% patients. Hypertriglyceridemia leads to Xanthelasma, which is associated with insulin deficiency and metabolic derangement in diabetes.

In chronic degenerative conditions, most common manifestation was planter keratoderma(2.1%) while diabetic bullae was present in 0.7% patients, which was comparable to Momin et al study(0.88%)⁶. In diabetes, neuropathy and microangiopathy leads to plantar keratoderma, callosity, ulcer and gangrene.

Diabetic dermopathy and diabetic bullae may result from diabetic microangiopathy. In 35 patients of other manifestations frequently associated with DM, highest incidence was of acrochordon(skin tags)(12.14%) followed by generalised pruritus (10%), xerosis(6.4%) and acanthosis nigricans(6.4%). Skin tags were most frequently associated condition(12.14%), which is comparable to Vahora et al study (13.33%)⁷.

Generalized pruritus was seen in 10% patients, which is comparable to Girish et al study (6%)⁴.

Higher percentage of acanthosis nigricans and skin tags were suggestive of insulin resistance in diabetic patients. Recently, it has been recognized that acanthosis nigricans may also be a relatively common marker for increased long-term risk of the less dramatic but potentially serious systemic disorders associated with insulin resistance and compensatory increased insulin secretion.

Total 48 patients of hypothyroidism and 8 patients of hyperthyroidism were having cutaneous manifestations of thyroid disorders (TABLE 3).

In hypothyroidism, most common cutaneous manifestation was diffuse hair fall (70.8%), which was comparable with Kambil SM et al⁸ study (40%). Second most common manifestation of hypothyroidism was xerosis(62.5%), which was comparable with studies carried out by Bains et al⁹ (67.5%) and Kambil SM et al⁸ (54%). Other manifestations were planter keratoderma (16.66%), alopecia areata (12.5%), vitiligo (10.41%) and psoriasis (4.1%). Association of hypothyroidism were seen in 1 patient each of

lichen planus, tinea corporis, tinea cruris, systemic sclerosis and myxedema facies, which was comparable with Keen et al study¹⁰.

Total 8 patients of hyperthyroidism were having cutaneous manifestations, in which diffuse hair loss and pruritus were most common manifestations (37.5%) each, which were comparable with study of Kambil SM et al⁸. Other common manifestations of hyperthyroidism were facial flushing, pretibial myxedema and melasma in 25% patients each.

Both hypo and hyperthyroidism were highly associated with various cutaneous changes. Hypothyroidism is generally associated with thick, dry skin, livedo reticularis of the extremities and thinning of hair. Hair becomes dry, brittle with extent of disease dictating severity of manifestations.

These effects were due to a decreased metabolic rate which causes peripheral vasoconstriction and decreased sebaceous gland secretion.

Hyperthyroidism is associated with thin, soft hair with possible progression to alopecia, onychodystrophy, and hyperpigmentation of the hands, feet and face. Graves disease is most commonly associated with ophthalmopathy, pretibial myxedema, and moist pruritic skin.

Pretibial myxedema can occur in other distributions such as arms, shoulders, neck, and upper back.

Androgen excess was seen in 22 patients, which included 45.5% patients of acne vulgaris, 31.8% patients of hirsutism and 22.7% patients of PCOS.

Polycystic ovary syndrome is characterized by the excessive production of androgens, which can manifest in adolescent girls as menstrual irregularities, android type obesity, and skin changes, such as acne and/or hirsutism¹¹. Initial screening for suspected androgen-associated disease is usually serum dehydro epiandrosterone sulfate, testosterone, and prolactin tests.

Hirsutism is defined as excessive growth of terminal hairs in androgen-dependent areas, primarily the face, neck, back, chest, and lower abdomen. Hyperandrogenism promotes an

increase in hair thickness and prolongs the phase of hair growth in the beard, armpits, and pubis.

Acne vulgaris is an additional manifestation of polycystic ovary syndrome. Especially moderate to severe acne that is resistant to traditional treatments or recurrence after the use of isotretinoin should be overlooked for androgen excess.

Conclusion: The present study shows the wide range of skin lesions in patients with endocrinological disorders particularly diabetes mellitus and thyroid diseases. Understanding the associated skin lesions aids in the early detection of the underlying endocrine imbalance, and the implementation of the appropriate treatment which helps to avoid morbidity.

Figure 1: Necrobiosis Lipoidica In DM

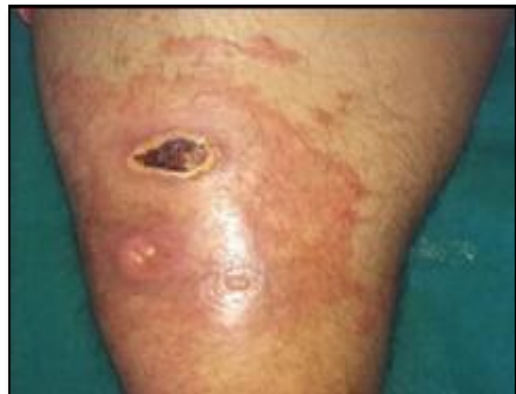

Figure 2: Diabetic Bullae

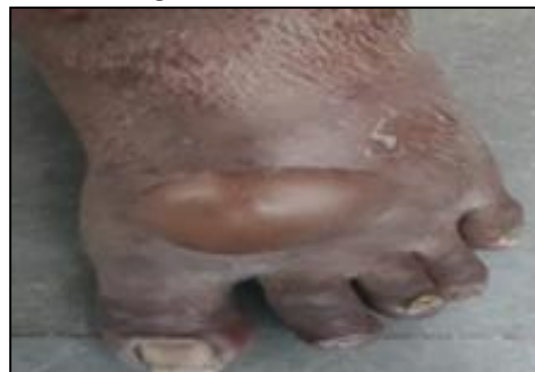

Figure 3: Alopecia Areata In Hypothyroidism

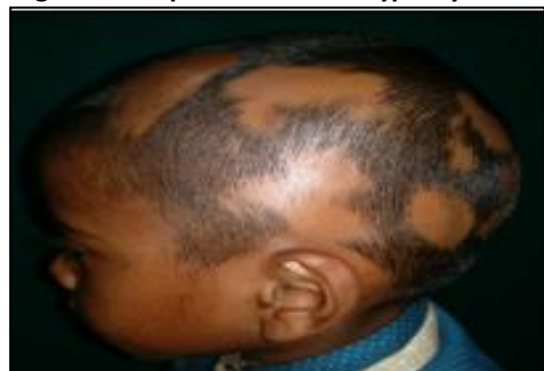
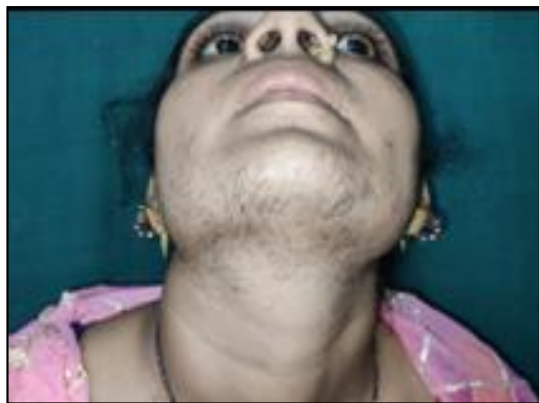
Figure 4: Hirsutism With Androgeb Excess



A Cross-Sectional Clinical Study. Indian Dermatol Online J. 2017;8(2):104-110.

Conflict of interest: None

Funding: None

Cite this Article as: Chaudhary D, Bunker A, Patel B, Bhuptani N. A Study Of Various Clinical Pattern Of Cutaneous Manifestations In Endocrine Disorders. Natl J Integr Res Med 2023; Vol.14(2): 01-07
--

References:

1. Skin manifestations of internal diseases. IADVL Text Book of Dermatology. 4th edition. 2015: 1915-64.
2. KirthiSampath K, Haritha S, Mahesh B. Cutaneous manifestations of endocrine disorders. Int J Res Dermatol 2018;4:234-9
3. Mahajan S, Koranne R V, Sharma S K. Cutaneous manifestation of diabetes melitus. Indian J DermatolVenereolLepr 2003;69:105-108
4. Verma, Girish Chandra et al. Prevalence of Cutaneous Manifestations of Diabetes Mellitus. IOSR Journal of Dental and Medical Sciences 11 (2013): 41-47.
5. Roslind S, Muhammed K, Sajeeth Kumar KG. Cutaneous manifestations in patients with type 2 diabetes mellitus and normal controls. J Skin Sex Transm Dis 2020;2(1):26-30.
6. Momin A, Astik B. Cutaneous manifestations in endocrinal disorders- an observational study. J. Evid. Based Med. Healthc. 2019; 6(23), 1649-1653.
7. Vahora R, Thakkar S, Marfatia Y. Skin, a mirror reflecting diabetes mellitus: A longitudinal study in a tertiary care hospital in Gujarat. Indian J Endocr Metab 2013;17:659-64.
8. Kambil SM. Clinical study of skin manifestations of hypothyroidism at a tertiary hospital in North Kerala. Int J Res Dermatol 2018;88-92.
9. Bains A, Tegta G R, Vedant D. A cross-sectional study of cutaneous changes in patients with acquired thyroid disorders. Clin Dermatol Rev 2019;3:72-7.
10. Keen MA, Hassan I, Bhat MH. A clinical study of the cutaneous manifestations of hypothyroidism in kashmir valley. Indian J Dermatol. 2013;58:326.
11. Keen MA, Shah IH, Sheikh G. Cutaneous Manifestations of Polycystic Ovary Syndrome: