

Rehabilitation of a Hemimaxillectomy Patient with Flexible Obturator Prosthesis

Dr Deval Shah*, Dr Alka Patwa**, Dr Varun Pitti*

*Karnavati School of Dentistry; **Goenka Research Institute of Dental Sciences, Ahmedabad

Abstracts: Rehabilitation of hemimaxillectomy patients can be challenging. The most common prosthetic treatment problem with such patients is, getting adequate retention, stability and support. The size and location of the defect usually influences the amount of impairment and difficulty in prosthetic rehabilitation. Obturator prosthesis is commonly used as an effective means for rehabilitating hemimaxillectomy cases. In cases of maxillary defect, obtaining satisfactory retention, stability & biocompatibility in the definitive obturator prosthesis can be elusive. Resilient denture materials are extremely useful in retaining the prosthesis, which obturates the maxillary defects. This clinical report describes making of flexible obturator prosthesis with modified buccal flange on unresected side as a means of indirect retention. This approach provides excellent mouldability, light weight & strength of the prosthesis to increase the retention, stability and comfort. [Shah D et al NJIRM 2012; 3(3) : 182-185]

Key words: flexible obturator, hemimaxillectomy, buccal flange

Author for correspondence: Dr Deval Shah, Karnavati School of Dentistry, Ahmedabad.

E - mail :drdevaldentist@gmail.com

Introduction: The intraoral defects in the maxilla are due to trauma, disease, pathological changes, radiation burns or surgical intervention. The defect may be small or it may include any portion of the hard and soft palate, the alveolar ridges and the floor of the nasal cavity. Post surgical defects in the maxilla result in hypernasal speech, fluid leakage into the nasal cavity and impaired masticatory function. The primary objectives in rehabilitating the maxillectomy patient are to restore the function of mastication, deglutition and speech and to achieve normal oro-facial appearance¹. The most common prosthodontic treatment problems with maxillectomy patients are lack of retention, stability and support. The size of the defect, the number of remaining teeth, the amount of the remaining bony structure and patient ability to adapt to the prosthesis are few factors which affect the prognosis of the treatment^{2,3}. The complex anatomy of the midface and its endless potential for surgical or traumatic defect size, shape and location also presents with numerous possible configurations of treatment considerations. The hard palate defects can be rehabilitated with an obturator denture⁴.

Flexible denture bases have got various advantages over the traditional rigid denture bases. Translucency of the material picks up underlying tissue tones, making it almost impossible to detect in the mouth. Complete biocompatibility is achieved because the material is free of monomer and metal, these being the principle causes of allergic reactions

in conventional denture materials. Clinicians are able to use areas of the ridge that would not be possible with conventional denture techniques. Flexible dentures will not cause sore spots due to negative reaction to acrylic resins and will absorb small amounts of water to make the denture more soft tissue compatible^{5,6}.

Case Report: A moderately built 22 years old male patient reported to the Department of Prosthodontics, Karnavati School of Dentistry, Gandhinagar complaining of difficulty in speech and leakage of food and liquid from the oral cavity into the nasopharynx. The medical records of the patient revealed that he had epidermoid carcinoma of the left maxilla involving the maxillary antrum. He underwent right side extended maxillectomy with temporalis flap grafting in palate three month ago. (fig 1,2)

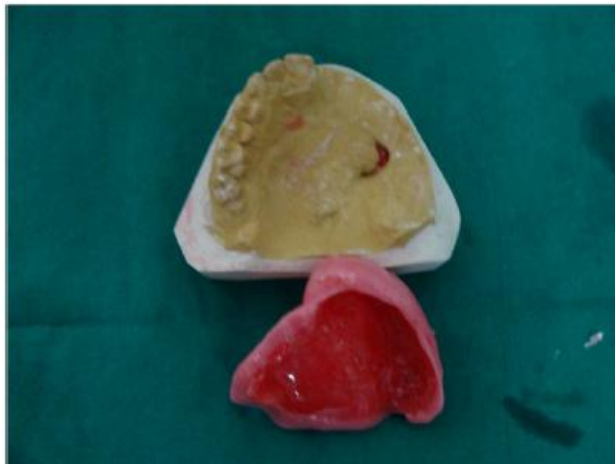
Fig-1: Pre operative Photograph

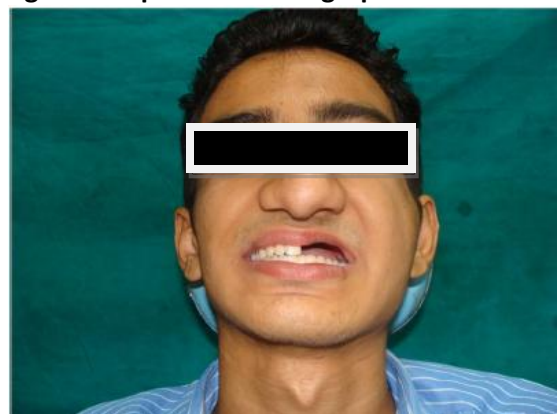
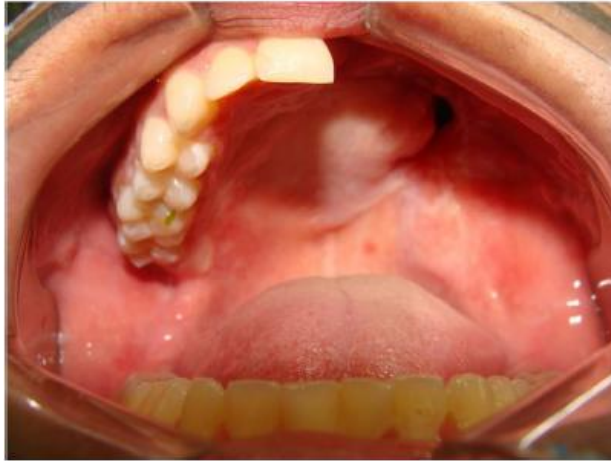
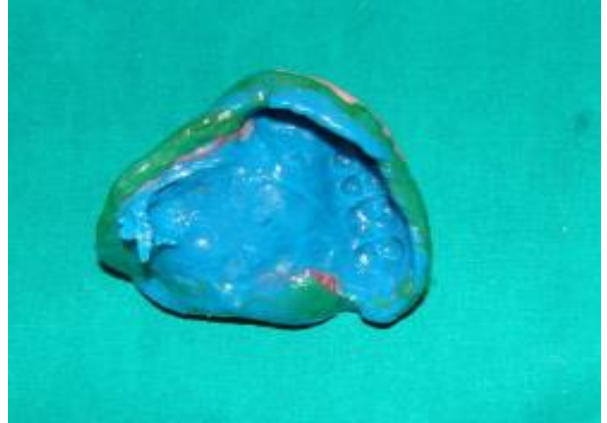Figure – 2: Internal View Of Figure

On examination, the left side of his face was found to be depressed inwards and gave an unaesthetic appearance. The patient had a large defect extending from right incisor region to the soft palate. Palatal grafting was done to minimize the defect. He had Class 1 defect according to the Armany classification⁷. An obvious nasal twang was observed in the speech of the patient. The lower arch was completely dentulous. A closed type flexible obturator was planned. To enhance the retention, a buccal flange on the right side was modified and was joined with the prosthesis.

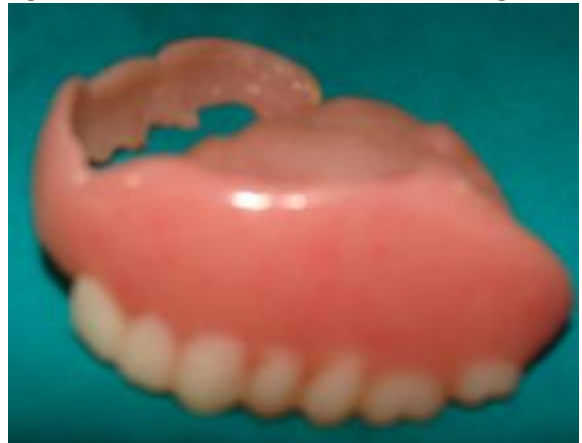The preliminary impression was made with irreversible hydrocolloid and a stone cast was poured from the impression. (fig 3)

Figure 3- Primary Cast With Special Tray

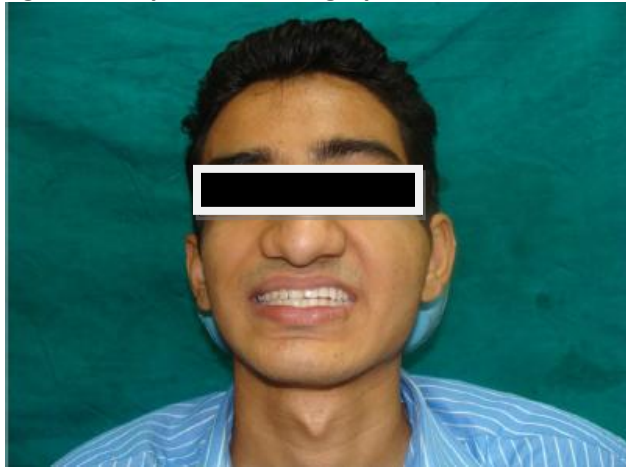An acrylic resin base was fabricated and green stick compound was used to properly record the tissue seal on the defect side & to achieve a proper peripheral seal. The final impression was made of light body impression material (fig 4).

Figure 4: Final Impression

The impression was boxed and the master cast was poured in type IV dental stone. The denture base was fabricated with self cure resin and occlusal rims were made to record the jaw relation. After selecting the teeth, denture try-in was performed in the conventional manner, as in the complete denture construction. After verification of the jaw relation, the trial denture was sent to the lab for prosthesis fabrication. A closed type flexible obturator was processed in injection system with Luciton FRS (F.D). For better retention buccal extension on right side was given (fig 5).

Figure 5- Final Prosthesis with buccal flange

The final prosthesis was inserted into the patient's mouth (fig 6) and it was checked for proper palatal contour and peripheral seal. The patient was educated about the maintenance of the prosthesis and was recalled for regular post-insertion visits. Adequate retention, stability and support were observed on subsequent recalls. The patient's normal swallowing ability was restored by the prosthesis and he was pleased with the dramatic improvement of speech and retention of the prosthesis.

Fig-6: Post operative Photograph

Discussion : Acquired defects in the maxilla due to surgical resection result in a communication between the oral and nasal cavities that causes difficulty in deglutition, speech and an unaesthetic appearance. Apart from this, it also results in psychological trauma to the patient. Small defects are usually closed by surgical means, but larger defects are often prosthodontically rehabilitated by obturators⁸.

This clinical report illustrates a class 1 defect, which was rehabilitated by a closed flexible obturator. The main objective was to decrease the weight and minimize the rotation of the prosthesis. Flexible denture base material helps to reduce the weight of the obturator, to decrease pressure to the surrounding tissues, to aid in deglutition and to encourage regeneration of the tissues. The lightness of the obturator also does not cause excessive atrophy and physiological changes in muscle balance^{1,9}.

The patterns of forces affecting the obturator prosthesis are complex because of their concurrent occurrence and mostly destabilize the prosthesis. These destabilizing forces need to be controlled by effectively and strategically positioning the indirect retainers. In the class 1 situation, the functional fulcrum line lies along the bony contours, next to the resected area and to provide maximum retention, the indirect retainer should lie in the premolar region. In this case, a modified buccal flange was placed over the unresected side and was connected to the obturator. This provision in the prosthesis helped in minimizing the rotation of

the prosthesis around the functional fulcrum line and also, it is easy to fabricate and greatly enhances the retention of the obturator.

Flexible dentures absorb small amounts of water to make the denture more soft tissue compatible. They will not warp or become brittle. These dentures stand aesthetically superior removable dentures with full functionality and comfort. Complete biocompatibility is also achieved because the material is free of monomer and metal, these being the principle causes of allergic reactions in conventional denture materials^{5,6}

The temporalis flap is a useful, reliable, and versatile option for reconstruction of moderate to large sized defects. The muscle can provide abundant tissue, with minimal to no functional morbidity or esthetic deformity in the donor site¹⁰.

Conclusion: The most challenging part in rehabilitating the patient with hemimaxillectomy, is to obtain adequate retention and stability. Flexible obturator has excellent biocompatibility, light weight of prosthesis and provide good mouldability. The modified buccal flange on the unresected side not only improves retention but also provides adequate stability to the prosthesis. This type of retention aid provides an easy option to achieve the primary objective of restoring the functions of mastication, speech and aesthetics.

Acknowledgement : I would like to thank all my friends who helped me out in the treatment of this patient. I would like to thank the management of the hospital where this patient was treated for giving me full support and help.

References:

1. Beumer J, Curtis TA, Firtell DN. Maxillofacial Rehabilitation. Prosthodontic and surgical considerations. C.V. Mosby Co., St Louis, Toronto. 1979 pg.183-243.
2. Parr GR, Tharp GE, Rahn AO. Prosthodontic principles in the framework design of maxillary obturator prosthesis. J Prosthet Dent 1989; 62: 205-12.
3. Desjardins R. Early rehabilitative management of the maxillectomy patients. J Prosthet Dent 1977; 38: 311-18.

4. Chalian V A maxillofacial prosthetic multidisciplinary practice The Williams and Wilkins company 1972:163-177
5. Prashanti E, Jain N, Shenoy V K, Flexible denture- A flexible option to treat edentulous patient. J of Nepal Dental Association 2010 : 11; 85-87
6. Dr Sunitha Shamnur, Dr Jagdish K N, Dr Kalavathi K R- 'Flexible Dentures- An alternate for rigid dentures . Journal of Dental Sciences & Research 2011; 1: 74-79
7. Aramany MA. Basic principles of obturator design for partially edentulous patients. Part II: design principles. J Prosthet Dent 1978; 40: 656-62.
8. Zarb GA. The maxillary resection and its prosthetic replacement. J Prosthet Dent 1967; 18: 268-81.
9. Keyf F. Obturator prosthesis for maxillectomy patients. J Oral Rehab 2001; 28: 821-29.
10. Abubanker A O, Abouzgia M B The temporalis muscle flap in reconstruction of intraoral defects. Oral Surg, Oral Med, Oral Pathol, Oral Radiol, Endod 2002 : 94(1): 24-30.