

Is There Any Correlation Between Computed Tomography (CT) Attenuation Value (Hounsfield Unit) Of Dural Venous Sinuses And Hemoglobin Level: A Prospective Observational Study

Dr. Vipul Virabhai Solanki*, Dr. Chinmay J Shah**, Dr. Bhaven Shah***,
Dr. Bhakti Vadodariya****, Dr. Arti Solanki****

*Assistant Professor, Department Of Radio Diagnosis, **Professor And Head, Department Of Physiology, Government Medical College, Bhavnagar - 364001 Gujarat , ***Professor, Department Of Radio Diagnosis, Gujarat Adani Institute Of Medical Science Bhuj, Gujarat , ****Resident, Department Of Radio Diagnosis, Government Medical College, Bhavnagar - 364001 Gujarat

Abstract:Background:In our routine practice patient were undergone CT scan of brain as well as other laboratory investigation for various traumatic brain injury and neurological complain and its management. They visit many premises for diagnosis and investigation. If we can predict the hemoglobin level from CT brain itself, we can reduce turnaround time for patient and increase throughput of patients for hospital. Keeping this in mind we had conducted this study to see the correlation between hemoglobin level and CT attenuation value of cranial Dural sinuses.**Material And Methods:**A prospective observational study was performed to demonstrate association between computed tomography (CT) attenuation value (Hounsfield unit (HU)) of dural venous sinuses and hemoglobin level from unenhanced CT scan of the brain. The non-contrast CT brain of total 245 patients done during October 2017 to September 2018 at medical college attached tertiary care was observed. Two measurements of HU value were taken on two adjacent slices using 10mm² of ROI for each site, from superior sagittal sinus (SSS) and torcular herophili (TOH). The value was averaged for superior sagittal sinus, confluence of sinus and is compared with hemoglobin of patients.**Result:**Mean HU VALUE in SSS of females and male had 48.47 and 51.85 respectively. Mean HU VALUE in TOH of females and male had 47.46 and 50.93 respectively. Positive and significant correlation was noted between HB and SSS average, HB and TOH Average.**Conclusion:**Based on our result CT attenuation value (HU) value of torcular herophili and superior sagittal sinus from unenhanced CT scan of brain can be used to predict the hemoglobin level of a person. The HU value of sinus can give insight into pathology such as anemia, polycythemia or cranial sinus thrombosis.[Solanki V Natl J Integr Res Med, 2021; 12(3): 20-24]

Key Words:Computed tomography, Dural venous sinus, Hemoglobin (HB), CT attenuation value (HU)

Author for correspondence: DR. Vipul V. Solanki, Assistant Professor, Department OF Radiology Diagnosis, Government Medical College, Bhavnagar -364001 E-Mail:vir_bapu1989@yahoo.co.in Mobile: 9016910257

Introduction: It is routine to have a CT brain imaging in all patients who present with an acute neurological deficit, motor vehicular accident and headache without having their blood report in hand. By the time their CT scan report becomes available the hemoglobin level of patients is not known. Relation of anemia and headache is well known¹. There are many patients with traumatic brain injury , headache undergone CT head before undergoing hemogram report.

Prediction of HB level from CT brain images can reduced mortality and morbidity. Normal CT brain in the headache directs the patient for workup of anemia if required. Anemia is a prevalent clinical condition in India². Conventional method to diagnose anemia is to do a hemogram in a pathology laboratory. In our routine practice, we have observed that radiodensity or attenuation value (CT HU value) on CT images

within the intracranial vasculature may vary greatly among patients. In some cases, hyper density or higher HU value within a given vascular structure may lead to the suspicion of vascular thrombosis.

The concept of “hemo-concentration” or elevated levels of HGB or HCT leading to increased x- ray attenuation within the vasculature is widely accepted.³ On the other hand, the data substantiating such a correlation are fairly weak, being limited to a very few studies^{4,5,6}.

HU value is pixel attenuation value on CT images represent x ray attenuation value of patient’s small volumetric element i.e. voxel and that depends upon: Total Atomic number of tissue, Density and thickness of tissue kVp used during scan. By using a specific scan protocol of head CT

This is an Open Access article distributed under the terms of the Creative Commons Attribution 4.0 International License (<http://creativecommons.org/licenses/by/4.0/>), allowing third parties to copy and redistribute the material in any medium or format and to remix, transform, and build upon the material for any purpose, even commercially, provided the original work is properly cited and states its license.

scan all variables except atomic number and density of particular tissue are different.

Intravascular blood gives hyper density (subjective) and high attenuation (HU) value on unenhanced CT brain. Said high attenuation of blood is attributed to the higher density and atomic number of hemoglobin among all blood content. This is the basis of our study. This study is prospective, with a larger sample size. It takes account of a larger (ROI) region of interest to measure HU value from multiple sites.

Keeping in mind the above fact we want to see the quantification of CT attenuation in relation with the hemoglobin. Present study was done with an aim to demonstrate association between computed tomography (CT) attenuation (CT HU value) value of intracranial Dural venous sinuses and hemoglobin level from unenhanced CT scan of brain.

Material & Methods: After obtaining permission from institutional ethical committee A prospective observational study was performed to demonstrate the association between computed tomography (CT) attenuation value (hounsfield unit (HU)) of dural venous sinuses and hemoglobin level from unenhanced CT scan of the brain of 245 patients. All patients were informed regarding study and its outcome.

The non-contrast CT brain of all patients done during October 2017 to September 2018 at Medical college attached tertiary care General Hospital, was observed. Patients with calvarial fracture hindering HU measurement of venous sinuses, recent history of contrast administration, known hypercoagulable state, pregnant patients, and those with a history of recent blood transfusion were excluded. A hemogram of patients if done in 12 hours of CT scan was included.

Non contrast CT brain was performed on a multidetector third generation CT scanner. The Slice thickness was 1.2mm and the exposure factor was 130 kv and 140mAS. All images were reformatted on DICOM workstation displays in axial, coronal and sagittal planes with WW80 and WL 35. Representative images 1 and 2. Region of interest (ROI) was drawn on the axial and coronal plane for superior sagittal sinus, confluence of sinus. Two measurements of HU

value were taken on two adjacent slice using 10mm² of ROI for each site. The values were averaged for superior sagittal sinus, confluence of sinus and are compared with hemoglobin and hematocrit of patients. The hemoglobin measurement done in laboratory is colorimetry. Representative Images are shown below.

Image 1: From Superior Sagittal Sinus

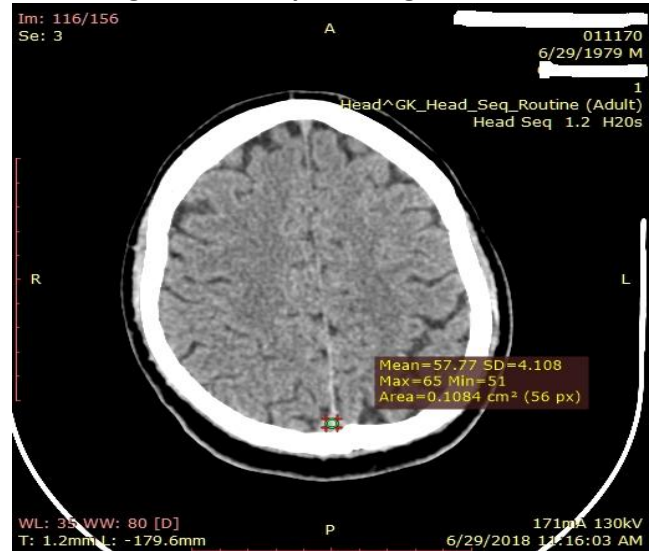
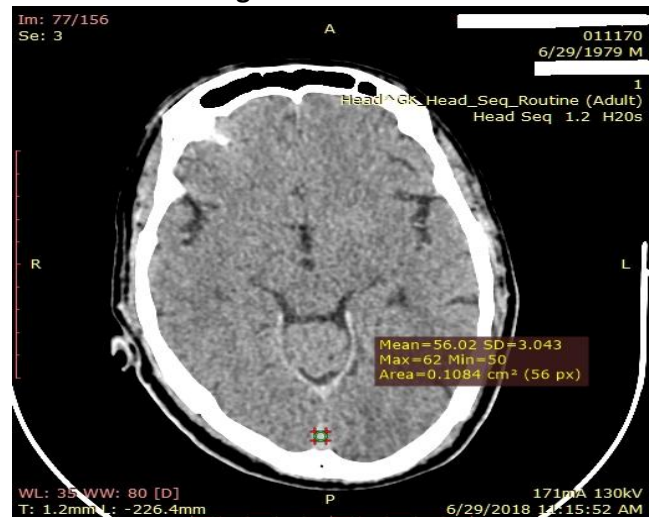


Image 2: From TOH



Statistical Analysis: Data entry done in excel spreadsheet Microsoft office home and student 2016. All data was then exported in the epi info 7 software. First there was demographic and general analysis followed by central tendency measurement to demonstrate the correlation linear regression was applied to total study participant with stratification based on sex.

Results: Table 1 below describes Age and Gender wise distribution of study participants. Maximum numbers of participants of both genders were in the age group of 24-64 years.

Table 1: Table 1 Age And Gender Wise Distribution Of Study Participants

Age Group	Female	Male	Total	Remarks
0-14 Year	5	6	11	Child
14-24 Year	2	23	25	Youth
24-64 Year	42	110	152	Adult
>65 Year	25	32	57	Senior
Total	74	171	245	

Table 2 illustrates presenting complaints for which the person had undergone an unenhanced CT scan of the brain. Maximum number of male patients had head injury, while maximum number of female patients had Neurology deficit

Table 2: Presenting Complaints For Which The Person Had Undergone An Unenhanced CT Scan Of The Brain

Presenting Complaint	Male	Female	Total
Dizziness	2	6	8
Headache	12	8	20
Head Injury	71	21	92
Neurology Deficit	61	26	87
Altered Sensorium	13	10	23
Convulsion	0	1	1
Other/No Details	12	2	14
Total	171	74	245

Table 3 describes Mean distribution of hemoglobin value stratified with male and female data. Mean hemoglobin values for males was 13.13 ± 2.24 and for female it was 11.32 ± 2.25 .

Table 3: Mean Distribution Of Hemoglobin Value Stratified With Male And Female Data

	Total	Hemoglobin gm/dl	
		Mean	Range
Female	74	11.32 ± 2.25	5.30-16.10
Male	171	13.13 ± 2.24	4.70-17.50
Total	245	12.58 ± 2.39	4.70-17.50

Table 4 illustrates mean distribution of average CT attenuation value HU value from superior sagittal sinus. (SSS AVG) mean SSS AVG for male was 51.85 ± 5.23 and 50.83 ± 5.49 for females. Table 5 explains mean distribution of average CT attenuation value HU value from to rcularherophili (TOH AVG). Mean TOH AVG for female and males were 47.46 ± 4.55 and 50.93 ± 4.48 respectively.

Significant and positive correlation was observed between HB and AVGSS (Table 6, Image 3) and also between HB and AVGTOH. (Table 7, Image 3)

Table 4: Mean Distribution Of Average CT Attenuation Value HU Value From Superior Sagittal Sinus (SSS AVG) Stratified With Male And Female Data

	Total	SSS AVG Value	
		Mean	Range
Female	74	48.47 ± 5.41	33.52-64.63
Male	171	51.85 ± 5.23	33.08-67.65
Total	245	50.83 ± 5.49	33.08-67.65

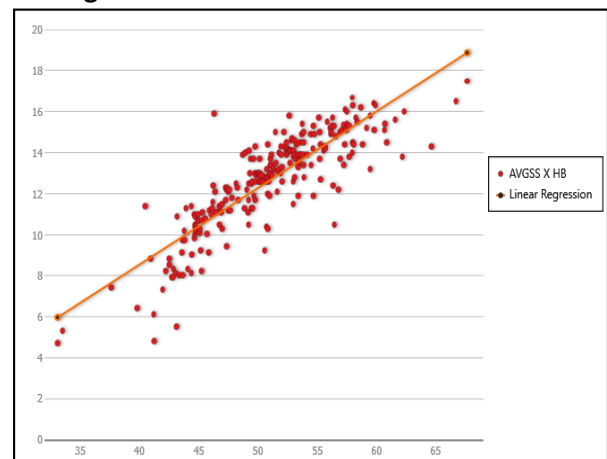
Table 5: Mean Distribution Of Average CT Attenuation Value HU Value From Torcularherophili (TOH AVG) Stratified With Male And Female Data

	Total	TOH AVG Value	
		Mean	Range
Female	74	47.46 ± 4.55	32.42-57.79
Male	171	50.93 ± 4.48	32.55-59.32
Total	245	49.88 ± 4.77	32.45-59.32

Table 6: Correlation Analysis Between HB And AVGSS (Pearson's Correlation Analysis)

Coefficient	T Value	P value
0.8576	25.9891	<0.0001

Image 3: Correlation of HB And AVG SSS HU



Discussion: In patient of traumatic injury, neurological deficit and with complain of headache the haemoglobin level play major and decisive role during management. In traumatic brain injury and in multi organ injury cases the window for detail haematological workup is narrow. If we can predict the haemoglobin level from CT scan of brain than it will be of great value for management and at time lifesaving.

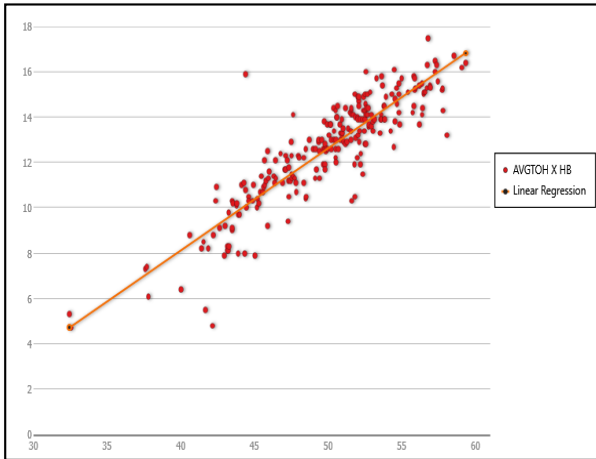
In patient with headache and neurological deficit prediction of haemoglobin level from CT density of cranial sinuses leads to narrow the differential and reduced the mortality of patient. This all leads to reduced turn round time for patient and

increase throughput of patient for hospital. Haemoglobin level by calorimeter from pathology investigation is the gold standard method.

Table 7: Correlation Analysis Between HB And AVGTOH (Pearson's Correlation Analysis)

Coefficient	T Value	P value
0.8972	31.6606	<0.0001

Image 4: Correlation of HB And AVG TOH HU



Anaemia or polycythaemia both conditions can cause altered blood density and so as the attenuation of x-ray, more specifically CT attenuation value. To honour the inventor of CT scan CT attenuation value was given the name Hounsfield unit -HU value. The superior sagittal sinus and torcular herophili has less

anatomical variation, easily localized on axial and coronal CT images of the brain. Therefore this is a perfect site to see for density and HU value measurement. The X ray attenuation values from (Dural venous sinuses) torcular Herophili, sigmoid, sagittal and transverse sinus from unenhanced CT (HU VALUE) brain is attributed to the density of blood³.

It is well known among radiologists to give diagnosis of extradural hematoma, subdural hematoma and intraventricular haemorrhage when it gives hyperdense appearance as an acute event with exception of severe anaemic patients which have hypo density⁷.

Healy JF, Nichols C et al reported case of polycythaemia as mimics of venous sinuses thrombosis because raised haemoglobin gives hyper dense appearance of Dural venous sinuses⁸.

D.F. Black et al attribute increased attenuation of venous sinus on unenhanced CT head to the hem concentration and correlate it with haematocrit of patients and also try to diagnosed venous sinus thrombosis from HU value haematocrit ratio (H:H)(N166)⁴.

In retrospective study silver g bruini had made an attempt to predict anaemia from HU value of cranial sinus from unenhanced CT head (N 100)⁵.

Pop marine et all made multi parametric correlation models for attenuation value and blood indices and found positive association between CT HU value and haemoglobin level using unenhanced CT thorax.(N144)⁶.

There is a moderate, yet statistically significant (p < 0.001), correlation between Hgb levels and attenuation values in upper, middle and lower segments of the SSS (r = 0.487, 0.497 and 0.533 respectively)⁹.

In our study With demonstration of significant positive correlation between HB level and HU value of superior sagittal sinus (Pearson's Correlation 0.8576),torcular herophili (Pearson's Correlation 0.8972)in total study sample, male and female stratification we can predict the haemoglobin level range from the Dural sinus on CT scan brain images. While reporting CT brain images if the dural sinus is relatively hypo dense as compared to brain parenchyma or hyper dense than radiologist may suggest haemoglobin correlation to rule out underlying haematological abnormality.

Limitation: However the CT brain cannot replace the hemogram as the gold standard for HB level. Small sample size with unequal gender wise distribution. Unequal number of scan as far as presenting complains are concern. The study can be extended to include CT HU value of Dural sinus, vena cava, cardiac chamber and pulmonary artery for better understanding.

Conclusion: The present study concludes that the positive and linear relationship among haemoglobin level and CT HU value of Dural venous sinuses TOH >SSS is promising for prediction of haemoglobin level from unenhanced CT scan of the brain and thus anaemia.

References:

1. Iron-Deficiency Anemia | NHLBI, NIH [Internet]. Nhlbi.nih.gov. 2021 [cited 2 June 2021]. Available from: <https://www.nhlbi.nih.gov/health-topics/iron-deficiency-anemia>
2. [Internet]. 2021 [cited 12 June 2021]. Available from: http://www.rchiips.org/nfhs/nutrition_report_for_website_18sep09.pdf
3. Norman D, Price D, Boyd D, Fishman R, Newton T. Quantitative Aspects of Computed Tomography of the Blood and Cerebrospinal Fluid. *Radiology*. 1977;123(2):335-338.
4. Black D, Rad A, Gray L, Campeau N, Kallmes D. Cerebral Venous Sinus Density on Noncontrast CT Correlates with Hematocrit. *American Journal of Neuroradiology*. 2011;32(7):1354-1357.
5. Bruni S, Patafio F, Dufton J, Nolan R, Islam O. The Assessment of Anemia from Attenuation Values of Cranial Venous Drainage on Unenhanced Computed Tomography of the Head. *Canadian Association of Radiologists Journal*. 2013;64(1):46-50.
6. Pop M, Pop R, Bacarea A. A Multiparameter Model for the Correlation Between CT Hounsfield Unit and Blood Components. *Acta Medica Marisiensis*. 2016;62(2):230-233.
7. Parizel P, Makkat S, Van Miert E, Van Goethem J, van den Hauwe L, De Schepper A. Intracranial hemorrhage: principles of CT and MRI interpretation. *European Radiology*. 2001;11(9):1770-1783.
8. John F. Healy C. Polycythemia Mimicking Venous Sinus Thrombosis [Internet]. PubMed Central (PMC). 2021 [cited 12 June 2021]. Available from: <http://www.ncbi.nlm.nih.gov/pmc/articles/pmc7976237/>.
9. Fanous R, Leung A, Karlik S. Quantitative assessment of the superior sagittal sinus on unenhanced computed tomography. *European Journal of Radiology*. 2010;75(3):336-342.

Conflict of interest: None
Funding: None
Cite this Article as: Solanki V, Shah C, Shah B, Vadodariya B, Solanki A. Is There Any Correlation Between Computed Tomography (CT) Attenuation Value (Hounsfield Unit) Of Dural Venous Sinuses And Hemoglobin Level: A Prospective Observational Study. <i>Natl J Integr Res Med</i> 2021; Vol.12(3): 20-24