

A Comparative Study Of Efficacy Of Methyl Salicylate And Eugenol As Clearing Agent For Teeth Specimen

Shelvi Vachhani*, Shylaja Md**, Kiran Vachhani***, Kailash Attur***, Kamal Bagda****

*UG Student, **Professor And Head, Department Of Oral Pathology And Microbiology, ***Professor, ****Prof And Head, Department Of Conservative Dentistry And Endodontics, Faculty Of Dental Sciences, Narsinhbhai Patel Dental College And Hospital, Sankalchand Patel Univeristy, Visnagar 384315.

Abstract: Background: Diaphonization is a known method wherein the tooth model is made clear to visualize the root canal morphology. The method provides a 3D view of the root canal without much damage to the exterior of the tooth. Hence it is one of the preferred tools for teaching even till date. Material And Methods: 20 teeth were cleared to study the root canal morphology. They were divided into two groups and cleared with Methyl Salicylate and Eugenol. Cleared teeth were evaluated for transparency and haziness in the root canal. Result: Teeth cleared with Eugenol showed better transparency and less haziness as compared to Methyl salicylate. Conclusion: Diaphonized teeth models are still one of the preferred teaching aids for root canal morphologies. Eugenol is a better clearing agent than Methyl Salicylate. [Vachhani S Natl J Integr Res Med, 2020; 11(6):71-74]

Key Words: Methyl Salicylate, Eugenol, Clearing Agent, Teeth

Author for correspondence: Dr. Shylaja, MD, Professor And Head, Department Of Oral Pathology And Microbiology, Faculty Of Dental Sciences, Narsinhbhai Patel Dental College And Hospital, Sankalchand Patel Univeristy, Visnagar-384315 E-Mail: shylajamd@gmai.com Mobile: 9723563697

Introduction: Root canal morphology was comprehensively studied by Carabelli and his work was presented in the form of drawings of sectioned teeth in 1842. He studied internal as well as external morphologies of all the teeth.

Later the other methods of studying the canals included direct visualization or under microscope, intra-oral radiographs, dye penetration and clearing, filling and clearing, scanning electron microscopy¹ computed tomography, spiral computed tomography, cone-beam computed tomography (CBCT), and micro-computed tomography (micro-CT)².

Teeth clearing method is thought to be the best method of studying the internal anatomy of the teeth and the method is also known as diaphonization of teeth. Okumara was first to use the process of diaphonization to study root canal,¹ and later many researchers used the method which helped in the development of classification of root canals. The procedure was used for animal models initially and is not used now-adays because of fastidious and time consuming process.

The procedure was introduced in dentistry to study the morphology of root canal as an educational model. But advancement in newer imaging technology has made the procedure obsolete. But still in the field of academics and for patient education, the procedure still remains one of the best tool as it provides a three dimensional view of the pulp chambers and root

canal. Hence we studied two different solutions methyl Salicylate and Euginol for their effect as a clearing agent for the teeth specimen.

Material & Methods : The study included 20 teeth, extracted for reasons of orthodontics and periodontal diseases. Teeth with calcified canals, root resorption, or with any periapical pathology were excluded. The extracted teeth were washed well and kept in 10% formalin for 48 hrs and 1% Thymol for 24 hrs for disinfection. Access cavity was prepared and the canals were exposed. The patency of root canal was checked with No. 8 K file. Teeth were washed in running tap water for 15 min and taken for decalcification with 5% Nitric acid till the enamel was totally decalcified (daily for 5 days). Decalcification was checked by piercing lightly the crown of the teeth with a probe. The decalcified teeth were washed in running tap water for 2 hrs to remove all traces of acid.


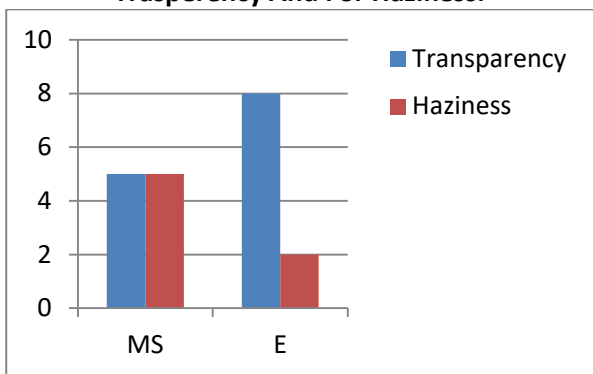
The teeth were dehydrated in graded isoprophyl alcohol. These teeth were divided in two groups of 10 each. Group I – the teeth were cleared in Methyl Salicylate (48 hrs). Group II – teeth were cleared in Eugenol (48 hrs).

After 48 hrs the teeth were checked for transparency after wiping with gauze dipped in methy salicylate and euginol respectively. Hematoxylin was added into the access cavity and the dye was allowed to flow into the root canals. The dye flows into the canals and exposes the 3D view of the root canal morphology.

The groups were compared for Transparency and Haziness: Transparency Criteria: whole of root canal visible- +positive, not visible- -negative Haziness Criteria: Present- +positive, Absent- -negative.

Results: Teeth cleared with Methyl Salicylate and with Eugenol were evaluated for transparency and for haziness. It was noted that the teeth that were cleared with Eugenol showed better transparency and had less haziness as compared to Methyl salicylate. It was also noted that Eugenol took less time for clearing than Methyl salicylate.

Figure 1. Teeth Cleared With Methyl Salicylate And With Eugenol Were Evaluated For Transparency And For Haziness.



Discussion: The first detailed description on root canal morphology of teeth was described by Carabelli in 1842 in form of drawings of sectioned teeth. Methods like cross sections also gave 3D view of internal anatomy of the tooth, but the morphology of the exterior of tooth was destroyed in the process³.

History of study of root canal morphology: Muhlreiter in 1870 was the first after Carabelli to study the internal anatomy of the teeth by sectioning them in all planes.

GV Black also studied the pulpal anatomy and described it in his book.¹ Sommer et al. sectioned teeth longitudinally to give a sagittal view of pulpal space from coronal portion to apex. Exposed canal was filled with the opaque wax but the method rarely showed lateral canals.

Rosenteil E reproduced root canal with radio-opaque material. In this technique, the 3D of pulp and depth was lost and only 2D was available as teaching aid. Barber et al. reproduced teeth in clear polished resin and filled pulpal spaces with red epoxy resin. This was first successful attempt of 3D view of the pulpal spaces. The method was extremely difficult to associate the pulpal spaces with the exterior of the tooth, and apical portion of tooth was obstructed by the mounting³.

Preiswreck in 1901 injected molten metal into the pulp chamber and obtained a 3D model by completely decalcifying the tooth. Hess et al in 1917 developed vulcanite replicas of the root canals and described the curvatures, anastomoses and intricate anatomies.¹

Diaphonization preserve the original form of the root canal to its minute detail. The specimen can also be preserved for a longer period of time.⁴ Till 1982, the diaphonization was used for anatomical studies of the pulp cavity. In 1983, Tagger et al. put forward an improved method with methyl salicylate as the clearing agent for 3D study on apical leakage.

The root canal system presents in multitude variety of shapes, configuration, and patterns that it is virtually impossible to completely debride. Diaphonization gives a 3D view of the pulp cavity, in relation to the exterior of the tooth. The form of the canal, even its minute structures, can be drawn clearly. Failures in the preparation of specimens are rare and the specimens can be preserved for a long time.

Literature suggests that diaphonization can be used to study the pulpal anatomy, instrumentation technique, micro leakage, analysis of broken instruments and perforations, homogeneity, and adaptation of Gutta-percha, effect of post design and its influence on root fracture, penetration of human saliva through dentinal tubules, sealer placement techniques in curved canals, quality of root canal obturation etc^{3, 5}. The process of making tooth transparent involves many physical and chemical changes:

creating an access cavity, washing the tooth with a cleaning solution, decalcifying (inorganic constituents of the tooth are dissolved), dehydrating (water, air and lipid components are removed) and finally immersing the tooth in clearing agent (tooth transparent by taking up its refractive index)^{4,5,6}. The preferred refractive index for clearing a tooth is 1.535⁷.

Various demineralising agents that can be used are: Nitric acid (5-11%), Formic acid (20%), Hydrochloric acid (5%), Solution of ion exchange resin and formic acid (40%)^{4,5,6}. Hydrochloric acid and Nitric acid are said to have faster action than the rest and nitric acid renders the tooth slightly yellowish. Formic acid sometimes show post-decalcification clogging of root canals³.

Dehydrating agents commonly used is alcohol (ethyl alcohol and isopropyl alcohol), magnesium sulfate, diatomaceous earth, calcium chloride, and silica gel (cat litter)⁷. Alcohol when used dissolves the blood clots inside the tooth and removes the blood from the canal. Sherwani et al used anhydrous calcium chloride [CaCl₂] and found it to be fast acting dehydrant². Non-alcohol dehydrating agent accomplishes two things: 1.

Alcohol is not present to break down any internal blood or pulpal remnants and 2. Provides an opportunity to allow air to replace any voids. Air injection into canal systems exposes the internal anatomy quite well and provides a nice contrast medium⁷.

Various clearing agents that can be used are Xylene, Benzene, Methyl salicylate, Eugenol, Casting resin. Each solution has its own advantages like Eugenol maintains the transparency of the tooth for the longest period of time outside the clearing agent, which serves its utility in imparting a longer working. Xylene is more corrosive in nature. Methyl salicylate tolerates more water and is non-noxious.^{5,6}

In the present study, we compared Methyl salicylate against Eugenol as a clearing agent and found that the transparency and haziness was less in eugenol as compared to methyl salicylate. The results were in conjunction with that of Shivapathsundaram et al. But few authors have found methyl salicylate as a better clearing agent. Shivapathasundharam et al.⁶ compared the efficacy of various clearing agents such as xylene, benzene, methyl salicylate, and eugenol. They

also tried suitable dye for the demonstration of root canal anatomy and compared the efficacy of various mounting media such as D.P.X. medium, Canada balsam, and commercial plastic dissolved in benzene, in preserving the cleared state. The results showed that eugenol is a superior clearing agent and that oil-based dyes are better suited for root canal demonstration⁶.

Clearing agents are volatile in nature hence once the transparent tooth is taken out of the clearing agent, the solvent evaporates, and the tooth is invaded by air and moisture again, hence opacity of sample is reversed. Time taken for tooth to become transparent in clearing agent is directly proportional to the time taken for it to become opaque, when it is out of clearing agent⁵.

There are certain limitations to this technique⁵ Clearing technique remains useful as a teaching and research tool with little or no clinical applicability. Incomplete dehydration will lead the teeth with opaque areas which can be corrected by additional dehydration in 100% ethyl alcohol. Development of opacity after air drying, which is readily reversible by immersion in clearing agent.

Conclusion: Diaphonization is an inexpensive and excellent technique for demonstration of 3D view of root canal morphology and is still one of the best teaching aids for undergraduate students. The result of the present study shows that Eugenol is a better clearing agent which gives better transparency and less haziness after the procedure and the model can be kept for longer time outside the clearing agent.

References:

1. Rehman K, Raza Khan F, Habib S. Diaphonization: A Recipe to study teeth. *J Contemp Dent Pract*; 2015; 16 (3): 248-251.
2. Sherwani OA, Kumar A, Tewari RK, Mishra SK, Tabassum S, Andrabi SM, et al. Root canal morphology of mandibular first molars in a North Indian subpopulation: An in vitro clearing study. *Saudi Endod J* 2017; 7: 156-60.
3. Gupta B, Tiwari B, Raj V, Kashyap B, Chandra S, Dwivedi N. Transparent tooth model: A study of root canal morphology using different reagents. *Eur J Gen Dent* 2014; 3: 66-70.
4. Robertson D, Leeb IJ, McKee M, Brewer E. A clearing technique for the study of root canal systems. *J Endod.* 1980; 6(1): 421-4.

5. Bansal R, Hegde S, Astekar M. Clearing Technique: Gateway to Demystifying Pulp Space Morphology. Acta Scientific Dental Sciences. 2019; 3(1): 65-68.
6. Shivapathasundharam B, Berti AE. Transparent tooth model system. An aid in the study of root canal anatomy. Indian J Dent Res. 2000; 11(3): 89-94.
7. Barrington C. Clearing a tooth to expose internal anatomy. Endodontic Practice US. 2015; March 16.

| |
|---|
| Conflict of interest: None |
| Funding: None |
| Cite this Article as: Vachhani S, Md S, Vachhani K, Attur K, Bagda K. A Comparative Study Of Efficacy Of Methyl Salicylate And Eugenol As Clearing Agent For Teeth Specimen. Natl J Integr Res Med 2019; Vol.10(6): 71-74 |