

## Anatomical Variation In Genitofemoral Nerve—A Cadaveric Study

Dr. Samir H. Ram\*, Dr. Jalpa N. Desai\*\*\*\*, Dr. Naimish R. Bhojak\*\*, Dr. Jitendra P. Patel\*\*\*

\*Tutor In Anatomy, \*\*Assistant Professor In Anatomy, \*\*\*Professor & Head Of Anatomy, Department Of Anatomy, Smt NHL Municipal Medical College, Ahmedabad, Gujarat, India,\*\*\*\*Assistant Professor, Department Of Anatomy, GCS Medical College, Hospital & Research Centre Ahmedabad, Gujarat, India

**Abstract:** Background: Variation in origin and branching pattern of genitofemoral nerve are common. These anatomical variations important for anatomists, clinicians, anesthetics and surgeons for avoid unexpected complication. Material And Method: 25 cadavers dissected in last 3 year. Result: in this study 20% cadavers found in genitofemoral nerve split near to the root L1-L2 while 4% cadavers found genitofemoral nerve derived from the root L2. Conclusion: In this study we found significant variation in genitofemoral nerve which is important for anatomists for academic purpose and also for surgeon to prevent iatrogenic nerve injury. [Ram S Natl J Integr Res Med, 2020; 11(5):28-30]

**Key Words:** lumbar plexus, root value, genitofemoral nerve

**Author for correspondence:** Dr. Jalpa N. Desai, A-62, Ashok Tenament, Opposite Cadila Lab. Ghodasar, Ahmedabad - 380050 E-Mail: drjalpa73@Yahoo.Com Mobile: 972435840

**Introduction:** A Variation in formation & branching pattern of genitofemoral nerve is reported by several authors. Knowledge of variation in GFN is important for anatomists for academic purpose and also practical importance for surgical intervention to prevent iatrogenic nerve injury.

Genitofemoral nerve is lies in posterior part of the substance of the psoas major muscle. It is a branch of lumbar plexus formed by ventral rami of the upper four lumbar nerves.

The genitofemoral nerve (L1-L2 Ventral divisions) emerges on the anterior surface of the psoas muscle near its medial border and runs downwards in front of the muscle. Near the deep inguinal ring it divides into femoral and genital branches. The femoral branch passes through the arterial compartment of the femoral sheath and is distributed to the skin of the upper part of the front of the thigh. The genital branch pierces the psoas sheath and enters the inguinal canal through the deep inguinal ring. In the male, it supplies the cremaster muscle, and in the female, it gives sensory branches to the round ligament of uterus and to the skin of the labium majus<sup>1,2</sup>.

The genitofemoral nerve can be injured with penetrating trauma, a knife wound or surgical exploration of the groin. genitofemoral may injured during varicose vein ligation by retractors and also be injured during inguinal hernia repair. Injury mostly diagnosed when patient start complaining pain postoperatively. In most cases, the injury is unnoticed during surgery and diagnosed in the post operative period when the patient complains of pain. the genitofemoral nerve can be injured during compression fracture, spinal stenosis of the L1 or L2 segments

or metastatic lesions to the lumbar spine the nerve roots. Irritation of nerve may occur in pelvic abscess, retroperitoneal hematoma and open pelvic fracture<sup>3</sup>. Variations in the regional anatomy of genitofemoral nerve might be a cause for radiculopathy following post abdominal hernial repair. Hence, a prior knowledge on the variations might be helpful in avoiding surgical trauma to the nerve<sup>4</sup>.

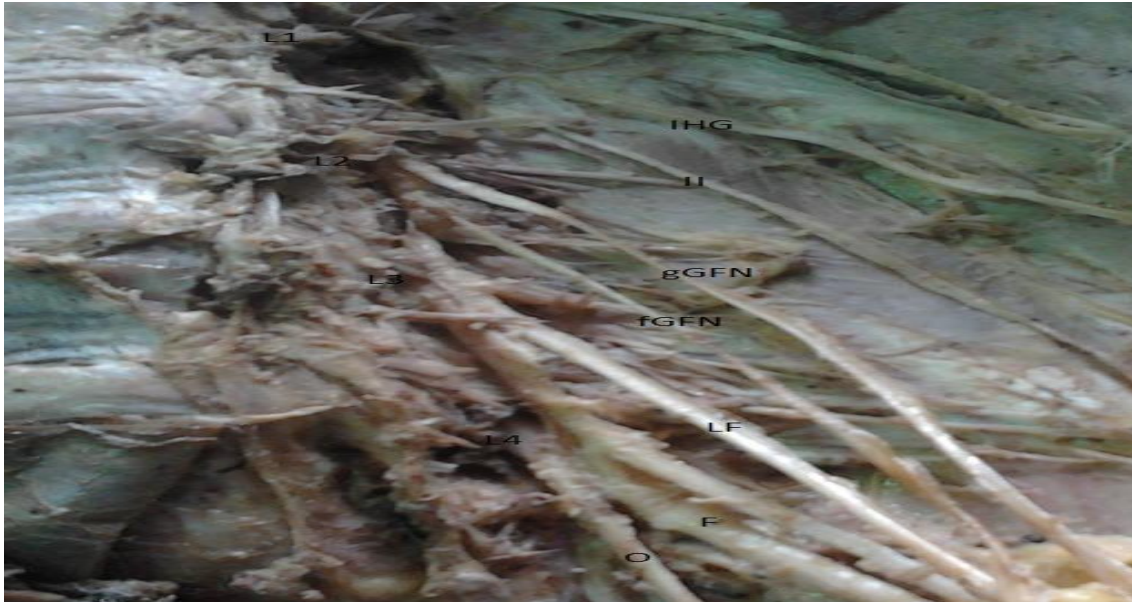
**Material & Methods:** 25 cadavers (50 lumbar plexus) out of 17 male and 8 were female dissected during academic work in smt NHL municipal medical college, Ahmedabad, Gujarat, India. Approval of ethical committee of NHL medical college was taken before to start this study. In which branches of lumbar plexus was observed. All cadavers were embalmed with 10% formalin. The dissection will be done according to the Cunningham's Manual of Practical Anatomy<sup>5</sup>.

After removing all content of abdomen and the fascia covering the muscle of posterior abdominal wall expose and clean the root of lumbar plexus of both sides and identify the branches. Genitofemoral nerve formation and course from the lumbar plexus will be traced and noted.. variation in formation and branching pattern of the recorded and photographed and compared with other literature and studies done by other authors.

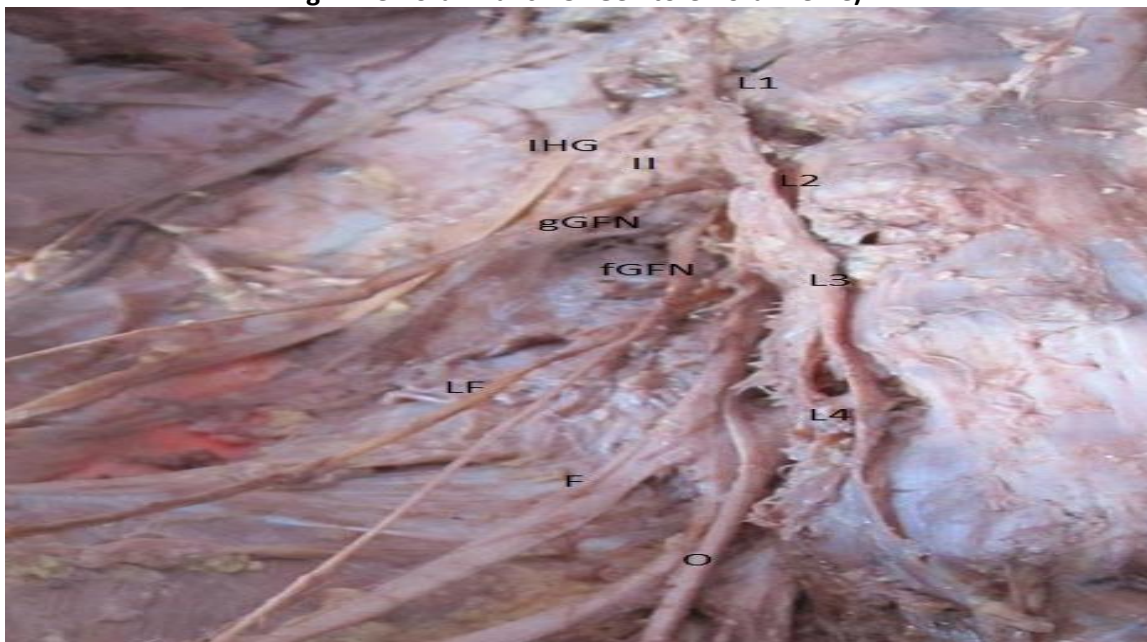
**Results:** The study was carried out on 25(17 male cadavers and 8female cadavers) human cadavers. Variation in branching pattern –Out of 25 cadavers, 20 cadavers in which 13 male & 7 female (80%) were found normal branching pattern bilaterally. While in 5 cadavers, 4 male & 1 female (20%) bilaterally

genitofemoral nerve split into genital and femoral branch near to the root as shown in fig-1. Variation in root value – In 24 cadavers (96%) genitofemoral nerve derived from L1-L2 bilaterally. While in one male cadaver (4%) genitofemoral nerve derived from the root L2 bilaterally (figure-2).

**Fig-1: Genitofemoral Nerve Split Into Genital And Femoral Branch Near To The Root. (L1-L2) (Ggfn- Genital Branch Of Genitofemoral Nerve, Fgfn- Femoral Branch Of Genitofemoral Nerve)**



**Fig-2: Genitofemoral Nerve Derived From The Root L2 (Ggfn- Genital Branch Of Genitofemoral Nerve, Fgfn- Femoral Branch Of Genitofemoral Nerve)**



**Discussion:** Maximum variation shown by Genitofemoral nerve both in its root value as well as its branching pattern within pelvic cavity. In past studies it observed that genitofemoral nerve has single root value first or second lumbar nerve but occasionally it may arise from third lumbar nerve and also arising from two roots (L1, L2 OR L2, L3)<sup>6</sup>. Gindha GS et al.<sup>7</sup> found 35 (58.33%) cases out of 60 cases were having the root value of L1 and L2. While 34 (56.67%) cases

in males out of 60 total cases were bilaterally in origin, while 1 case (1.67%) was unilaterally arising from L1 and L2 on right side. In females 3 cases (5.00%) on right side and 3 cases (5.00%) on left side were arising from the root value of L1 and L2. These cases were bilaterally present. 4 cases (2 cases 3.33% on right side, and 2 cases 3.33% on left side) in males were arising from the root value of L2 only. These were bilateral in origin. No such variation was found in female.

Fasila P et al.<sup>8</sup> found origin of genitofemoral nerve varied from L1 alone in one specimen, L2 and L3 in one specimen and rest all specimens i.e. 58 plexus showed normal root value L1-L2. The nerve showed an early split in 7 specimens out of which 5 plexus, both genital and femoral component arose from L2.

P. Nontasaenet al.<sup>9</sup> observed genitofemoral nerve derived from L1-L2 in 98.5% from L2 in 0.8% and L2-L3 in 0.8%. Denizet al.<sup>10</sup> observed genitofemoral nerve was originating from the ventral ramus of L2 on right side of a 35years old female cadaver. Bergman et al.<sup>11</sup> found that 75% genitofemoral nerve was derived from L1-L2. 5% from L2, 0.25% from L2 and L3. In the present study genitofemoral nerve derived from L1-L2 in 24 cadavers (96%) bilaterally while in one male cadaver (4%) nerve derived from L2 bilaterally. No any variation unilaterally. Anloague PA et al.<sup>12</sup> Observed that 16 of the 34 (47.1%) lumbar plexes demonstrated a variation of the genitofemoral nerve complex into its terminal genital and femoral branches midway along the anterior surface of the psoas major.

The most common variation occurred in 9 of 34 plexes (26.5%) and included a split of the genitofemoral nerve into the genital and femoral branches within the substance of the psoas muscle with fibers of the psoas major passing between these branches. In the present study 5 cadavers, 4 male & 1 female (20%) bilaterally genitofemoral nerve split into genital and femoral branch near to the root.

**Conclusion:** Lumbar plexus and its branches important for every anatomist for dissection and also for surgeon who need to explore lower abdomen region and surgery for repair of the inguinal hernia. In present study of variation found in genitofemoral nerve help the clinician to treat patient and surgeon to prevent iatrogenic injuries so they prevent postoperative complication like neuralgia.

#### References:

1. B.D.Chaurasia's text book of Human Anatomy (Lower limb & Abdomen) vol 2, 6<sup>th</sup> edition page 343
2. Stanring S. Gray's Anatomy: The Anatomical Basis of Clinical Practice. Chapter posterior abdominal wall, lumbar plexus. 40th ed. London: Churchill Livingstone Elsevier; 2011. p. 1978–1080.

3. Marco Gupton; Matthew Varacallo Anatomy, Abdomen and Pelvis, Genitofemoral Nerve[Update 2020 Aug.11] In:statpearls . Treasure Island(FL) publishing Jan 2020
4. Fasila P. Assis & Priya Ranganath., A Human Cadaveric Study on Variations in Formation and Branching Pattern of Lumbar Plexus with Its Clinical Implications Scholars Journal of Applied Medical Sciences . 2018; 6(1A): 58-63
5. Romanes GJ. Cunningham's Manual of Practical Anatomy, posterior abdominal wall, lumbar plexus. 5th ed. New York: Oxford University Press; 2013;2:182–186.
6. Bergman RA, Afifi AK, Miyauchi R: Variations of connections between lumbar and sacral plexuses. In illustrated encyclopedia of human anatomic variation: Part III: Nervous System: Plexuses, University of Iowa. (Electronic Publication), 2001
7. Gindha GS, Arora D, Kaushal S, Chhabra U .Variations in Origin of the Genitofemoral Nerve from the Lumbar Plexuses in North Indian Population (A Cadaveric Study). MOJ AnatPhysiol, 2015; 1 (3): 1-5
8. Fasila P. Assis, PriyaRanganath. A Human Cadaveric Study on Variations in Formation and Branching Pattern of Lumbar Plexus with Its Clinical Implications. Sch. J. App. Med. Sci., Jan 2018; 6(1A): 58-63
9. P.Nontasaen, Sirjit Das. A cadaveric study of the anatomical variations of the lumbar plexus with clinical implications. Journal of the anatomical society of india 65(2016) 24-28
10. Deniz U, Mustafa A, Alev K. Multiple variations of the nerves arising from the lumbar plexus. Neuroanatomy. 2006;5:37–39.
11. Bergman RA, Afifi AK, Miyauchi R. External structure of genitofemoral nerve in post fetal life in man Folia Morphol. Warsaw; 1975;34:425–435.
12. Anloague PA, Hujibregts P. Anatomical variations of the lumbar plexus: a descriptive anatomy study with proposed clinical implications. J Man Manip, 2009;17(4):107-14.

Conflict of interest: None
Funding: None
Cite this Article as: Ram S, Desai J, Bhojak N, Patel J. Anatomical Variation In Genitofemoral Nerve—A Cadaveric Study. Natl J Integr Res Med 2020; Vol.11(5): 28-30