

Does Orthopantomograph Helps In Evaluating Bone Density After Placement Of Demineralized Dentin Graft?

Dr. Jigar M. Dhuvad*, Dr Deval Mehta**, Dr Sonal Anchlia***

*Assistant Professor, **Dean, Professor and Head, ,***Professor and Head,

Department of oral and maxillofacial surgery, Government Dental College and Hospital, Asarwa, Gujarat University, Ahmedabad.

Abstract: Background: Subsequent to tooth extraction a physiological phenomenon takes place with alveolar resorption and results in decreasing ridge volume and ridge contours. Therefore, preservation of 3-dimensional alveolar bone contour is mandatory with placement of graft and follow-up is essential to authenticate the subsequent formation of bone within the socket. Aim and Objective: The aim of this paper was to discuss a technique in detail for radiographic evaluation of bone formation by measuring bone density of autogenous dentin demineralized (Auto DDM) graft prepared for alveolar bone grafting immediately after dental extractions and review the literature on "Bone Density and Demineralised Dentin Graft" online PubMed database. Material And Methods: A systematic search of the literature was carried out relevant to oral and maxillofacial surgery in online data-base of the United States National Library of Medicine. Evaluation of bone density was refined with the help of standardized digital radiographs, Orthopantomograph (OPG), at immediate after extraction and placement of DDM graft, 1 month, 3months, and 6 months follow-up. Result: OPG showed favorable bony healing with excellent bone formation, which can be appreciated on measuring bone densities. Conclusion: We conclude that the availability of DDM grafts would have a strong positive effect on the clinical use of the tooth as a bone graft material in oral surgery. Further studies should be performed to confirm the osteogenic effects and biological safety of this DDM graft material. [Dhuvad J Natl J Integr Res Med, 2019; 10(6):66-71]

Key Words: Bone Density, Demineralized Dentin graft, Orthopantomograph, Dental extraction, Autogenous graft.

Author for correspondence: Dr. Jigar M Dhuvad, Assistant Professor, Department of oral and maxillofacial surgery, College of Dental Science and Research Centre, Gujarat University, Ahmedabad
Email: drjigardhuvad1981@gmail.com, Mo: 9879596740

Introduction: Subsequent to tooth extraction, a physiological phenomenon takes place with alveolar resorption and the subsequent formation of bone within the socket. ¹ During natural healing after tooth extraction, reductions in width 2.6 - 4.6 mm and in height 0.4 - 3.9 mm were observed, studies also have documented that the bone volume following extractions decreased by 50% within 12 months, and 2/3 of this resorption took place during the first 3 months. ²⁻⁴

This bone resorption results in decreasing ridge volume and deforming the ridge contours, which consequently results in narrowing and atrophy of the native alveolar ridge contour. ^{5, 6} Therefore, preservation of 3-dimensional alveolar bone contour is obligatory after extraction and which can be confirmed by the measuring the formation of a bone into extraction sockets.

The aim of this paper was to discuss a technique in detail for radiographic evaluation of bone formation by measuring bone density of autogenous dentin demineralized (Auto DDM) graft prepared for alveolar bone grafting immediately after dental extractions and review the literature on "Bone Density and Demineralised Dentin Graft" online PubMed database.

Material & Methods : A systematic search of the literature was carried out to identify the eligible articles at our institution in a period from September 2016 to December 2018. The existing literature through the term "Bone Density and Demineralised Dentin Graft" relevant to oral and maxillofacial surgery in online data-base of the United States National Library of Medicine: Pubmed(<http://www.ncbi.nlm.nih.gov/pubmed/>) was searched. Authors are also discussing a technique in detail for radiographic evaluation of bone formation by measuring bone density of Auto DDM graft prepared for alveolar bone grafting immediately after dental extractions. Teeth without root canal fillings that require extraction due to advanced periodontal bone loss or other indications like prosthodontic or orthodontics indications can only be treated with the following mentioned technique.

Procedure from tooth extraction to grafting of particulate dentin: Patient was made to gargle with 0.1% chlorhexidine solution right before extraction and also after every meal for 10 days following surgery. During extraction, extreme care was shown to preserve the surrounding bone and soft tissue. Sockets were debrided and rinsed with

saline. Subsequent cleaned tooth extraction, root surface was cleaned carefully from periodontal tissue. All carious lesions, restorations like crowns and fillings, discolored dentin and calculus, if any, were removed.

The pulp tissue from the root canal(s) was removed using a root canal instruments. Layers of enamel and cementum were also removed. The teeth were washed with sterile normal saline. Subsequently, the clean and dry tooth, dentin, were immediately grinded with a specially designed 'mortar and pestle' (0.5-1mm), and then dentin particles were immersed in basic alcohol for 10 minutes in a sterile glass container for defatting, dissolving all organic debris, bacteria and toxins of the dentin particulate. The basic alcohol cleanser consisted of 0.5M of NaOH and 30% alcohol (v/v). After decanting the basic alcohol cleanser, the particulate was washed thrice, in sterile phosphate buffered saline (PBS). The PBS was decanted leaving wet particulate dentin ready to graft into freshly extracted sockets. The graft was carefully inserted into alveolar socket and the wound was closed primarily with 3-0 black braided silk.

Bone density measurement: Osseous regeneration was evaluated with the help of standardized digital OPG at immediate after extraction and placement of graft, 1 month, 3months, and 6 months follow-up. The panorama photos, digitized as DICOM files, were converted into JPEG graphic files, and the JPEGs were stored.

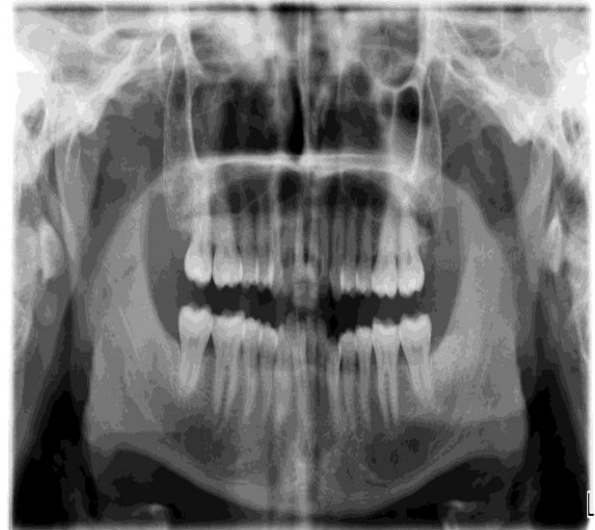
Standard Measurement Procedure: First open the Adobe Photoshop → Import the image → Placement of Cursor in the Area of Interest (AOI).

1. From View option → open a New Guide option → Draw two vertical and two horizontal orientation lines in the AOI in the extraction socket by a 2*2 square mm for molars and 1*1 square mm for premolars and adjacent bone respectively.
2. From Windows option select Histogram option → Take cursor into AOI → Measure the bone density of the AOI in the form of mean, standard deviation, and median.
3. AOI was created for the defect region and one for the adjacent bone using the following rules:
 - a) For each bone defect AOIs must be created for the defect and the adjacent bone on the same radiograph.
 - b) The size of the adjacent bone must be similar to the size of the extraction defect.

- c) The AOI of the defect must enclose the whole radiologic distinguishable part of the defect.
- d) The surrounding bone must be selected by avoiding the following anatomic structures:
 - Mandibular canal
 - Cortical plates of mandible or maxilla
 - Radiological overlay of maxillary sinus
 - Surrounding teeth or implants
4. If one of these rules could not be used properly, the image has to be locked out of the analysis.
5. The results were summarized in a Microsoft Excel worksheet [Microsoft Excel 2013, Microsoft corp., USA] and comparison was done. All the measurements and surgical procedure was performed by a single operating surgeon.

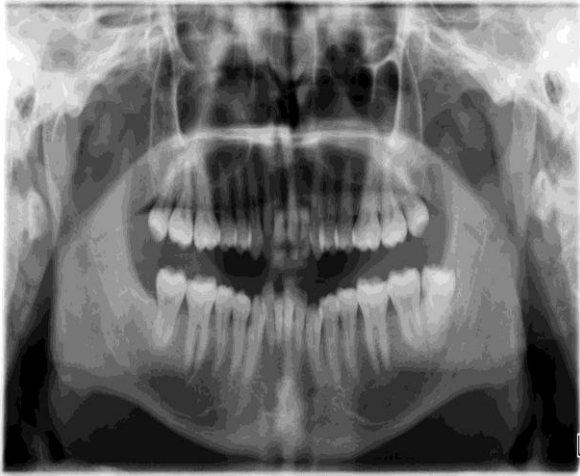
Case Presentation: A 35 year old male patient came with a complaint of pain in upper and lower left posterior last tooth since more than 15 days. After proper history and clinical examination, patient underwent radiographic evaluation i.e. OPG. Clinically there was a cheek bite and OPG showed buccally placed carious 28 and distoangular 38. [Figure1]

Figure 1: OPG showing carious 28 and distoangular 38



He was informed and treated for wisdom tooth extraction followed by placement of demineralized dentin graft. [Figure 2]

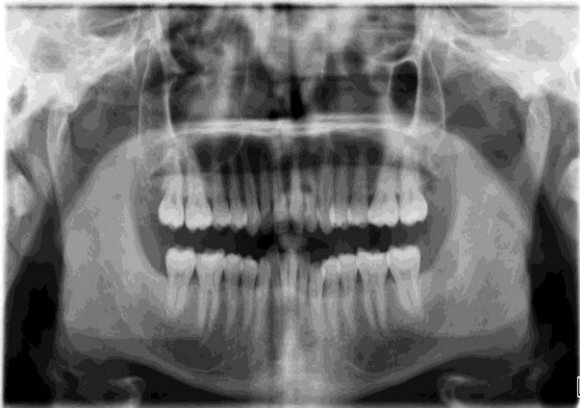Figure 2: Placement of demineralized dentin Graft



He received antibiotics perioperatively and for 7 days post-surgery (Amoxycillin + Clavulanic Acid 625mg 1-1-1) along with Piroxicam (NSAIDs) 10mg two times a day for 3 days and later on as per requirement.

Results : Six articles were found with the search terms “Bone Density and Demineralised Dentin Graft” in the online Pubmed database.⁷⁻¹² The relevant data was extracted and tabulated [Table 1]The healing of the post-extraction wound was uneventful. On follow-up no signs of microbial infection, exudation, or dehiscence of the wound were observed clinically. OPGs just immediately after placement of graft revealed radiopaque particles covering fully inside the socket including a sharp radiopaque line of lamina dura. [Figure 3]

Figure 3: Sharp radiopaque line of lamina dura



At 1, 3 and 6 months of the follow-up, the alveolar socket appeared to be filled with uniform radiodense bone like tissue indicated that the socket healed fully with new bone. In addition, lamina dura of the socket disappeared completely by bone remodeling. Gradual absorption of the demineralised granules was observed on the sequential radiographic findings of the socket [Figure 4] and [Figure 5].

Figure 4: Sequential radiographic findings of the socket

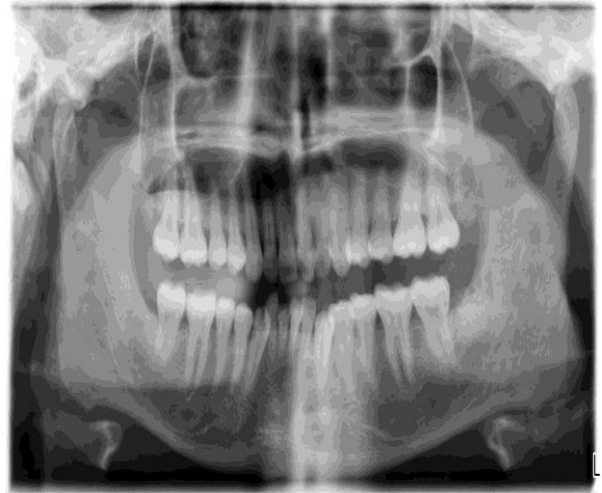
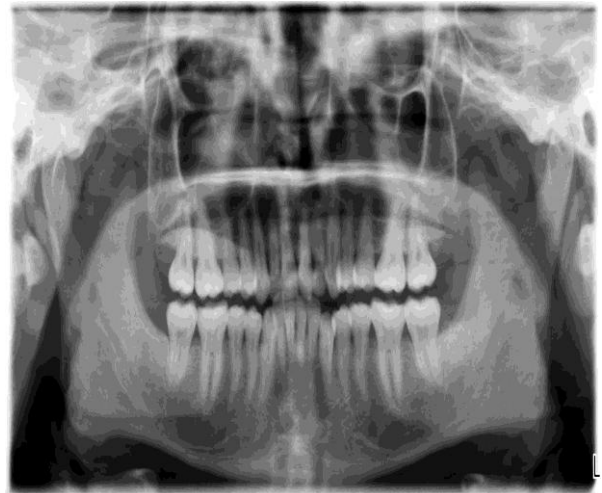
Figure 5: Sequential radiographic findings of the socket



Discussion: In clinical practice, digitally processed radiographic images are the common way to examine and evaluate pathology in the jaw bones. After surgical treatment, with or without augmentative procedures, radiographic follow-up is mandatory by the operating surgeons, as well.¹³

Apurva Vohra found that the measurements of density of the extraction socket revealed that bone deposition was at faster rate in extraction socket with graft placement as compared to control site.¹⁴ Kattimani VS, et al. evaluated the efficacy of eggshell derived hydroxyapatite (EHA) in the bone regeneration of human maxillary cystic bone defects secondary to cystic removal or apicoectomy and evaluated that by the end of the 8th week, the defects grafted with EHA showed absolute bone formation.¹⁵

Similarly Khalid I, et al. and Panday V, et al. also scanned OPG by using computer- assisted

densitometric image analysis software and showed additional density on the graft site.^{16, 17} Bould M, et al. assessed the precision and reproducibility of a digital image analyser and the human eye, in measuring radiographic dimensions and concluded that digital image analysis system is up to 20 times more precise than the human eye.¹⁸ The other radiological imaging technologies and methods used for quantification of bone healing are dual energy Xray absorptiometry, single energy X-ray absorptiometry, radiographic absorptometry, and quantitative computed tomography. However, these techniques are costly and have more radiation hazards.¹⁹ Proportional study has been conducted between digital and conventional dental panoramic images by Akmal Sabarudin and Yu Jin Tiau and instituted that images produced by digital panoramic system were superior in diagnostic image quality than that from conventional.²⁰

Digital visualization has also improved the diagnostic quality significantly in terms of radiographic density and contrast. Application of digital panoramic images is mushrooming due to its remuneration such as fast communication of images, small storage space required, minimum contamination to the environment and providing optimal diagnostic images with low radiation dose when compared to the conventional technique.²¹⁻²³ It has been reported that radiation dose in digital panoramic imaging is 5-14 μ Sv which is significantly lower than that of conventional panoramic imaging, which is 16-21 μ Sv.²⁴

Regarding digitally processed radiographic images, measurements of grey value is a simple feature of most graphic analysis software. The grey values are related to the absorption of x-rays, the radiologic density of a certain tissue. The grey values are saved in an 8-bit colour space. Every pixel obtains a value from 0 - 255 in which 0 stands for black, low radiologic density while 255 for white, total x-ray absorption.^{25, 26} Chiapasco et al, analyzed the evolution of mean grey values of bone defects resulting from cystectomy of large mandibular cysts. They used conventional radiographic images, digitalized with a scanner and used the grey values of a healthy tooth as a reference.²⁷

If measurements of mean grey values are used to assess the outcome of bone healing after surgical treatment, a parameter of reference is very important to allow comparison of measurements

on different radiographs. Ihan Hren and Miljavec used the surrounding bone as reference in their relative bone density measurements. Compared with other references used by different authors like teeth and metal markers, the recompense of this procedure is that there are no costs and it allows retrospective analysis of bone healing using radiographs which might have not been especially taken for scientific research.²⁸

Teeth could lose its reference ability by decay or dental treatment. Measurement of bone density is a quick, easy, economical parameter and also a close to practice tool which could have various possible uses in oral and maxillofacial surgery as well as in the evaluation of endodontic or periodontic treatment. Nevertheless, the user has to keep in mind that there could be other causes for a change in mean grey values such as sclerosing fibrosis, mineralized tumors, or the introduction of radiopaque foreign material into the bone defect such as bone substitutes or own bone transplantation. There could only be considered relative changes in bone density compared with surrounding bone.

In our study, immediately after tooth extraction till tooth preparation, demineralisation, washing and shifting of a graft into sterile container takes approximately 18-20 minutes. A follow-up of 6 months revealed a gradual absorption of DDM granules and remodelled into new bone formation in the OPG in the illustrated case of impacted tooth presence, its removal and on follow-up when checked bone density. Moreover, as supporting data, implant success evaluations might be added as the ongoing part of the study.

Limitations: Some limitations exist in the study. Firstly, the absence of a histological evaluation of newly formed tissues. Secondly, measurements of the absolute mineral density could not be realized with this method. Thirdly, operative procedure and evaluation of radiographic bone density was completed by single operator dependent. Therefore, results might influence the findings. However, avoiding the uncertainty can be achievable if using one operator to prepare the image for evaluation. Such an examination might have provided relatively more objective results that might explain the similarity of the outcomes in treated and empty left sockets.

Conclusion: The use of autografts prepared at the chair side as bone graft material on the day of

tooth extraction can be suitable for both patients and clinicians. Within the limitations of this study, the results indicate that DDM grafts prepared within 20 minutes from tooth can effectively restore alveolar bone defects in humans. We conclude that the availability of autografts would have a strong positive effect on the clinical use of the tooth as a bone graft material in implant surgery. Further studies should be performed to confirm the osteogenic effects and biological safety of this tooth-based graft material.

References:

1. Kabir MA, Murata M, Kusano K, Akazawa T, Shibata T. Autogenous Demineralized Dentin Graft for Third Molar Socket Regeneration - A Case Report. *Dentistry* 2015;5: 343.
2. Ten Heggeler JMAG, Slot DE, Van der Wijden GA. Effect of socket preservation therapies following tooth extraction in non-molar regions in humans: a systematic review. *Clin Oral Implants Res* 2011; 23:779 -788.
3. Schropp L, Wenzel A, Kostopoulos L, Karring T. Bone healing and soft tissue contour changes following single-tooth extraction: a clinical and radiographic 12-month prospective study. *Int J Periodontics Restorative Dent* 2003; 23: 313-323.
4. Van der Weijden F, Dell'Acqua F, Slot DE. Alveolar bone dimensional changes of post-extraction sockets in humans: a systematic review. *J Clin Periodontol* 2009; 36: 1048-1058.
5. Atwood DA, Coy WA. Clinical, cephalometric and densitometric study of reduction of residual ridges. *J Prosthet Dent* 1971; 26: 280-295.
6. Watt DM, Likeman PR. Morphological changes in the denture bearing area following the extraction of maxillary teeth. *Br Dent J* 1974; 136: 225-235.
7. Kamal M, Andersson L, Tolba R, Al-Asfour A, Bartella AK, Gremse F, Rosenhain S, Hölzle F, Kessler P, Lethaus B. Bone regeneration using composite non-demineralized xenogenic dentin with beta-tricalcium phosphate in experimental alveolar cleft repair in a rabbit model. *J Transl Med.* 2017; 15(1):263.
8. Park SM, Kim DH, Pang EK. Bone formation of demineralized human dentin block graft with different demineralization time: In vitro and in vivo study. *J Craniomaxillofac Surg.* 2017; 45(6):903-912.
9. Cavdar FH, Keceli HG, Hatipoglu H, Demiralp B, Caglayan F. Evaluation of Extraction Site Dimensions and Density Using Computed Tomography Treated With Different Graft Materials: A Preliminary Study. *Implant Dent.* 2017; 26(2):270-274.
10. Nam JW, Kim MY, Han SJ. Cranial bone regeneration according to different particle sizes and densities of demineralized dentin matrix in the rabbit model. *Maxillofac Plast Reconstr Surg.* 2016; 38(1):27.
11. Bakhshalian N, Hooshmand S, Campbell SC, Kim JS, Brummel-Smith K, Arjmandi BH. Biocompatibility and microstructural analysis of osteopromotive property of allogenic demineralized dentin matrix. *Int J Oral Maxillofac Implants.* 2013; 28(6):1655-62.
12. Beertsen W, van den Bos T, Niehof J. Mineralization of dentinal collagen sheets complexed with alkaline phosphatase and integration with newly formed bone following subperiosteal implantation over osseous defects in rat calvaria. *Bone Miner.* 1993; 20(1):41-55.
13. Sitzmann F. Wann sind zur Sicherung von Diagnose und Therapie Röntgenaufnahmen nötig? Stellungnahme der DGZMK 2/93 V 1.0, Stand 12/92. Published by: DGZMK 1993.
14. Vohra A. Radiological measurement of bone density to assess the efficiency of bone graft. *IAIM*, 2016; 3(2): 88-91.
15. Kattimani VS, Chakravarthi PS, Kanumuru NR, Subbarao VV, Sidharthan A, Kumar TS, Prasad LK. Eggshell derived hydroxyapatite as bone graft substitute in the healing of maxillary cystic bone defects: A preliminary report. *J Int Oral Health*, 2014; 6(3): 15-9.
16. Khalid I, Kumar DSY, Rao S. Use of computer-assisted densitometric image analysis (CADIA) in assessing bone density changes in extraction socket. *Indian J Stomatol.*, 2011; 2(3): 168-71.
17. Panday V, Upadhyaya V, Berwal V, et al. Comparative Evaluation of G bone (Hydroxyapatite) and G-Graft (Hydroxyapatite with Collagen) as Bone Graft Material in Mandibular III Molar Extraction Socket. *Journal of Clinical and Diagnostic Research* 2015; 9(3): ZC48-ZC52.
18. Bould M, Barnard S, Learmonth ID, Cunningham JL, Hardy JR. Digital image analysis: improving accuracy and reproducibility of radiographic measurement. *Clin Biomech.*, 1999; 14(6): 434-7.
19. Babatunde OM, Fragomen AT, Rozbruc RS. Noninvasive quantitative assessment of bone

- healing after distraction osteogenesis. HSS Journal, 2010; 6(1): 71-8.
20. Sabarudin A, Tiau YJ. Image quality assessment in panoramic dental radiography: a comparative study between conventional and digital systems. Quant Imaging Med Surg 2013; 3(1):43-48.
 21. Molander B, Gröndahl HG, Ekestubbe A. Quality of film-based and digital panoramic radiography. Dentomaxillofac Radiol 2004; 33:32-6.
 22. Visser H, Rödiger T, Hermann KP. Dose reduction by direct-digital cephalometric radiography. Angle Orthod 2001; 71:159-63.
 23. Yalcinkaya S, Künzel A, Willers R, et al. Subjective image quality of digitally filtered radiographs acquired by the Durr Vistascan system compared with conventional radiographs. Oral Surg Oral Med Oral Pathol Oral Radiol Endod 2006; 101:643-51.
 24. Visser H, Hermann KP, Bredemeier S, et al. Dose measurements comparing conventional and digital panoramic radiography. Mund Kiefer Gesichtschir 2000; 4:213-6.
 25. Yasar F, Apaydin B, Yilmaz HH. The effects of image compression on quantitative measurements of digital panoramic radiographs. Med Oral Patol Oral Cir Bucal. 2012; 1074-1081.
 26. Geiger M, Blem G, Ludwig A. Evaluation of ImageJ for Relative Bone Density Measurement and Clinical Application. J Oral Health Craniofac Sci. 2016; 1: 012-021.
 27. Chiapasco M, Rossi A, Motta JJ, Crescentini M. Spontaneous bone regeneration after enucleation of large mandibular cysts: a radiographic computed analysis of 27 consecutive cases. J Oral Maxillofac Surg. 2000; 942-948.
 28. Ihan Hren N, Miljavec M. Spontaneous bone healing of the large bone defects in the mandible. Int J Oral Maxillofac Surg. 2008; 1111-1116.

Conflict of interest: None
Funding: None
Cite this Article as: Jigar D, Deval M, Sonal A. Does Orthopantomograph Helps In Evaluating Bone Density After Placement Of Demineralized Dentin Graft? Natl J Integr Res Med 2019; Vol.10(6): 66-71