

Coronary Artery Dominance In North Indian Population by The Angiographic Method.

Vishram Singh*, **Suresh Babu Kottapalli****, **Rakesh Gupta*****, **Nitin Agarwal******, **Yogesh Yadav*******

*Former Prof. & HOD Dept. of Anatomy, **Ph.D. Scholar, Dept. of Anatomy, *****Prof. Dept. of Anatomy Santosh Medical College, Santosh Deemed to be University, Ghaziabad, Delhi NCR., *** Professor & HOD, Department of Anatomy, ****Assistant Professor, Department of Medicine, RMCH, Bareilly, U.P, India.,

Abstract: Background: The rise in coronary heart disease in India has led to a rapid transition in health status. In rural areas, prevalence of coronary artery disease was estimated as 3-4% and 8-10 % in urban areas in the age group of above 20 years. This represents 2 fold rise in rural areas and 6 fold rise in urban areas when compared to past 40 years. Coronary circulation was classified as right , left, and co-dominant. It has clinical importance. It is believed that the persons with left coronary artery dominance is associated with poor prognosis with coronary artery disease and acute coronary syndrome. Method: A total of two hundred and fifteen patients who have undergone angiography were included in this study. Results: One hundred and fifty-six (73%) were male and fifty-three (27%) were female. Right coronary artery was dominant in 184, left dominant in 23 (10.70%) and co-dominant in 8 (3.72%) of the patient population. Among a total of 215 patients, 54 (25.12%) were smokers, 67(31.16%) patients had Pre-hypertension, 42 (19.53%) had Pre-diabetes, and 18 (8.37%) had Dyslipidemia. Conclusions: The right coronary dominant pattern in coronary artery circulation is more prevalent in our population than left coronary dominance and co-dominance patterns. This study would be useful to the surgeons, cardiologists and radiologists of this region. [Singh V Natl J Integr Res Med, 2019; 10(4):70-72]

Keywords: Coronary dominance, myocardial infarction, coronary artery disease

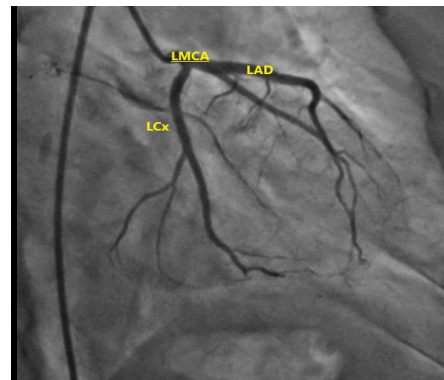
Author for correspondence: Suresh Babu Kottapalli, Ph.D. Scholar, Dept. of Anatomy, Santosh Medical College, Ghaziabad, Delhi NCR.E Mail: ksureshbraju1986@gmail.com, M: 9701842713

Introduction In developing countries like India, Coronary artery disease is one of the major reasons for death. The rise in coronary heart disease in India has led to a rapid transition in health status. The estimated prevalence of coronary artery disease is around 3 to 4% in rural areas and 8 to 10% in urban areas among adults older than 20 years which representing a twofold rise in rural areas and a six-fold rise in urban areas over the past 40 years¹

Coronary circulation was classified as right coronary artery dominance(RD), left coronary artery dominance(LD), and co-dominant(CD)². The dominant vessel supplies posterior descending artery (PDA) and at least one posterolateral branch. In 85% of population, right coronary artery (RCA) is dominant. In fifteen percent, the RCA is non-dominant in which half have PDA and posterolateral branch which arising from the distal circumflex artery i.e. left dominance, the remaining half of the right coronary artery gives rise to PDA and the left circumflex artery (LCx) provides all the posterolateral branches called codominant circulation³ (Figure 1 -3).

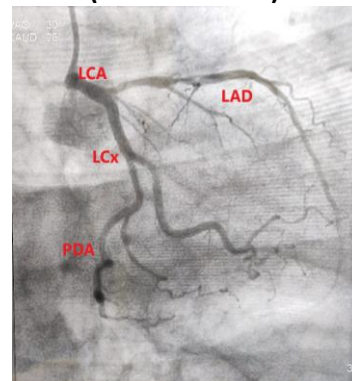
Clinically, the dominance pattern of the heart has an important role. The Left dominant anatomy is believed to be associated with worse prognoses

Figure 1: Normal Left Coronary Artery Showing Its Main Branches



LMCA – Left Main Coronary Artery, LAD – Left Anterior Descending Artery, LCx – Left Circumflex Artery

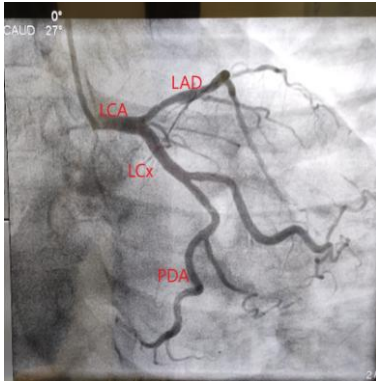
Figure 2: Showing Left Dominance (PDA From LCX)



PDA – Posterior Descending Artery for patients with the ACS and stable coronary artery disease ^{4, 5}. Left dominance have significantly higher mortality than RD and mixed

types⁶ Information about variations of coronary arteries and pathologies is important in planning the treatment and in the interpretation of findings of cardiovascular diseases⁷.

Figure 3: Showing Left Dominance



The information regarding the dominant pattern of coronary circulation in North India is scanty. Hence, we carried out this study to determine the pattern of coronary artery dominance in our North Indian population.

Materials and Methods: After getting Institutional ethics committee clearance, this study was carried out at our institute during the period of 15 months from 2017 to 2018. Written informed consent was obtained from all the participants.

All patients of either gender of 18 - 35 years of age, eligible to undergo coronary angiography were recruited for this study. If they have known valvular heart disease, congenital heart disease, hypertrophic cardiomyopathy, showing anomalies in coronary arteries, proximal occlusion and patients who were going for preoperative coronary angiographic for cardiothoracic surgery were excluded in this study. 215 patients were enrolled in the study. Sociodemographic profile of participants, pattern of coronary artery dominance, an association of CAD with coronary artery dominance were recorded. Standard views were acquired during coronary angiography with special focus on left anterior oblique cranial view to document left the dominant system.

Statistical analysis was carried out by using R for windows. To calculate the frequencies, percentages, means and standard deviation, descriptive statistics were used. Age and other numerical data were expressed as Mean \pm

Standard deviation while the categorical data were expressed as frequency and percentages.

Results & Discussion: A total of two hundred and fifteen patients who have undergone were included in this study. One hundred and fifty-six (73%) were male and fifty-three (27%) were female (Fig2). Right coronary artery was dominant in 184 (85.58%), left dominant in 23 (10.70%) and co-dominant in 8 (3.72%) of the patient population (Table 1). Among a total of 215 patients, 54 (25.12%) were smokers, 67(31.16%) patients had Prehypertension, 42 (19.53%) had Prediabetes, and 18 (8.37%) had Dyslipidemia. (Table 2).

Table 1: Distribution of coronary dominance

Dominant artery	Count	Percentage
Right dominance	184	85.58 %
Left dominance	25	11.63 %
Codominance	6	2.79 %

Table 2: Cardiovascular risk factors

Risk factor	Number	Percentage
Smoking	54	25.12%
Pre Hypertension	67	31.16%
Pre Diabetes	42	19.53%
Dyslipidemia	18	8.37%

In our study, 85.58% had RCA dominance, 11.63% had LCx dominance and 2.79% had codominant coronary circulation. It was reported that the extent of coronary atherosclerosis does not depend on the type of dominant coronary artery⁸ but in ACS patients, left dominance will be a significant and independent predictor of high long-term mortality⁹.

Further, the origin of the SA nodal artery is not related to coronary arterial dominance, but the origin of the AV nodal artery is also dependent on coronary artery dominance¹⁰. The coronary dominance is related to myocardial bridging, particularly in the left coronary circulation¹¹.

In different communities, the pattern of coronary artery dominance is varied in different communities. In a report by Altai et al, 83% of RD, 14.5% of LD was observed and CD was seen in 2.5%¹². In Kenya, the prevalence of RD was 82%¹³. The most prevalent pattern was RD, followed by CD and LD in the Brazilian population also⁸.

Another study in Italy have reported the coronary dominance pattern results were: right, 86.6%; left, 9.2%; balanced, 4.2%¹³. Another report in Jalgaon region of North Maharashtra, India, the pattern of coronary dominance was 82.4% RD, 13.3% LD and 4.3% CD¹⁴. Similarly, in another study done in Assam (India), the pattern was found to be 70% RD, 19% LD, and 11% CD¹⁵. From the above studies, RD is more prevalent which is following our findings

Conclusions: In this study, the prevalence of right coronary dominant pattern is more in North Indian population than the left and co-dominant ones. According to previous studies, the mortality rate was higher in left dominant and co-dominant than right dominant in the prevalence of myocardial infarction. This study would be useful for radiologists, cardiologists, and surgeons of this region.

References :

1. Srinath Reddy K, Shah B, Varghese C, Ramadoss A. Responding to the threat of chronic diseases in India. *Lancet*. 2005 Nov 12;366(9498):1744–9.
2. Gawlikowska-Sroka A, Miklaszewska D, Czerwiński F. *Folia Morphol(Warsz)*. Analysis of the influence of heart size and gender on coronary circulation type. 2010 Feb;69(1):35-41.
3. Libby P, Bonow RO, Mann DL, Zipes DP. Braunwald Heart Diseases a textbook of Cardiovascular Medicine 8th ed. Saunders 2008:478. In.
4. Goldberg A, Southern DA, Galbraith PD, Traboulsi M, Knudtson ML, Ghali WA, et al. Coronary dominance and prognosis of patients with the acute coronary syndrome. *AM Heart J*. 2007 Dec; 154(6):1116–22.
5. Veltman CE, de Graaf FR, Schuijf JD, van Werkhoven JM, Jukema JW, Kaufmann PA, et al. Prognostic value of coronary vessel dominance concerning significant coronary artery disease determined with non-invasive computed tomography coronary angiography. *Eur Heart J*. 2012 Jun;33(11):1367–77.
6. The Radiology Assistant : Coronary anatomy and anomalies . [cited 2019 Mar 6]. Available from: <http://www.radiologyassistant.nl/en/p48275120e2ed5/coronary-anatomy-and-anomalies.html>
7. Fuster, Walsh, Harrington hunt, King III, Nash prystowsky, Roberts, Rose; Hurst's THE HEART,13th edition The McGraw-Hill Companies 2011 7) Eren S, Bayram E, Fil F, Kop. In.

8. Balci B, Yilmaz O. Atherosclerotic involvement in patients with left or right dominant coronary circulation. *Kardiol Pol*. 2004 Jun;60(6):564–6.
9. Goldberg A, Southern DA, Galbraith PD, Traboulsi M, Knudtson ML, Ghali WA, et al. Coronary dominance and prognosis of patients with the acute coronary syndrome. *AM Heart J*. 2007 Dec;154(6):1116–22.
10. Pejčović B, Krajnc I, Anderhuber F, Kosutić D. Anatomical aspects of the arterial blood supply to the sinoatrial and atrioventricular nodes of the human heart. *J Int Med Res*. 08 Aug;36(4):691–8.
11. Loukas M, Curry B, Bowers M, Louis RG, Bartczak A, Kiedrowski M, et al. The relationship of myocardial bridges to coronary artery dominance in the adult human heart. *J Anat*. 2006 Jul;209(1):43–50.
12. Koşar P, Ergun E, Oztürk C, Koşar U. Anatomic variations and anomalies of the coronary arteries: 64-slice CT angiographic appearance. *Diagn Interv Radiol*. 2009 Dec;15(4):275–83.
13. Cademartiri F, La Grutta L, Malagò R, Alberghina F, Meijboom WB, Pugliese F, et al. Prevalence of anatomical variants and coronary anomalies in 543 consecutive patients studied with 64-slice CT coronary angiography. *Eur Radiol [Internet]*. 2008 Apr [cited 2019 Mar 10];18(4):781–91. Available from: <https://www.ncbi.nlm.nih.gov/pmc/articles/PMC2270369/>
14. A Study Of Coronary Dominance In Population Of Jalgaon Region Of North Maharashtra By Angiographic Method . Researchgate. [Cited 2019 Mar 10]. Available From: <https://www.researchgate.net/publication/281317153i>.
15. A Study of Coronary Dominance in the Population of Assam | Request PDF . ResearchGate. [cited 2019 Mar 10]. Available from: https://www.researchgate.net/publication/288325493_A_Study_of_Coronary_Dominance_in_the_Population_of_Assam

Conflict of interest: None
Funding: None
Cite this Article as: Singh V, Kottapalli S B, Gupta R, Agarwal N, Yadav Y, Coronary Artery Dominance In North Indian Population by The Angiographic Method. <i>Natl J Integ Res Med</i> 2019; Vol.10(4): 70-72