

Histopathological Study of Salivarygland Lesions

Dr.Richa. D. Patel

Department of pathology, Baroda Medical College,Vadodara-390001,India.

Abstract: Objectives: To study histological pattern for the classification and type of salivary gland lesions and epidemiological pattern. Use of Immunohistochemistry in histologically mimicking tumors. **Methods:** Cross sectional study was performed on 79 cases which included biopsies, specimens and referred materials received in pathology department. The samples were examined grossly, processed with hematoxylin and eosin stain for histological confirmation of lesion, special stain and immunohistochemistry done to diagnose some of cases. **Results:** 79 cases of salivary gland lesions were studied, out of which 28(35.44%) were non neoplastic, 34(43.03%) were benign and 17(21.51%) were malignant SGLs. Benign SGLs were more common in 2nd-3rd while malignant tumors were more common in 4th-6th decade of life. Male to female ratio was 1.72:1. Benign tumors were more common in parotid gland 26(81.25%), non-neoplastic lesions 20(54.05%) and malignant tumors 11(29.72%) both were more common in minor salivary glands. Pleomorphic adenoma 27(34.17%) was most common SLG tumor amongst all. Malignant SLG tumors mucoepidermoid carcinoma and adenoid cystic carcinoma had equal incidence 5(6.33%). Immunohistochemistry markers were applied in 8(10%) cases. **Conclusions:** Epidemiological features of most SGLs were similar to previous studies but some differences in age and site related distribution were noted. IHC was found helpful in diagnosis of 8 cases. [Patel R D Natl J Integr Res Med, 2019; 10(5):68-74]

Key Words: Adenoid cystic carcinoma, histology, Immunohistochemistry, Mucoepidermoid carcinoma, Pleomorphic adenoma, mammary analog secretory carcinoma..

Author for correspondence: Dr.Richa. D. Patel, Department of Pathology, Baroda Medical College, Vadodara-390001, India. E-mail: dr.richa0622@gmail.com.

Introduction: Salivary glands are unique amongst the secretory glands, with a more heterogeneous group of tumors, exhibiting greatest histological diversity¹. Accounting for less than 2% of all human neoplasm but comprise a morphologically diverse group of rare tumors². Disorders of Salivary gland include inflammatory, immunological and neoplastic lesions. They have low incidence and their anatomical relationship, especially that of the parotid gland to the facial nerve, makes their management challenging³. The salivary gland system includes three pairs of major glands- parotid, submandibular and sublingual and many minor glands in the submucosa of the oral cavity. Lips, floor of mouth, gingiva, cheek, hard & soft palates, tongue, tonsillar areas and oropharynx⁴. Major salivary gland tumors tend to be benign, whereas minor salivary gland tumors tend to be malignant⁵.

Any chronic disease process / neoplasms in this location results in an apparent disfigurement of face and/or loss of lubrication of oral mucosa is the one most well appreciated by all⁶. The salivary glands are compound exocrine glands, composed of a ductal and an acinar portion (serous or mucinous type)⁷. The parotid and the sublingual glands of the tongue are exclusively of the serous type of gland. Salivary glands situated at palate, base and the lateral border of the tongue are predominantly of the mucous type. The submandibular, sublingual salivary glands and

minor salivary glands located in lip, cheek and apex of tongue have both components⁸. Parotid gland is divided into numerous lobules each containing many secretory units. Supporting tissue septa radiate between the lobules convey blood vessels, nerves and large excretory ducts. Myoepithelial cells embrace the secretory units, their contraction helping to expel the secretory product. The excretory duct is lined by stratified epithelium⁹. Duct System - The intercalated duct is quite short, lined by a single layer of cuboidal epithelial cells that are backed by myoepithelial cells on the outside. The striated ducts are lined by a columnar epithelium with luminal brush border. Interlobular ducts are made up of stratified epithelial cells. Elastic and collagen fibers surround the periphery⁸.

Striated ducts have a folded basal membrane, to enable active transport of substances to make saliva hypotonic¹⁰. Saliva is formed by the acinar cells, it is high in amylase content and it contains acidic and neutral sialomucin⁹. The reserve cells of the intercalated ducts are the source of regeneration of the acinar tissue and the terminal duct system, and are thought to be the progenitors (together with myoepithelial cells) of most salivary gland tumors. Basal and luminal cells at all levels of the duct system and even acinar cells are capable of DNA synthesis and mitosis, and therefore they all have the potential to give rise to neoplasms¹¹.

Immunohistochemistry can enhance the accuracy and be a helpful tool in cases which cannot be assessed by histological examination, such as the cell nature and differentiation status, cell proliferation, and tumor protein expression. Utility of IHC in salivary gland tumor pathology is under the following issues: assessment of cell differentiation, focusing on neoplastic myoepithelial cells; discrimination of histologically mimic tumor groups; diagnosis of specific tumor types¹².

The purpose of study is to document epidemiological correlation of salivary gland, study histological pattern to type salivary gland lesions and use of immunohistochemistry to diagnose some of salivary gland lesions.

Materials and Methods: This study was cross sectional study performed on biopsy and excised salivary gland specimens submitted to the department of pathology, Baroda medical college during the period of two years. An ethical committee approval taken from Institutional Ethics Committee for Human research Medical College &SSG Hospital, Baroda. A total of 79 cases were studied. Clinical details of patient were obtained from requisition form received in pathology department and entry was made in the proforma.

The specimens were subjected to a thorough gross examination. Appropriate sections were taken. The sections were processed and paraffin blocks were prepared. The sections were cut at 4-5 micron thickness and stained with hematoxylin and eosin for histopathological confirmation of salivary gland lesions. During the HPE reporting, most of the cases were diagnosed by light microscopy. Special Stained used when needed. Only in certain cases where there was diagnostic dilemma, Immunohistochemistry (IHC) markers were applied.

Results : Out of total 79cases, 28 (35.4%) non-neoplastic lesions, 34 (43%) benign and 17 (21.5%) malignant tumors were found.50 (63.29%) male and 29(36.7%) female patients were having salivary gland lesions. Non-neoplastic lesions were more common in 2nd -3rd decade of life, benign tumor and malignant were more common in 2nd -3rd and 4th -6th decade of life respectively. (Table 1 & 2)

Amongst non-neoplastic lesions cystic lesions were common in both gender. One case of intra parotid gland lymphnode tuberculosis found in female patient. Pleomorphic adenoma was commonest benign tumor in both. Cases of warthins tumor, canalicular adenoma, basal cell adenoma, myoepithelioma were found male patients. In female mucoepidermoid carcinoma was more common than other malignant tumor and in male adenoid cystic carcinoma was more common. One case of each mammary analog carcinoma of salivary gland and high grade B-cell extranodal non-hodgkins lymphoma was found.

Table 1 : Distribution of salivary gland lesions according to sex of the Patients

Sex	Non Neoplastic	Benign	Malignant
Male	18	22	10
	66.6%	62.85%	58.82%
Female	09	13	07
	33.3%	37.14%	41.2%
Total	27	35	17
	100.0%	100.0%	100.0%

Table: 2 Anatomical location of salivary gland tumors according to category

Site of Tumor	Category			Total
	Non neoplastic	Benign	Malignant	
Parotid Gland	03	26	03	32
	9.37%	81.25%	9.37%	100%
Submandibular Gland	05	02	03	10
	50%	20%	30%	100%
Minor salivary Gland	20	06	11	37
	54.05%	16.21%	29.72%	100%

In present study IHC was applied in 8 cases. (Histological picture are shown in figure 1 to 8):

A 52 year female presented with growth over hard palate. Microscopic differential diagnosis ? adenoid cystic carcinoma or canalicular adenoma. On IHC Pankeratin, GFAP and CD117 positive and p63 negative diagnosis of Canalicular adenoma given.

A 25 year male presented with growth over soft palate. On light microscopy examination tumor showed plasmacytoid cells predominantly , cells showing clear cell changes and myxoid material without malignant features so, diagnosis of benign tumor made. On IHC pankeratin, GFAP, S-100 and h-caldesmon positive and CD34

negative. Diagnosis of Myoepithelioma was given.

A 28 year female with swelling over lingual side of mandible. On microscopy diagnosis of low grade malignant salivary gland tumor made. Final diagnosis of Low grade mucoepidermoid carcinoma given with positive marker p63,Calponin and EMA.

A 25 year male presented with right side parotid region swelling. Micorscopic differential diagnosis ? Mammary analog secretory carcinoma or acinic cell carcinoma, microcystic type made. On IHC S-100, Vimentin, Ck8, Ck18, Ck7 and GCDFP-15 positive and Calponin, Ck5/6, Ck 20 and p63 negative. Diagnosis of MASC given.

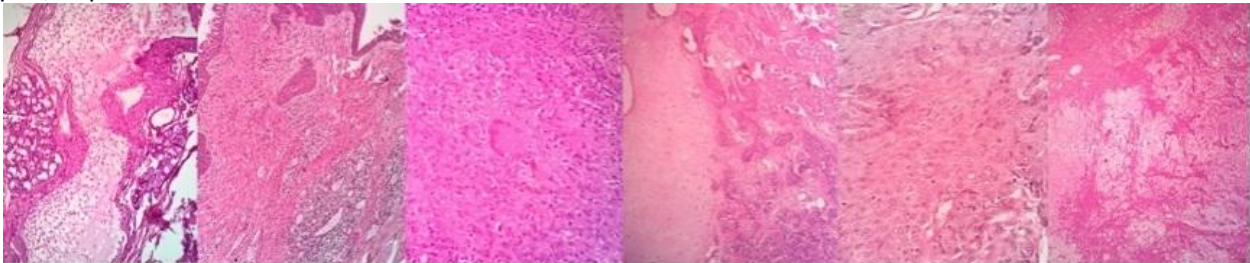


Fig.1.H&E A. Mucocele 40X B. Chronic Sialadenitis C. Intraparotid Lymphnode Tuberculosis D,E,F.Pleomorphic adenoma 40X

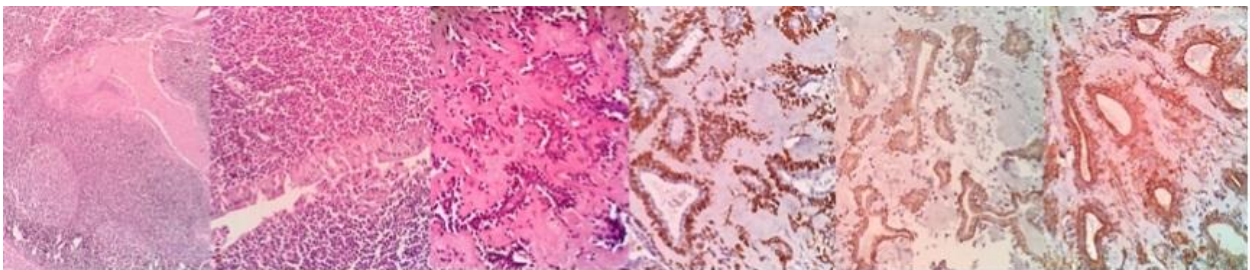


Fig.2. H&E A. Warthins tumor 10X B. Warthins tumor 40X . Canalicular Adenoma C. H&E10X D.GFAP E.CD117 & F.Pankeratin positive

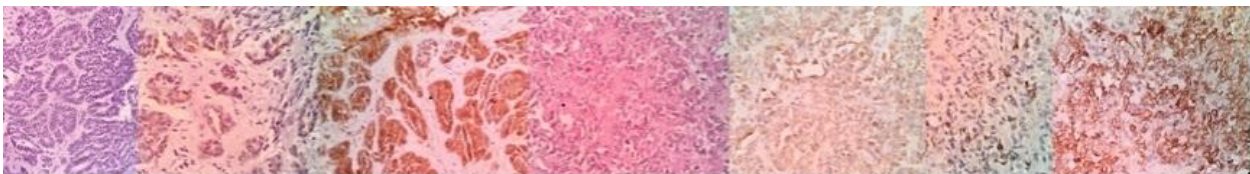


Fig.3. Basalcell Adenoma A. H&E 40X B. CK7 & C. S-100 Positive. Myoepithelioma D. H&E 40X E. h-caldesmon F.GFAP & G. Pankeratin positive

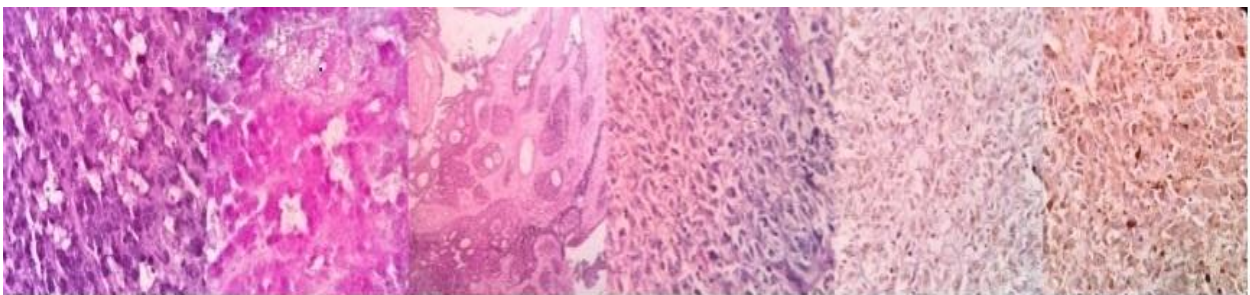


Fig.4. Acinic cell Carcinoma A.H&E 40X B.PAS Stain. C. Acinic cell carcinoma. Myoepithelial Carcinoma. D.H&E40X E.p63 & F.S-100 positive

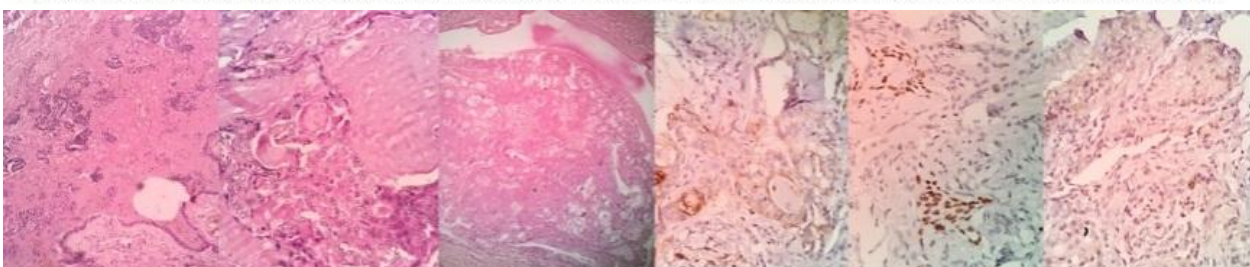


Fig.5. Mucoepidermoid Carcinoma A,B,C. H&E 40X D.EMA E. p63 & F. Calponin Positive

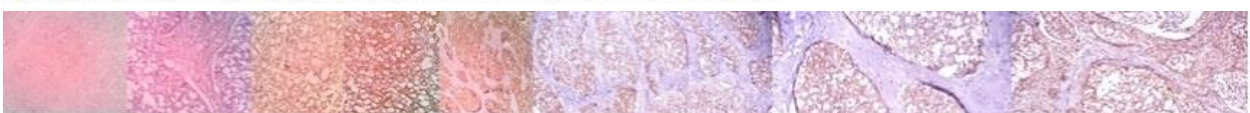

Fig.6 Mammary analog secretory carcinoma A,B. H&E 40X C.GCDFP-15 D.CK7 E.S-100 F.CK8 G.Ck18 F. Vimentin Positive

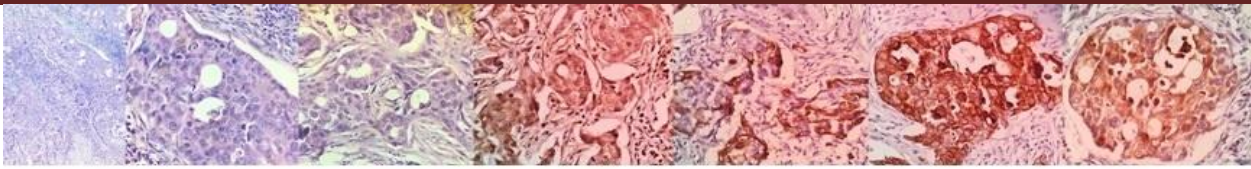


Fig.7. Salivary duct Adenocarcinoma A,B,C. H&E 40X D. CEA E.CK5/6 F. Ck7 G.GCDFP-15 Positive

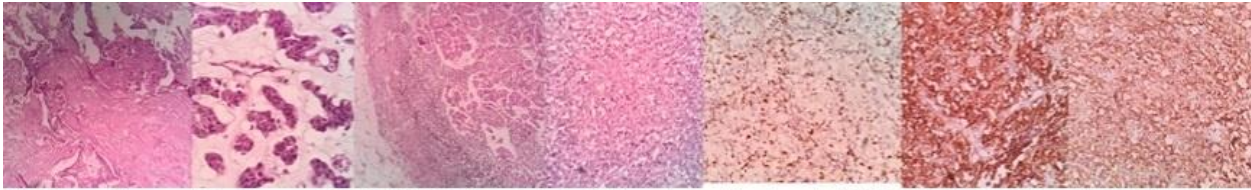


Fig.8 Ca. ex Pleomorphic adenoma A,B. H&E 40X C. LN metastasis. High grade B-cell extranodal NHL. D.Ki-67(30-40%) E.LCA F.CD20 Positive

A 50 year male presented with swelling over hard palate . On microscopy differential diagnosis of ? basal cell adenoma or polymorphous low grade adenocarcinoma made as it did not show infiltration , mitosis or atypia. On IHC S-100, Ck7 positive and SMA, GFAP,CD117 negative diagnosis of Basal cell adenoma given.

A 34 year male presented with hard palate swelling. Microscopy showed monomorphic cells with infiltration in surrounding tissue. On IHC CD20, Ki67(30-40%) and LCA positive and CD2,CD5,S-100, Calponin, Pan-Ck negative. Diagnosis of High grade B-Cell extranodal Non-hodgkin's lymphoma given.

A 50 year male with growth over base of tongue. On microscopy diagnosis of malignant tumor made. On IHC myoepithelial marker p63 and S-100 positive and CK5/6, HMB45 and SMA negative. Diagnosis of Myoepithelial carcinoma given. A 60 year male with right side upper neck swelling. Microscopy showed cribriform pattern and feature of malignancy with IHC it show GCDFP-15, CK5/6, CK7, CEA positivity and p63 negative. Diagnosis of Salivary duct adenocarcinoma given.

Discussion: In present study 79 cases of salivary gland lesions were studied during period for two years. In the present study maximum number of cases were seen in age group 21 to 30 years compared to DhanamjeyaRao Teeda et al¹⁴ which showed maximum cases in 41 to 50 years and Syed Imtiyaz Hussain et al¹³ which showed maximum cases in 31-40years. In the present study in age group of 51-60 years incidence was 15.2% which almost similar to Syed Imtiyaz Hussain et al¹³ 14.0% and in age group of 31-40 years incidence was 18.98% and 16.98% in present and DhanamjeyaRao Teeda et al¹⁴ study respectively(Table 3). The ratio of M: F of benign salivary gland tumors was almost similar in syed

Imtiyaz Hussain et al¹³ and present study. The ratio of M: F of malignant salivary gland tumors was similar in Dave P.N. et al¹⁵ and present study (Table 4).

Table 3: Comparative analysis of age wise distribution of salivary gland lesions

Age group	Syed Imtiyaz Hussain et al ¹³	Dhanamjeya Rao Teeda et al ¹⁴	Present Study
0-10	7%	0%	6.32%
11-20		15.9%	8.86%
21-30	21.0%	13.20%	27.84%
31-40	26.0%	16.98%	18.98%
41-50	22.0%	24.52%	12.65%
51-60	14.0%	11.32%	15.2%
61-70	10.0%	16.98%	8.86%
71-80		1.88%	-
81-90		-	1.26%

Table 4: Comparative analysis of salivary gland lesions in males and females.

Study	M:F RATIO	
	Benign	Malignant
Dave P.N. et al ¹⁵	1	1.42
Syed Imtiyaz Hussain et al ¹³	1.62	4.28
Kirti N. Jaiswal et al ³	0.7	1.28
Present Study	1.71	1.42

Incidence rate of 43.03% of benign salivary gland tumors in present study was similar to the study of Malliga .S et al¹ and Mallepogu Anil Kumar et al¹⁶ with the incidence rate of 51.45 % and 54.54% respectively. The incidence rate of malignant tumors was 21.51% in present study as compared to 18.86% and 28.15% in the study of DhanamjeyaRao Teeda et al¹⁴ and Malliga .S et al¹ respectively(Table 5). The most common site of salivary gland lesion was parotid gland in all studies but in present study minor salivary gland was most common site. Involvement of parotid

gland almost similar 40.50% and 48.3% in present study and Anita Omhare et al¹⁷ respectively. Involvement of submandibular

gland was almost similar in present (13.92%) and DhanamjeyaRao Teeda et al¹⁴(16.9%) (Table 6).

Table : 5 Comparative analysis of salivary gland lesions in different studies.

Characteristics	No of Cases			Incidence (%)		
	Non Neoplastic	Benign	Malignant	Non Neoplastic	Benign	Malignant
Mallepogu Anil Kumar et al ¹⁶	15	30	10	27.27%	54.54%	18.18%
DhanamjeyaRao Teeda et al ¹⁴	12	31	10	22.64%	58.49%	18.86%
Malliga .S et al ¹	21	53	29	20.4%	51.45%	28.15%
Anita Omhare et al ¹⁷	66	39	19	53.22%	31.45%	28.4%
Present Study	28	34	17	35.44%	43.03%	21.51%

Table 6 :Comparative analysis of site wise distribution of salivary gland lesions.

Site	DhanamjeyaRao Teeda et al ¹⁴	Anita Omhare et al ¹⁷	Mallepogu Anil Kumar et al ¹⁶	Malliga .S et al ¹	Present Study
Parotid Gland	73.5%	48.3%	67.27%	58.25%	40.50%
Submandibular Gland	16.9%	41.2%	25.45%	29.12%	13..92%
Minor Salivary gland	9.4%	10.4%	7.27%	12.6%	45.56%

Incidence of chronic siadenitis almost similar in present study(6.32%) and DhanamjeyaRao Teeda et al¹⁴(5.66%). Case of tuberculosis found in present study and Anita Omhare et al¹⁷ only(Table 7). Pleomorphic adenoma was most common benign salivary gland tumor in all studies followed by warthin’s tumor. Incidence

rate of pleomophic adenoma(34.17%) and warthins tumor (3.79%) of present study almost similar to Malliga .S et al¹ study with incidence rate of 41.6% and 2.1% respectively. Incidence of myoepithelioma almost similar in present study (1.26%) and Dhanamjeya Rao Teeda et al¹⁴ (1.88%) (Table 8).

Table 7: Comparative analysis of non-neoplastic Salivary gland lesions

Type of Lesions	DhanamjeyaRao Teeda et al ¹⁴	Anita Omhare et al ¹⁷	Mallepogu Anil Kumar et al ¹⁶	Present study
Acute Inflammation	-	-	-	1.26%
Chronic Sialadenitis	5.66%	39.2%	16.36%	6.32%
Tuberculosis	-	3.33%	-	1.26%
Cystic Lesion	16.98%	9.2%	10.9%	26.58%
Rannula	-	-	-	2.53%
Retention Cyst	-	-	-	17.72%
Mucocele	-	-	-	6.32%

Table 8: Comparative analysis of Benign Salivary gland tumor

Type of Tumors	DhanamjeyaRao Teeda et al ¹⁴	Anita Omhare et al ¹⁷	Mallepogu Anil Kumar et al ¹⁶	Malliga .S et al ¹	Present study
Pleomorphic Adenoma	45.25%	21.66%	43.63%	41.6%	34.17%
Warthin’s Tumor	5.66%	0.8%	10.9%	2.1%	3.79%
Canalicular adenoma	-	-	-	-	1.26%
Myoepithelioma	1.88%	-	-	-	1.26%
Oncocyst adenoma	-	-	-	1%	1.26%
Basal Cell Adenoma	-	-	-	-	1.26%
Monomorphic Adenoma	5.66%	8.33%	-	-	-
Hemangioma	-	1.67%	-	-	-
Neurofibroma	-	-	-	1%	-

Table 9: Comparative analysis of malignant Salivary gland tumor

Type of Tumors	DhanamjeyaRao Teeda et al ¹⁴	Anita Omhare et al ¹⁷	Mallepogu Anil Kumar et al ¹⁶	Malliga .S et al ¹	Present study
Mucoepidermoid Carcinoma	9.43%	6.66%	7.27%	22.9%	6.33%
Acinic cell carcinoma	-	3.33%	-	-	2.53%
Adenocystic Carcinoma	3.77%	1.66%	3.63%	4.2%	6.33%
Myoepithelial Carcinoma	-	-	-	-	1.26%
Salivary duct adenocarcinoma	1.88%	0.8%	-	-	1.26%
Carcinoma ex pleomorphic adenoma	1.88%	3.33%	3.63%	6.25%	1.26%
Mammary analog secretory carcinoma	-	-	-	-	1.26%
High grade B cell extranodal Non Hodgkins Lymphoma	-	-	-	-	1.26%
Poorly differentiated carcinoma	1.88%	-	3.63%	-	-

Mucoepidermoid carcinoma was most common malignant salivary gland tumor of all studies. Incidence rate of mucoepidermoid carcinoma of present study 6.33% was almost similar to Anita Omhare et al¹⁷ with incidence of 6.66% . Incidence rate of carcinoma ex pleomorphic adenoma of present study 1.26% was almost similar to DhanamjeyaRao Teeda et al¹⁴ with incidence of 1.88%.(Table 9).

Conclusion: Histopathological examination by H&E stain is gold standard for diagnosis of salivarygland lesions but immunohistochemistry definitely helpful while diagnosing morphologically mimicking tumors.

References:

- Malliga .S, Sivaelangovan .R A Correlative Cytological and Histopathological Study of Lesions of Salivary Gland International Journal of Science and Research .2016;5(8):758-761.
- Junu Devi, Kunja Lal Talukdar Salivary gland neoplasm: clinicopathological study of 84 cases IAIM.2015; 2(4): 70-77.
- Kirti N. Jaiswal, Sachin .P.Johari, Alok C.Shrivastav , Anuradha V. Shirkhande Study of Salivary gland neoplasms Indian Medical Gazette.MARCH 2015:96-100.
- Juan Rosai- Major and minor salivary glands. In: Michael Houston ed. ROSAI AND ACKERMAN'S Surgical Pathology. 10th ed.2011,Vol1:817-857.
- Epker B.N. and Henry F.A. Clinical histopathology and surgical aspects of Intraoral minor salivary gland tumors. Journal of oral surgery. 1969; 27:792-804.
- Antonio G. Nascimento, Ana Lucia P. Amaral, Lúcia Anne F. Praclo, Jacob Kligerman, Telma Ruth P. Silveira. Adenoid cystic carcinoma of salivary gland (A study of 61 cases with clinicopathologic correlation) cancer .1986; 57: 312 - 319.
- Martínez-Madrigal F, Bosq J, Casiraghi O.Major salivary glands. In Mills SE (ed.):Histology for pathologists, ed. 3. Philadelphia, Lippincott Williams & Wilkins.2007; pp.445-469.
- Sternberg's Diagnostic surgical pathology. Lippincott Williams & Wilkins. Fifth edition, 824-859.
- B. Young, J. W. Heath. Wheater's functional histology. Churchill Livingstone. Fourth edition, 2000.
- The histology guide-oral-salivary gland, university of Leeds.
- Dardick I, Byard RW, Carnegie JA. A review of the proliferative capacity of major salivary glands and the relationship to current concepts of neoplasia in salivary glands. Oral Surg Med Oral Pathol. 1990, 69: 53-67.
- Toshitaka Nagao, Eiichi Sato, Rie Inoue Hisashi Oshiro, Reisuke H. Takahashi, Takeshi Nagai, Maki Yoshida, Fumie Suzuki, Hiyo Obikane, Mitsumasa Yamashina and Jun Matsubayashi. Immunohistochemical Analysis of Salivary Gland Tumors: Application for Surgical Pathology Practice. Japan society of Histochemistry and Cytochemistry. 2012;45 (5):269-282.

13. Syed Imtiyaz Hussain, Gulshan Akhter , Farooq sideeq , Baba Iqbal , Ruby Reshi , Farzana Manzoor and Arshi Beg. Histopathological Spectrum Of Salivary Gland Tumours: A Hospital Based Study. International Journal Of Advance Research. 2017;5(2):1912-1922.
14. Dr.DhanamjeyaRaoTeeda,Dr.AkarshM.P,Dr. Sindhura. P, Dr.VramyaSwathi A . Histopathological Study of Salivary Gland Lesions. IOSR Journal of Dental and Medical Sciences .2016;15(6):80-86.
15. Dave P.N., Parikh U.R., Goswami H.M., Jobanputra G.P., Panchal N.V., Shah A.M. Histopathological Study Of Salivary Gland Lesions. IJCRR.2015;7(17):45-51
16. Mallepogu Anil, Raghu, C. Sekhar. Histopathological Study of Neoplastic and Nonneoplastic Lesions of Salivary Gland: An Institutional Experience of 5 Years. Int J Sci Stud .2017;4(12):69-72.
17. Anita Omhare,Sanjeev Kumar Singh Jitendra Singh Nigam, and Ankit Sharma Cytohistopathological Study of Salivary Gland Lesions in Bundelkhand Region, Uttar Pradesh, India. Pathology Research International .2014,(804265):1- 5.

Conflict of interest: None
Funding: None
Cite this Article as: Patel R D. Histopathological Study of Salivarygland Lesions. Natl J Integr Res Med 2019; Vol.10(5): 67-74