

Stapler Hemorrhoidectomy v/s Open Hemorrhoidectomy

Dr. Krunal Solanki*, Dr. Asit Patel**, Dr. Reddemma Kanniganti***, Dr. Anil Sanjava****

*Associate Professor, **Professor & Head of Unit, ***3rd Yr. Resident, ****2nd Yr. Resident

Sheth LG Hospital & AMC MET Medical College, Ahmedabad, Gujarat, India

Abstracts: Background: Haemorrhoidal disease is a painful concern to the sufferer and the treating surgeon. Several methods are available for treatment of hemorrhoids. Milligan Morgan Hemorrhoidectomy is the most widely practiced Gold standard surgical technique for the management of 3rd and 4th degree hemorrhoids. Staplers are novel methods known for its simplicity, ease and standardization to an anastomosis Material and Method: A case study was done to compare Open haemorrhoidectomy with Stapler Haemorrhoidectomy in context to parameters such as post-operative pain, early ambulation, post-operative complications in patients operated for stapler Hemorrhoidectomy Result: 50 patients were studied, of which 42 were male and 8 female. The postoperative pain as analysed by visual analogue scale was significantly high on the day of surgery for patients operate by open technique as compared to stapler. Conclusion: Operative time, duration of hospital stay and return to normal activity were more satisfactory with stapler haemorrhoidectomy than the open method. Hence, those who can afford the cost of surgery will definitely benefit, though it cannot be prescribed to all patients due to economic constraints. We still suggest long-term follow-up of all stapler Hemorrhoidectomy patients. [Solanki K Natl J Integr Res Med, 2019; 10(1):40-42]

Key Words: Stapler, Open Hemorrhoidectomy, Surgery

Author for correspondence: Dr. Krunal. Solanki, 502, Rajvansh Apartment, Judges Bungalow, Bodakdev, 380054, Ahmedabad. E-mail: drkunal_0001@yahoo.com. M : 09924544622

Introduction: The human race is acclaimed as a downside to the upright posture adapted as an evolutionary refinement of Homo sapiens. The irksome nature of the haemorrhoidal disease has been of painful concern to the sufferer and the treating surgeon alike. No other single disease entity has so many different treatment modalities advocated from disparate systems of medicine than hemorrhoids. This in itself goes to show that not a single method has escaped from patient dissatisfaction due to difficulty in compliance, painful convalescence, unacceptable complications and persistence of symptoms.

Modern surgical practice has learnt from experience that surgery as an option is not viable and better avoided in 1st and 2nd degree hemorrhoids. The Milligan Morgan Hemorrhoidectomy is the most widely practiced surgical technique for the management of 3rd and 4th degree hemorrhoids and is considered the current Gold standard and has stood the test of time by virtue of its least postoperative complications, cost effectiveness and better long-term effects. Staplers as a mechanical adjunct to surgery replacing the traditional sutures have revolutionized operative procedures over the last decade worldwide due to its simplicity, ease and standardization to an anatomises. We conducted a randomized controlled study at AMC MET Medical College at Ahmedabad in India to

compare the stapled Hemorrhoidectomy and the Milligan Morgan open Hemorrhoidectomy.

Materials and Methods: A total of 50 patients of age 30-40 years with internal haemorrhoids Grade 3 and Grade 4 with or without external hemorrhoids were included in the study. Patients with grade 1 and 2 hemorrhoids, infected or thrombosed hemorrhoids, those who have undergone previous anal surgeries for hemorrhoids or fistula and those with co-existing ano-rectal conditions like fissure-in-ano, fistula-in-ano, were excluded from the study.

All patients were admitted 2 days prior to the surgery. Preliminary investigations for fitness of anaesthesia and surgery were done which included routine haematological investigations of hemoglobin, total and differential blood cell counts, blood group, blood urea and glucose and serological tests for antibodies of hepatitis B and HIV, a complete urine examination and an electrocardiogram.

One day prior to surgery, patients underwent a pre-anesthetic check up and also were informed by the surgeon about both the procedures and that one of them would be performed on them. All patients were given a cleansing enema the night before and on early morning of surgery. Stapled Hemorrhoidectomy (SH) was performed according to the

technique described by Longo with slight modifications using the PPH set. The PPH 01 consisted of circular anal dilator, pursestring suture anoscope, suture threader and 33 mm haemorrhoidal circular stapler¹.

Description of stapler hemorrhoidectomy procedure: The circular anal dilator was gently inserted and secured into the anus thereby reducing the prolapse of the anoderm and parts of the anal mucous membrane. The circular anal dilator was then fixed to the perianal skin using of 1-0 silk. The obturator of the dilator was removed and replaced with the pursestring anoscope. The 90-degree window in the anoscope was rotated through the anus for application of a 2-0 Prolene (polypropylene) pursestring suture. The circular pursestring was placed at 3 to 5 cm above the dentate line. The pursestring was started at 3 O'clock position moving in clockwise direction and including only the mucosa and submucosa. There were about three bites taken in each quadrant of the canal. A second 2-0 polypropylene simple stitch was placed perpendicular and contralaterally at 9 O'clock position. In women, the posterior vaginal wall was checked to avoid inclusion in the pursestring. The haemorrhoidal stapler was opened to its maximum position and the head gently introduced and positioned proximal to the pursestring where upon it was secured. This ensured equal and opposite traction sutures to be passed through the stapling device for a more uniform loading (equal "pull down") of tissue into the drum of the stapler. The stapler was held in the closed position for 30 seconds before and 2 minutes after firing. After extraction of the stapling device, the pursestring anoscope was inserted and the stapled line inspected for uniformity and presence of any bleeding or tears. Any bleeding was handled by under-running the bleeding points with 2-0 silk sutures. The stapler was opened and the completeness of the excised doughnut checked no anal pack was kept into the canal. External dressing was applied.

Milligan Morgan open Hemorrhoidectomy was done for the second group. The external and internal hemorrhoids were excised entirely upto the anorectal ring with help of scissors. The pedicles were doubly suture ligated with help of no.2 chromic catgut. Diathermy was used to achieve hemostasis; the wounds were left open

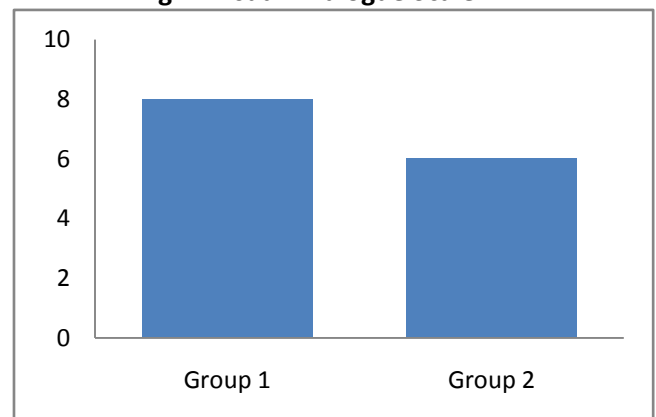
to granulate. No packs were left in anal canal at end of this procedure. The operating time was defined as the time from beginning of the surgery until the application of the dressing.

All patients received a normal diet postoperatively and were given oral Laxative 15ml HS daily for preventing hard stools. Patients in both groups were advised same cleaning of the anal region and Sitz baths, and same kind of external dressing applied.

A pain score data sheet (visual analogue scale) was filled out by the patients postoperatively (0 mm indicates no pain and 10 mm indicates maximum pain). Pain scores were evaluated for three consecutive postoperative days by a surgical resident not involved with the operative procedure. Urinary retention was defined as inability to void urine postoperatively for a period of 12 hours or more. Pain therapy consisted of Diclofenac Sodium 50mg twice daily. Patients stayed in the hospital for 2 to 5 days. Patients received postoperative oral metronidazole 400 mg tid for 3 days.

Result : Of the total 50 patients that were evaluated, 42 were male and 8 female patients. They were then divided in two groups of 25; Group 1 was operated by open technique and group 2 operated by stapler method. The mean operative time for the procedure was 35 to 40 minutes, considered from introduction of anal dilator to application of dressing and that for open technique was 60 to 70 minutes.

Fig 1: Visual Analogue Scale



A pain score data sheet (visual analogue scale) was filled out by the patients (assisted by resident doctors if required) postoperatively (0 mm indicates no pain and 10 mm indicates maximum pain). Most patients experienced

significant amount of pain of the first day ranging between 5-7 with a mean score of on VAS for stapler and 7-9 for open haemorrhoidectomy.

The pain significantly reduced on 2nd and 3rd day coming down to 2-3 on VAS in most patients of stapler procedure, where as it remained comparatively high “4-5” for patients operated by open technique.

Complications i.e. local hematoma was encountered a patient and improper stapler line was seen in one patient where in conversion to open technique was required. Urinary retention was considered as in ability to pass urine for 12 hours postoperatively, only one patient had this complication. On an average, most patients operated by stapler technique were discharged on 2rd postoperative day. On the other hand, patients operated by open technique were discharged by 4th postoperative day. Most patients operated by stapler technique returned to their routine work by 4th to 5th postoperative day and those operated by open technique returned to their work between 6th to 8th postoperative days.

Conclusion : The benefits of Stapler haemorrhoidectomy include less postoperative pain, lesser operative time, short duration of hospital stay and early return to normal activity. Early functional and symptomatic outcomes have been satisfactory and appear similar to those achieved using conventional techniques without increase in complications. We would still suggest long-term follow-up of these patients, which will help inpatient management.

References

1. Jayaram S, Colguhoun PH, Malthaner RA. StapledVersus Conventional Surgery for Hemorrhoids. Cochrane Database Syst. Rev. 2006; 18(4):CD005393.
2. Milligan ETC, Morgan CN, Jones CE, Officer R. Surgical anatomy of the anal canal and operative treatment of haemorrhoids. Lancet. 1937; ii: 1119-24.
3. Beattie GC, Lam JPH, London MA. A prospectiveevaluation of the introduction of circumferential-stapled anoplasty in the management of hemorrhoids and mucosal prolapse. Colorectal Dis. 1999; 2:137-42.
4. Thomson WH. The nature of haemorrhoids. Br JSurg. 1975; 62:542-52

5. Kohlstadt CM, Weber J, Prohm P. Staplerhemorrhoidectomy. A new alternative to conventional methods. Zentralbl Chir. 1999; 124:238-43.
6. Pernice LM, Bartalucci B, Bencini L, Borri A, Catarzi S, Kroning K. Early and late (ten years) experience with circular stapler hemorrhoidectomy. Dis Colon Rectum. 2001; 44:836-41.
7. Kirsch JJ, Staude G, Herold A. The Longo andMilligan-Morgan hemorrhoidectomy. A prospective comparative study of 300 patients. Chirurg. 2001; 72:180-5.
8. Carapeti EA, Kamm MA, McDonald PJ, PhillipsRK. Double blind randomized controlled trial of effect of metronidazole on pain after day-case haemorrhoidectomy. Lancet. 1998; 351:169-72.
9. Hetzer FH, Demartines N, Handschin AE, ClavienPA. Stapled vs excision hemorrhoidectomy: long-term results of a prospective randomized trial. Arch Surg. 2002; 137:337-40.
10. Shalaby R, Desoky A. Randomized clinical trial ofStapled versus Milligan-Morganhaemorrhoidectomy. Br J Surg. 2001; 88:1049-53

| |
|--|
| Conflict of interest: None |
| Funding: None |
| Cite this Article as: Krunal S, Asit P, Reddemma K, Anil S. Stapler Hemorrhoidectomy v/s Open Hemorrhoidectomy. Natl J Integr Res Med 2019; Vol.10(1): 40-42 |