

5 years follow up of open reduction and internal fixation of lisfranc injuries

Ravikumar R. Bhesaniya¹, Bhavesh H. Jesalpura^{2,*}

¹Senior Resident, ²Professor, ²Dept. of Orthopaedics, ¹Smt. Sardaben general hospital, Saraspur, Ahmedabad, Gujarat, ²Banas medical college, Palanpur, Gujarat, India

*Corresponding Author: Dr. Bhavesh H. Jesalpura

Email: bjesalpura@yahoo.com

Abstract

In the treatment of fracture-dislocations of the tarso-metatarsal joints, early accurate diagnosis combined with prompt anatomical reduction and stable internal fixation provides optimal results

Aims and Objectives: Open reduction and internal fixation has been recommended as the treatment for most unstable injuries of the Lisfranc (tarso-metatarsal) joint. In many of cases Lisfranc injuries are diagnosed late or missed because of associated injuries and treated by other methods like cast application, closed reduction etc. and are associated with poor outcome.

Material and Methods: We performed a retrospective study of patients who underwent open reduction and screw fixation or k wire fixation of a Lisfranc injury in a three-year period. Among 20 adults treated for that injury, they were followed for minimum of 5 years. 5 injuries were purely ligamentous, and 15 were combined ligamentous and osseous. Patient outcome was assessed with use of the American Orthopaedic Foot and Ankle Society (AOFAS) midfoot score.

Results: The average AOFAS midfoot score was 79.8 points (on a scale of 0 to 100 points, with 100 points indicating an excellent outcome), with patients losing points for pain, decreased recreational function, and orthotic requirements. The major determinant of a good result was anatomical reduction ($p = 0.05$). Patients with purely ligamentous injury showed a trend toward poorer outcomes despite anatomical reduction and screw fixation/k-wire fixation.

Conclusion: This study support the concept of stable anatomical reduction of Lisfranc fracture-dislocations leads to the best long-term outcomes as patients so treated have less arthritis as well as better AOFAS midfoot scores.

Keywords: Lisfranc, Open reduction, AOFAS Score.

Introduction

In the treatment of fracture-dislocations of the tarso-metatarsal joints, early accurate diagnosis combined with prompt anatomical reduction and stable internal fixation provides optimal results.¹⁻⁷ Closed reduction and percutaneous Kirschner-wire fixation has been advocated by some authors,^{4,8-11} but the trend is toward open anatomical reduction and screw fixation/K-wire fixation.^{1-3,5,7} It has been observed that pure dislocations without fracture may be associated with a poorer outcome despite open reduction and internal fixation¹². The purpose of this study is to analyze the at least 5 years follow up of open reduction and internal fixation of Lisfranc dislocation with or without fracture.

Material and Methods

We performed a retrospective study of all patients with a tarso-metatarsal joint injury treated at V. S. general hospital and associate hospitals between 2010 and 2013. The study was conducted with the approval of ethics committee of the institution and prior consent of patients was taken. Inclusion criteria were skeletal maturity and open reduction and internal fixation of a Lisfranc joint injury. Indications for surgery were instability, displacement of at least 1 mm in any plane, and purely ligamentous injury.

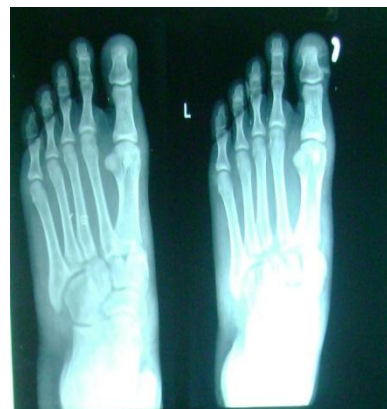

Fig. 1: Case no.1 without any fracture involvement of all 5 Tarso-metatarsal joints

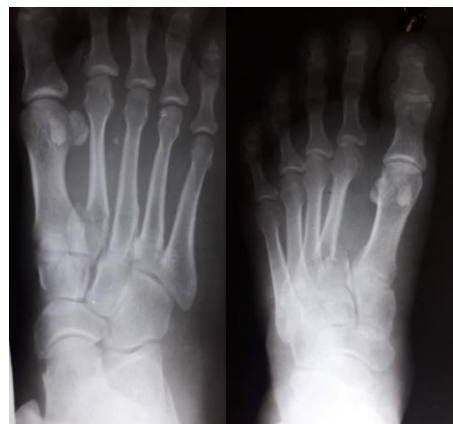

Fig. 2: case no. 13 with partial involvement of Tarsometatarsal joint

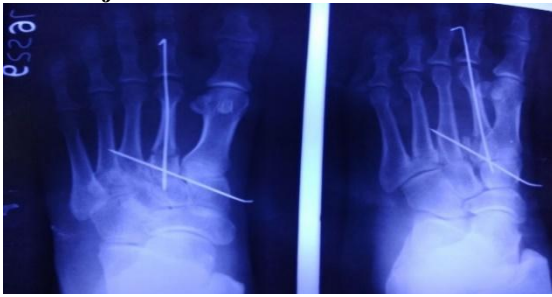

Fig. 3: Post op of case no. 13

Diagnosis was made from the x-ray by remembering the Stein's¹⁴ normal x-ray guideline: (a) The first metatarsal aligns itself with the medial cuneiform both medially and laterally. This is evident on both AP and internal oblique views. (b) The first intermetatarsal space corresponds precisely with the first intertarsal space on both AP and internal oblique views. (c) The medial border of the second metatarsal aligns itself exactly with the medial edge of the middle cuneiform. This is best seen on the AP view. (d) The second intermetatarsal space aligns itself precisely with the corresponding intertarsal space between the middle and lateral cuneiforms. This relationship is best appreciated on the internal oblique view. (e) The third

intermetatarsal space is continuous with the corresponding intertarsal space between the lateral cuneiform and cuboid, and the lateral border of the third metatarsal aligns itself to the lateral edge of the lateral cuneiform. This is seen best on the internal oblique view. (f) The medial border of the fourth metatarsal forms a continuous straight line with the medial edge of the cuboid. This is best appreciated on the internal oblique view. (g) The relationship of the fifth metatarsal to the cuboid varies and cannot be relied on to diagnose a tarsometatarsal injury. However, the fourth and fifth metatarsals almost always move as a unit, allowing the alignment of the fourth tarsometatarsal joint to be used as a marker for displacement of the fifth metatarsal. (h) On the lateral view, evaluation of the tarsometatarsal joints, specifically the important second tarsometatarsal, should demonstrate an uninterrupted line along the dorsal surface of the tarsal bone proximally and the corresponding metatarsal base distally. Any dorsal displacement of the metatarsals is abnormal and indicates a significant Lisfranc injury with instability. Slight plantar displacement of 1 mm or less, however, may be a normal radiographic finding. Overlap of bone structures can cause difficulty with interpretation of this view (Fig. 4).¹⁴

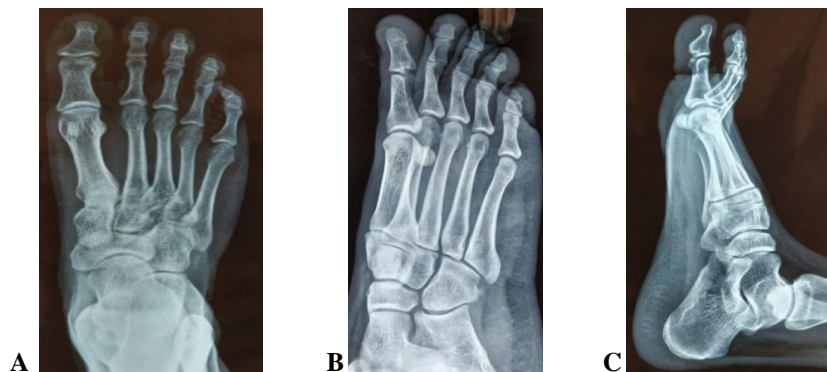

Fig. 4:(a) AP, (b) oblique and (c) Lateral View of normal foot alignment

20 adult patients with Lisfranc fracture dislocation treated with ORIF were followed up for minimum 5 years. There were 14 male patients and 6 female patients. The age range was from 21 to 70 years, with an average age of 44.45 years. The right foot was involved in 12 patients and the left foot in 8. All of the injuries occurred due to high-energy trauma. 15 patients had been injured in a motor-vehicle accident and 5 had fallen from the height. There were 13 isolated Lisfranc injuries. 7 patients had multiple trauma (an Injury Severity Score¹⁵ of at least 18 points), There were 16 closed injuries and 4 open injuries. The open injuries were classified according to the method of Gustilo and Anderson; 16 2 injuries were type I, 1 was type II, 1 type IIIA, and none were IIIB/IIIC.

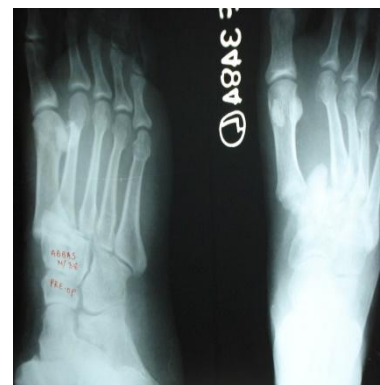

Fig. 5: Preoperative photograph of patient of case no.9

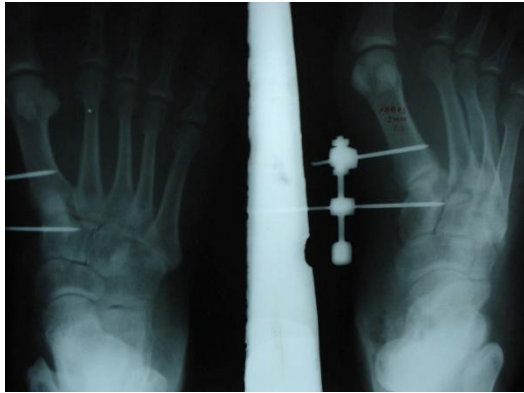


Fig. 6: Post operative photograph of patient no. 9

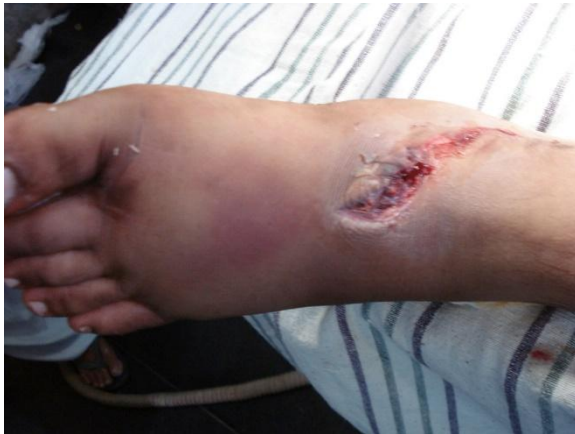

Fig. 7: case no.9 having open area that required coverage later on

13 patients had involvement of all five tarso-metatarsal joints, none had involvement of four, 3 had involvement of three, and 5 had involvement of two. 3 injuries involved the medial column (the first and second tarso-metatarsal joints) alone, and 2 involved the lateral column (the fourth and fifth tarso-metatarsal joints) alone. 4 patients required fasciotomy because of impending compartment syndrome of the foot. 14 had fractures of the bases of the metatarsals. 6 patients had associated cuneiform fractures or disruptions, and 4 had associated cuboid fracture. 15 patients had combined ligamentous and osseous injuries, and 5 had ligamentous injury only (no fracture). Patients with only a fleck sign⁴ (an avulsion fracture of the Lisfranc ligament¹⁷) were considered to have purely ligamentous injury. The direction of displacement was lateral in 14 patients, medial in 2, and divergent in 4. For 2 patients, the diagnosis was delayed for more than one month. Final radiographs were reviewed for evidence of fracture nonunion, malalignment, posttraumatic osteoarthritis, or implant failure.

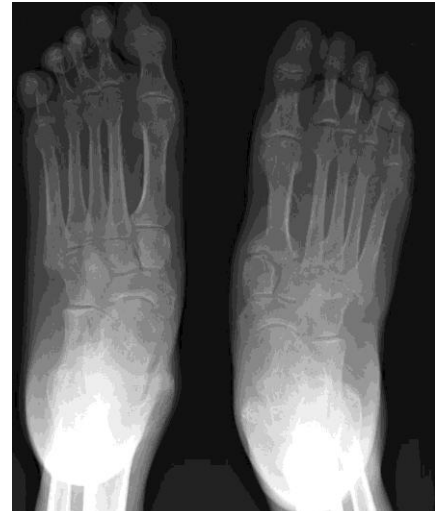

Fig. 8: case no. 4 who developed arthritis within 1 year

Nonunion was defined as no healing of the fracture after three months. Several radiographic parameters were used to assess alignment. In the normal foot, the medial border of the second metatarsal is collinear with the medial border of the middle cuneiform on the antero-posterior radiograph. On the oblique radiograph, the medial border of the fourth metatarsal is collinear with the medial border of the cuboid and the lateral border of the third metatarsal is collinear with the lateral border of the lateral cuneiform¹⁴. In the normal foot, a line tangential to the medial aspect of the navicular and the medial cuneiform (the medial column line) should intersect the base of the first metatarsal on an abduction stress antero-posterior radiograph¹³. The reduction was considered anatomical if this relationship was intact; nearly anatomical if it was within two millimeters, and non-anatomical if it was off by greater than two millimeters. Posttraumatic osteoarthritis was assessed clinically and on radiographs and was deemed to be present if there was any radiographic evidence of osteophytes, joint space narrowing, or subchondral cysts or sclerosis in conjunction with tarsometatarsal joint pain and tenderness and pain with joint motion (**Fig. 8**). The degree of posttraumatic osteoarthritis was classified according to the symptoms. Intermittent pain requiring intermittent use of over-the-counter analgesics was classified as mild, intermittent pain requiring use of regular prescriptive analgesics was classified as moderate, and constant chronic pain requiring use of stronger prescriptive analgesics was classified as severe. At the time of final follow-up for the purposes of this study, the patient's charts were reviewed to identify all complications. Also, a history was recorded and a physical examination was performed for all patients. Functional outcomes were assessed with use of the American Orthopaedic Foot and Ankle Society (AOFAS) score¹⁸ for the midfoot. The AOFAS score is based on a scale of 0 to 100

points, with 100 points indicating an excellent or maximum outcome.

Operative Technique

Open injuries were treated with immediate irrigation and debridement accompanied by open reduction and internal fixation or staged temporary external fixation with later open reduction and internal fixation.

Operative treatment of closed injuries was delayed until soft-tissue edema subsided, which usually occurred within two weeks, unless there were increased compartment pressures and urgent fasciotomy was done. Operative reduction and fixation proceeded from a medial to a lateral direction. The first and second tarsometatarsal joints were approached through a single dorsal incision over the first intermetatarsal space. The branches of the superficial and deep peroneal nerves and the dorsalis pedis artery were preserved, and the first and second metatarsocuneiform joints were opened and irrigated. Comminuted fragments were reduced when possible; smaller, irreducible fragments were removed. The first tarsometatarsal joint was aligned by reducing the medial border of the medial cuneiform to the medial border of the first metatarsal. The plantar-medial aspect of the joint was directly visualized to ensure that there was no plantar gap. The joint was held reduced with a provisional Kirschner wire, and then threaded 2.5/3 mm K-wire or if necessary then 3.5mm countersunk screw was inserted from the metatarsal base proximally into the medial cuneiform, with care being taken to avoid violating the adjacent naviculocuneiform joint.

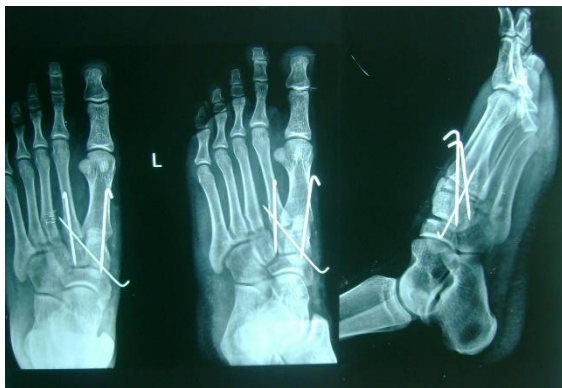

Fig. 9: Post operative case no. 9 at 6 weeks

If instability persisted, an additional K-wire or 3.5-millimeter screw was placed from proximal to distal and lateral to the first screw to add rotational stability. The second metatarsal was then reduced to the medial border of the middle cuneiform and was held provisionally with a Kirschner wire.

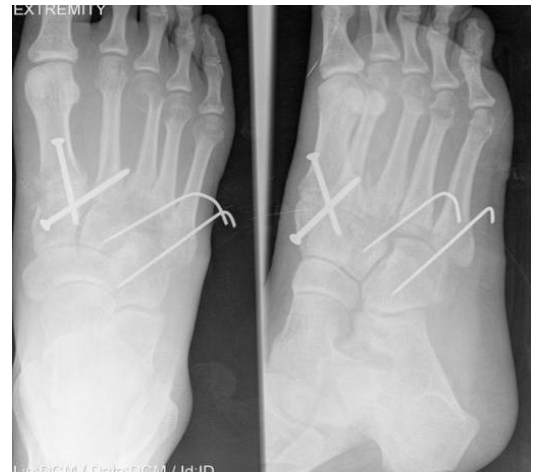

Fig. 10: Postoperative photograph at 6 weeks of case no.1

A threaded 2.5/3 mm K-wire or 3.5-millimeter countersunk cortical screw was placed from distal to proximal across the joint. An additional threaded 2.5/3 mm K-wire or 3.5-millimeter cortical set screw (the Lisfranc screw) was inserted under biplanar fluoroscopy from the medial cuneiform into the base of the second metatarsal to increase the stability of the fixation if required. This Lisfranc screw was placed in the line of the interosseous Lisfranc ligament.¹⁷ When the third metatarsal base was dislocated, a second dorsal incision was made between the third and fourth metatarsals to expose the third metatarsocuneiform joint. This joint was then reduced and was stabilized with a threaded 2.5/3 mm K-wire or 3.5-millimeter screw from a distal to a proximal direction. The fourth and fifth tarsometatarsal joints usually reduced once the above three reductions were achieved, and they were held with one or two trans-articular percutaneous smooth Kirschner wires from the base of the fifth metatarsal into the cuboid. Open reduction of these lateral two joints was required in only one patient. Associated cuneiform or cuboid fracture required reduction and fixation with Kirschner wires, screws, a plate and screws,¹⁹ or a combination of these implants. The alignment of the fractures and tarsometatarsal joints and the position of the implants were checked with fluoroscopy. Each foot was also examined clinically after fixation to assess the stability of the medial and lateral columns. Plantar alignment of the metatarsal heads was also checked. A short leg splint was applied at the end of the procedure with the ankle in the plantigrade position. It was worn for two weeks, and then a short leg non-weight bearing cast was given for an additional four weeks. At six weeks, the percutaneous lateral Kirschner wires were removed. The patients were then shifted to full weight-bearing walking boot over four to six weeks. The internal fixation was removed only if it was painful. The indications for secondary tarsometatarsal arthrodesis

were severe pain and disability in patients with posttraumatic osteoarthritis.

Results

The duration of follow-up is at least 5 years. Patients' data has been summarized in Table 1.

Table 1: Summary of patient data

Case	Age	Metatarsal fractures	Cuboid injury	Cuneiform injury	No. of TMT jt. Involved	Reduction	Post traumatic OA	Implant failure	AOFAS score
1	47	No	No	No	5	Anatomical	No	No	73
2	70	Yes	No	No	5	Anatomical	No	No	85
3	52	Yes	No	No	5	Anatomical	No	No	77
4	65	No	No	No	5	Nonanatomical	No	No	65
5	38	Yes	Yes	Yes	5	Nonanatomical	Yes	No	60
6	59	Yes	No	No	5	Anatomical	No	No	97
7	36	Yes	No	Yes	5	Anatomical	No	No	90
8	64	Yes	Yes	Yes	5	Anatomical	No	Yes	90
9	32	No	No	No	2	Anatomical	No	No	75
10	34	Yes	Yes	No	5	Anatomical	No	No	80
11	41	Yes	No	No	2	Anatomical	No	Yes	65
12	56	No	No	Yes	5	Anatomical	No	No	80
13	22	Yes	No	No	2	Anatomical	No	No	85
14	34	Yes	No	Yes	2	Anatomical	No	No	85
15	36	No	No	No	5	Anatomical	No	No	90
16	56	No	Yes	No	3	Anatomical	No	Yes	97
17	30	Yes	No	Yes	5	Nonanatomical	Yes	No	60
18	45	Yes	No	No	2	Anatomical	No	No	77
19	51	Yes	No	No	5	Anatomical	No	No	85
20	21	Yes	No	No	3	Anatomical	No	No	80

Complications

3 patients (15 percent) had broken K- wires, 2 of these K- wires were across the third tarsometatarsal joint, and 1 was across the first. There were no postoperative infections. 1 open fractures and 1 fasciotomy wound required split-thickness skin-graft coverage, and 1 open fracture required flap coverage. A deep-vein thrombosis developed in 1 patient. No painful neuromas or cases of reflex sympathetic dystrophy, vascular insufficiency, or stress fracture were noted. 2 patients had developed posttraumatic arthritis out of which one had developed mild lateral subluxation once weight bearing resumed.

AOFAS Score: The average AOFAS midfoot score was 79.8 points (range 60 to 97 points), with patients losing points for mild pain, decreased recreational function, and the need to wear an orthotic in the shoe.

Discussion

Lisfranc injury account for 0.2 percent of all fractures.^{2,7,10} They were classified by Quénu and Küss²⁰ into homolateral, divergent, and isolated groups. The system was later modified by both Hardcastle et al.¹⁰ and Myerson et al.,⁴ who classified the injuries into total incongruity, partial incongruity, and divergent patterns. Although these classification systems were

descriptive, we thought that they were not prognostic and that they did not direct the treatment decisions. Therefore, we classified the injuries anatomically and treated operatively those that demonstrated instability or displacement or that involved ligaments only. Anatomical reduction and stable internal fixation has become a standard principle governing treatment of tarsometatarsal fracture-dislocations. Most authors have agreed that stable anatomical reduction leads to optimal results.^{1,3-5,7} Our study supports this concept as patients with anatomical reduction had a significantly better average AOFAS score ($p = 0.05$) and a significantly lower prevalence of secondary osteoarthritis ($p = 0.004$). The advantage of open reduction is that it allows direct visualization of the fracture-dislocation for the debridement of comminuted fracture fragments, soft tissue, and osteochondral debris. This facilitates precise reduction of the injury. There is controversy about which method of fixation is best. There are proponents of Kirschner-wire fixation,^{4,8-11} while others rely on screw fixation.^{1-3,5,7}

Most recent publications established that screw fixation should be the preferred fixation technique because it provides greater biomechanical stability than pinning alone.²⁷

We have used K- wires/combination of methods in all of our cases and only K-wires for 4th and 5th rays.

We wanted the strong threaded K- wires/screws to maintain the corrected joint position in order to allow the fractures and soft tissues to heal. Fractures healed well with this method, but ligamentous healing was probably less predictable. The purely ligamentous injuries did not always heal, and there was a trend toward an increase in degenerative changes. K-wires across the third tarsometatarsal joint failed the most often. This was most likely due to the close proximity of the third tarsometatarsal joint to the more mobile fourth and fifth tarsometatarsal joints.^{5,21} K-wires across the first tarsometatarsal joint had the second-highest prevalence of failure. It has been reported that the degree of posttraumatic arthritis is directly proportional to the degree of gross damage to the articular surface that had been identified at the operation and to the adequacy of reduction.^{4,22} Our study supports this observation as patients with anatomical reduction had a significantly lower prevalence of posttraumatic osteoarthritis ($p = 0.004$) and a significantly better average AOFAS outcome score ($p = 0.05$) than did patients without anatomical reduction. O.R. Marín-Peña et al. stated that lack of association between the extent of arthritis and clinical scores.²⁸

Primary arthrodesis for the treatment of Lisfranc injuries have been advocated by Granberry and Lipscomb²³ and by Bonnel and Barthélémy,²⁴ and this may be a better option for patients with purely ligamentous injury. However, new studies must be done to confirm this concept. There are numerous outcome measurements that can be used to evaluate the results of treatment.^{4,18,25,26} To measure functional outcome, we used the AOFAS midfoot scoring system as it is a well accepted and standard method for reporting results. Overall, the results of purely ligamentous injury or with non-anatomical reduction are not excellent. In summary, there were few significant differences between the groups, although the populations were small enough to hide many type-II errors (failure to see a difference between the outcomes of two groups [when there actually is a difference] because the sample size is small).

Conclusion

The trends lead to several conclusions. First, the overall outcomes after surgical treatment of Lisfranc injuries are good, and usually patients have few limitations. Patients lost points from the AOFAS midfoot scores because of mild pain, decreased recreational function, and the need to wear an orthotic in the shoe. Second, anatomical reduction remains important for a good long-term outcome. Finally, anatomical reduction may be less predictive of a good result in patients who have dislocation without fracture. It may be that injuries involving damage to the ligament-bone interface cannot heal with sufficient strength for the patient to regain stable long-term function. However, this question would best be answered by a prospective study.

References

1. Arntz, C. T.; Veith, R. G.; and Hansen, S. T., Jr.: Fractures and fracture-dislocations of the tarsometatarsal joint. *J Bone and Joint Surg* 1988;70-A:173-181, Feb. 1988.
2. Buzzard, B. M., and Briggs, P. J.: Surgical management of acute tarsometatarsal fracture dislocation in the adult. *Clin. Orthop* 1998;353:125-133.
3. Curtis, M. J.; Myerson, M. S.; and Szura, B.: Tarsometatarsal joint injuries in the athlete. *Am J Sports Med* 1993;21:497-502.
4. Myerson, M. S. Fisher, R. T. Burgess, A. R. and Kenzora, J. E.: Fracture dislocations of the tarsometatarsal joints: end results correlated with pathology and treatment. *Foot and Ankle* 1986;6:225-42.
5. Myerson, M.: The diagnosis and treatment of injuries to the Lisfranc joint complex. *Orthop Clin N A* 1989;20:655-64.
6. Myerson, M.: Injuries to the forefoot and toes. In *Disorders of the Foot and Ankle: Medical and Surgical Management*, edited by M. H. Jahss. Ed. 2, vol. 3, pp. 2233-2272. Philadelphia, W. B. Saunders, 1991.
7. Rosenberg, G. A., and Patterson, B. M.: Tarsometatarsal (Lisfranc's) fracture-dislocation. *Am J Orthop Supplement*: 7-16, 1995.
8. Blanco, R. P.; Merchán, C. R.; Sevillano, R. C.; and Martínez, L. M.: Tarsometatarsal fractures and dislocations. *J Orthop Trauma* 1988;2:188-94.
9. Goossens, M., and De Stoop, N.: Lisfranc's fracture-dislocations: etiology, radiology, and results of treatment. A review of 20 cases. *Clin Orthop* 1983;176:154-62.
10. Hardcastle, P. H.; Reschauer, R.; Kutscha-Lissberg, E.; and Schoffmann, W.: Injuries to the tarsometatarsal joint. Incidence, classification and treatment. *J Bone and Joint Surg* 1982;64B(3):349-56.
11. Tan, Y. H.; Chin, T. W.; Mitra, A. K.; and Tan, S. K.: Tarsometatarsal (Lisfranc's) injuries — results of open reduction and internal fixation. *Ann Acad Med Singapore* 1995;24:816-19.
12. R. S. Kuo., N. C. Tejwani, C. W. Digiovanni., S. K. Holt, S. K. Benirschke, S. T. Hansen And B. J. Sangeorzan: Outcome After Open Reduction and Internal Fixation of Lisfranc Joint Injuries. *J Bone and Joint Surg* 2000;82A(11):1609-18.
13. Coss, H. S.; Manos, R. E.; Buoncristiani, A.; and Mills, W. J.: Abduction stress and AP weightbearing radiography of purely ligamentous injury in the tarsometatarsal joint. *Foot and Ankle Internat* 1983;19:537-41.
14. Stein, R. E.: Radiological aspects of the tarsometatarsal joints. *Foot and Ankle* 1983;3:286-89.
15. Baker, S. P.; O'Neill, B.; Haddon, W., Jr.; and Long, W. B.: The Injury Severity Score: a method for describing patients with multiple injuries and evaluating emergency care. *J Trauma* 1974;14:187-96.
16. Gustilo, R. B., and Anderson, J. T.: Prevention of infection in the treatment of one thousand and twenty-five open fractures of long bones. Retrospective and prospective analyses. *J Bone and Joint Surg* 1976;58-A:453-58.
17. Jeffreys, T. E.: Lisfranc's fracture-dislocation. A clinical and experimental study of tarso-metatarsal dislocations and fracture-dislocations. *J. Bone Joint Surg* 1963;45-B(3):546-51.
18. Kitaoka, H. B.; Alexander, I. J.; Adelaar, R. S.; Nunley, J. A.; Myerson, M. S.; and Sanders, M.: Clinical rating

- systems for the ankle hindfoot, midfoot, hallux and lesser toes. *Foot Ankle Internat*1994;15:349-53.
19. Sangeorzan, B. J., and Swiontkowski, M. F.: Displaced fractures of the cuboid. *J Bone Joint Surg*1990;72-B(3):376-78.
 20. Quénu, E., and Küss, E.: Étude sur les luxations du métatarse. (Luxationsmétatarso-tarsiennes). Du diastasis entre le 1er et le 2e métatarsien. *Rev Chir*1909;39:1-72.
 21. Ouzounian, T.: Movements of the midfoot. Applications in trauma. Read at the Annual Meeting of the American Orthopaedic Foot and Ankle Society, Las Vegas, Nevada, 1989.
 22. Sangeorzan, B. J.; Veith, R. G.; and Hansen, S. T., Jr.: Salvage of Lisfranc's tarsometatarsal joint by arthrodesis. *Foot and Ankle*1990;10:193-200.
 23. Granberry, W. M., and Lipscomb, P. R.: Dislocation of the tarsometatarsal joints. *SurgGynecObstet*1962;114:467-69.
 24. Bonnel, F., and Barthélémy, M.: Traumatismes de l'articulation de Lisfranc. Entorses graves, luxations, fractures: études de 39 observations personnelles et classification biomécanique. *J Chir*1976;111:573-92.
 25. Engelberg, R.; Martin, D. P.; Agel, J.; Obremsky, W.; Coronado, G.; and Swiontkowski, M. F.: Musculoskeletal Function Assessment instrument: criterion and construct validity. *J Orthop Res*1996;14:182-92.
 26. Martin, D. P.; Engelberg, R.; Agel, J.; Snapp, D.; and Swiontkowski, M. F.: Development of a musculoskeletal extremity health status instrument: the Musculoskeletal Function Assessment instrument. *J Orthop Res* 1996;14:173-81.
 27. Lee CA, Birkedal JP, Dickerson EA, Vieta PA Jr, Webb LX, Teasdall RD. Stabilization of Lisfranc joint injuries: a biomechanical study. *Foot Ankle Int*2004;25(5):365–70.
 28. Marín-Peña, Oliver & Recio, Vitoria & Sanz Gómez, Tomas & Larrainzar-Garijo, Ricardo. (2012). Fourteen years follow up after Lisfranc fracture-dislocation: Functional and radiological results. *Injury*. 43 Suppl 2. S79-82. 10.1016/S0020-1383(13)70185-2.

<i>Conflict of interest: None</i>
<i>Funding: None</i>
<i>Cite this Article as:</i> <i>Bhesaniya R, Jesalpura .5 years follow up of open reduction and internal fixation of lisfranc injurie. Natl J Integr Res Med 2018; 9(5):44-50</i>