

## A Study Of Venous Drainage Of Thyroid Gland In 50 Cadavers

Dr.Kanani SD\*, Dr.Patel JP\*\*, Dr.Shah RK\*\*\*, Dr.Nirvan AB#, Dr.Dave RV##,

\*Assistant Professor in Anatomy, PS Medical College, Karamsad, Anand, \*\* Associate Professor in Anatomy, Smt.N.H.L.Municipal Medical College, Ahmedabad, \*\*\*Assistant Professor in Anatomy, GCS Medical College, Ahmedabad, # Associate Professor in Anatomy, B.J. Medical College, Ahmedabad, ##Assistant Professor in Anatomy, B.J.Medical College, Ahmedabad

**Abstracts: Introduction:** The thyroid gland is drain by mainly three vein, superior thyroid vein, middle thyroid vein, inferior thyroid vein. Some time fourth thyroid vein of kocher is also present. **Material and Methods:** Anatomy of venous drainage of thyroid gland was studied in 50 formalin embalmed cadaver, aged between 60 to 80 years. Dissection method was use for this study. **Result and Observation:** Middle thyroid vein found to be absent in 12 cases. No abnormality found in superior thyroid vein and inferior thyroid vein. Termination of all veins was traced. Thyroid vein of kocher was not found in any cases. **Conclusion:** A better understanding of the anatomic variability in superior thyroid vein, middle thyroid vein and inferior thyroid vein may be useful not only to minimize the risk of bleeding, but it also can help to perform a more accurate dissection with the goal of preserving the laryngeal nerves and parathyroid glands, especially because of its location and relationships with other adjacent structures. [Kanani SD NJIRM 2014; 5(1) : 88-91]

**Key Words:** Thyroid vein, Thyroid gland, Venous drainage

**Author for correspondence:** Dr.Sanjay Kanani, C/10,Anupam Colony, Opp: Chirag Dimond, Post: Thakkarbapa Nagar, Ahmedabad – 382350, E-mail: drsanjaykanani@gmail.com

**Introduction:** A Knowledge of the anatomy of the thyroid veins, is important because of its application in thyroid<sup>1</sup>, parathyroid and laryngeal surgery, in the transposition of myocutaneous flaps for reconstructions<sup>2</sup> and, particularly, in tracheostomies<sup>3, 4, 5</sup>. The Veins of thyroid gland form a plexus which lies beneath the true capsule if the thyroid gland and drained by via superior thyroid vein, middle thyroid vein, inferior thyroid vein. Superior thyroid vein form by deep and superficial tributaries corresponding to the arterial branches in upper part of the thyroid gland. It ends in the internal jugular vein or facial vein. Middle thyroid vein drains the lower part of the gland. The anatomy of middle thyroid vein is important because it is short, thin walled vessel, leaving the middle of gland and directly coursing laterally to pass in front of or behind the carotid artery and enter the internal jugular vein, it is first vessel encountered in thyroidectomy and merits careful ligation. Inferior thyroid vein drain the inferior poles. The inferior thyroid vein leave the lower border of gland and pass through the loose fascial space to join with the brachiocephalic veins posterior to the manubrium. The frequency of indications for tracheostomy in emergency rooms and intensive care units is increasing and thus the occurrence of haemorrhagic events is increasing likewise. Krausen<sup>4</sup> reports that many surgeons have been dismayed at the occurrence of massive haemorrhages caused by accidental section of the inferior thyroid vein during emergency or even

routine tracheostomies. Buguet-Brown et al.<sup>3</sup> report the case of cataclysmic acute haemorrhage caused by lesion of the inferior thyroid vein in percutaneous tracheostomy. Muhammad et al.<sup>6</sup> report 4.8% unsuccessful tracheostomies where haemorrhages were caused by vascular lesions.

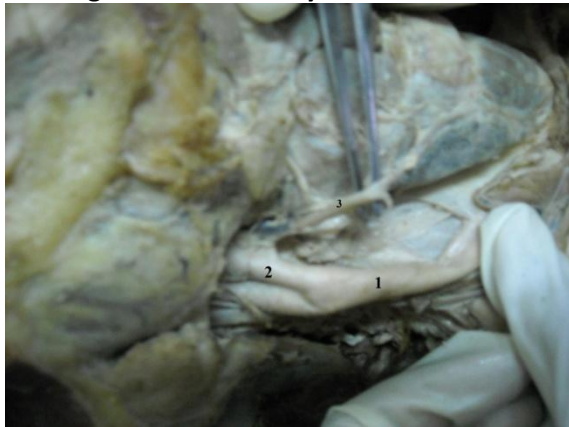
**Material and Methods:** This study was conducted on 50 cadavers in the dissection laboratory with age range of 60 to 80 years. The cadavers were embalmed through carotid arterial perfusion or femoral arterial perfusion with formaldehyde solution, spirit, water, glycerine, phenol crystal, eosin and then preserved in weak formalin solution before dissection. The dissection was performed in dissection laboratories of Smt.N.H.L.Municipal Medical College, B.J.Medical College, AMC MET Medical College, Ahmedabad, Gujarat, India during period of 2008 to August 2011. Permission of Head of department from individual college was taken for cadaveric dissection.

**Method:** Dissection method was employed for this study. The infrahyoid group of muscles were identified and reflected. The sternocleidomastoid muscle and superior belly of omohyoid were displaced laterally. After reflecting the sternohyoid, sternothyroid muscles the thyroid gland was exposed. The fascia was removed from the lobes of the thyroid gland exposing its arteries and veins. Veins of thyroid gland were trace form its commencement to termination. For complete

dissection of the inferior thyroid veins, the sternum, the upper ribs and the clavicle were reduced.

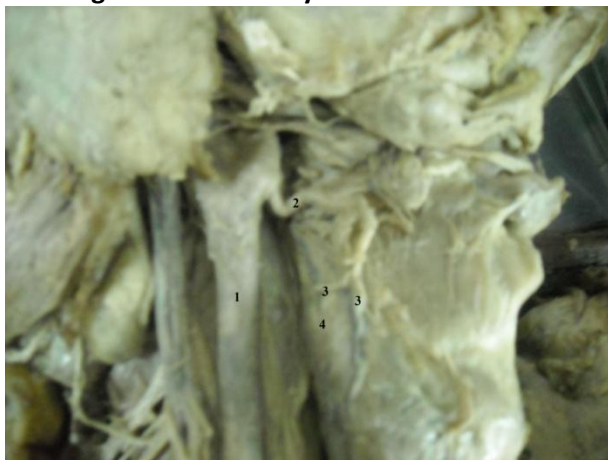
**Results:** Superior thyroid vein was found to be present in all samples and on both sides (100%). In all samples superior thyroid vein was terminated in internal jugular vein. Table 1 shows presence of all three thyroid vein in present study.

**Figure.1 : Middle thyroid vein is absent.**



1 – Common carotid artery, 2 – External carotid artery, 3 – Superior thyroid artery.

**Figure 2: Middle thyroid vein is absent.**



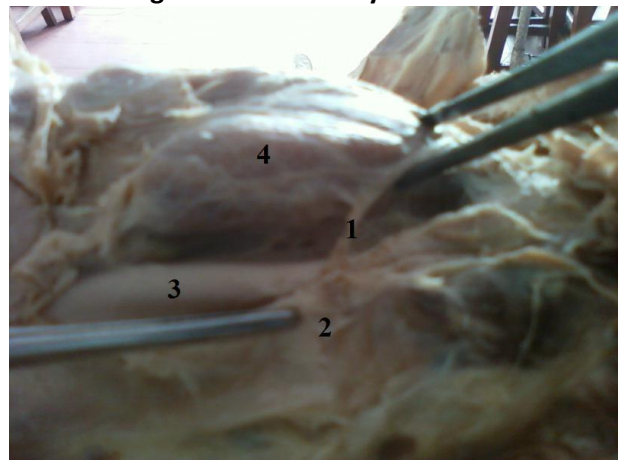
1 – Common carotid artery, 2 –Superior thyroid artery, 3 – Glandular branches of superior thyroid artery, 4 – Thyroid gland

Middle thyroid vein, located laterally to the thyroid gland just above the inferior thyroid artery, was absent in 24% of the dissected sides. It was present bilaterally in 32 cases (64%), present on the right side while absent on the left in 7 cases (14%) and absent on the right side while present on the left in

5 cases (10%). It was absent bilaterally in 6 cases. In all founded samples middle thyroid vein was terminated in internal jugular vein. Table 2 shows presence of middle thyroid vein in present study.

Inferior thyroid veins were present in all samples. Numbers of inferior thyroid veins were two in all cases (100%). Inferior thyroid veins were terminated in brachiocephalic vein. No any other abnormality found in superior thyroid vein and inferior thyroid vein. Thyroid vein of kocher was not found in any cases.

**Figure 3 : Middle thyroid vein.**



1 – Middle thyroid vein, 2 – Internal jugular vein, 3 – Common carotid artery, 4 – Thyroid gland

**Table.1** Presence of thyroid veins

Thyroid veins	Right side N (50)	Left side N (50)	Total
Superior thyroid vein	50	50	100
Middle thyroid vein	39	37	76
Inferior thyroid vein	Present in all cases. Number of inferior thyroid vein were two in all cases		100

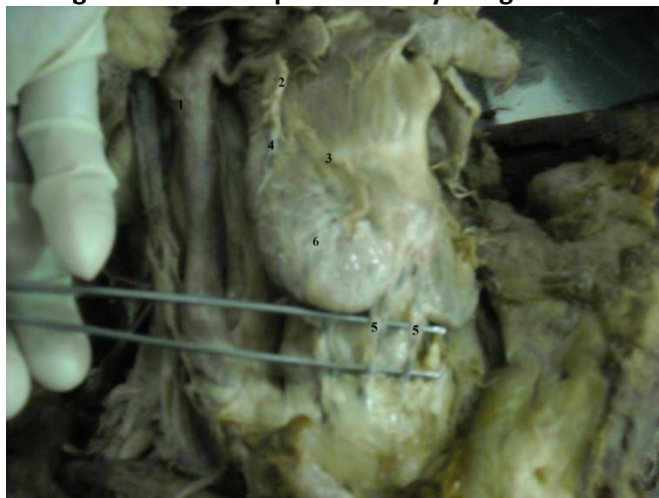**Discussion:** Superior thyroid vein was found in all samples and on both sides, confirming the references cited in the literature studied. Chevrel et al.<sup>7</sup> report cases of two terminations but do not state whether the veins are independent; Remmert et al.<sup>8</sup> report that in 20% of cases this vein is not single. Chevrel et al. mentioned the possibility of

two terminations. For Chevrel et al.<sup>7</sup> the termination may occur directly in the internal jugular vein (10%), or through the linguofacial trunk (56%) or even in both (33%). For Remmert et al.<sup>8</sup> the vein joins the facial vein in 43% of cases and in other cases goes directly to the internal jugular vein. Oszukowski and Kosinski<sup>9</sup> report the junction with the lingual and facial veins in 44% and Shima et al.<sup>2</sup> found an association of the three veins in 46.6% and a combination with the facial vein in 6.9%.

Middle thyroid vein for Chevrel et al.<sup>7</sup> report its presence in 29%, while for Shima et al.<sup>2</sup> the frequency is 55.2%. In our study middle thyroid vein was absent in 24% of the dissected sides in cadaveric dissection.

Inferior thyroid vein was always present in the study of Krausen<sup>4</sup>, Lazaro da Silva et al.<sup>1</sup> and Moriggl and Pomaroli<sup>10</sup>. Using computerised tomography, Belli et al.<sup>11</sup> found this artery in 90% of cases. Chevrel et al.<sup>7</sup> did not mention any absence, and concluded that this vein found it in all cases. In our study this vein was present in all cases.

**Figure 4: Vascular pattern of thyroid gland**



1 – Common carotid artery, 2 – Superior thyroid artery, 3 – Anterior glandular branch of superior thyroid artery, 4 – Posterior glandular branch of superior thyroid artery, 5 – Inferior thyroid vein, 6 – thyroid gland

There were differences in the number of veins found by these authors:

– Krausen<sup>4</sup> - one (10%), two (10%), three (40%), four (20%), five (20%);

– Lazaro da Silva et al.<sup>1</sup> - one (81.5%) and two (18.5%);

– Belli et al.<sup>11</sup> - one (38%), two (33%), three (16%), four (3%);

– Moriggl and Pomaroli<sup>10</sup> - one (60.7%), two (30.3%), three (8.4%), four 0.6%.

In our study numbers of veins were two in all cases. (Figure.4)

Table 2 & 3 shows a comparison of presence and numbers of thyroid veins observed in present study and previous studies.

**Table 2: Comparison of presence of thyroid veins observed in present and previous studies**

Thyroid veins	Presence of thyroid veins	
	Present study	Other studies
Superior thyroid vein	100 %	100 %
Middle thyroid vein	76 %	Chevrel et al. – 29 % Shima et al. – 55.2 %
Inferior thyroid vein	100 %	Krausen, Lazaro da Silva et al., Moriggl and Pomaroli – 100%, Belli et al. – 90 %

**Table 3: Comparison of number of Inferior thyroid vein observed in present and previous studies**

Inferior thyroid vein	One (%)	Two (%)	Three (%)	Four (%)	Five (%)
Present study	00	100	00	00	00
Krausen	10	10	40	20	20
Lazaro da Silva et al.	81.5	18.5	00	00	00
Belli et al.	38	33	16	03	00
Moriggl and Pomaroli	60.7	30.3	8.4	0.6	00

**Conclusion:** A better understanding of the anatomic variability in superior thyroid vein, middle thyroid vein and inferior thyroid vein may be useful not only to minimize the risk of bleeding, but it also can help to perform a more accurate dissection with the goal of preserving the laryngeal nerves and parathyroid glands, especially because of its location and relationships with other adjacent structures. The inferior thyroid veins and

their multiple tributaries are the ultimate guardians of the cervical trachea. Deeply embedded in the pretracheal fat pad, this plexus of veins is consistently encountered during low tracheostomy that accompanies conservation laryngeal procedures as well as in tracheal reconstruction. In a high tracheotomy, the handling of the thyroid isthmus is simplified by an appreciation of these veins. Even cricothyrotomy is potentially complicated by hemorrhage subsequent to a tear in a tributary of the inferior thyroid venous system. Iatrogenic injury can be avoided with knowledge as well as possible anatomic and pathological variation that may exist. All diagnosis and surgical procedures involving suprasternal fossa, tracheostomy in particular, require a careful approach.

**Acknowledgment:** We sincerely thankful to our Professor and Head of the Department of Anatomy, Smt.N.H.L. Municipal Medical College, B.J.Medical College and AMC MET Medical College, Ahmedabad, who not only acted as guide but also as a mentor for successfully completing this research.

#### References:

1. Lázaro da Silva A, Delorenzo S, Pelaquim AF, Freire MTG, Rezende Neto JB. Anatomia das veias tireóideas inferiores: aplicação cirúrgica. *Arq Bras Med.* 1989; 63: 243–246.
2. Shima H, Von Luedinghausen M, Ohno K, Michi K. Anatomy of microvascular anastomosis in the neck. *Plast Reconst Surg.* 1998; 101: 33–41.
3. Buguet-Brown ML, Favier JC, Da Conceição M, Pitti R. Acute severe hemorrhage by a wound of the inferior thyroid vein during percutaneous tracheostomy. *Ann Fr Anesth Reanim.* 2001; 20: 304–305.
4. Krausen AS. The inferior thyroid veins. The ultimate guardians of the trachea. *Laryngoscope.* 1976; 86: 1849—1855.
5. Muhammad JK, Major E, Patton DW. Evaluating the neck for percutaneous dilatational tracheostomy. *J Craniomaxillofac Surg.* 2000; 28: 336–342.
6. Muhammad JK, Major E, Woods A, Patton DW. Percutaneous dilatational tracheostomy: haemorrhagic complications and the vascular anatomy of the anterior neck. A review based on 497 cases. *Int J Oral Maxillofac Surg.* 2000; 29: 217–222.
7. Chevrel JP, Hidden G, Lassau, JH, Alexandre JH, Hureau J. Le drainage veineux et lymphatique du corps thyroïde. *J Chir (Paris).* 1965; 90: 445–464.
8. Remmert S, Majocco A, Gehrking E. Der neurovaskuläre infra-hyoidale muskelfaszienlappen: anatomisch-topographische untersuchung der innervations und gefäßversorgung. *HNO.* 1995; 43: 182–187.
9. Oszukowski P, Kosinski H. Opening of the middle thyroid vein into vertebral vein in the fetus. *Przegl Lek.* 1996; 53: 634–635.
10. Moriggl B, Pomaroli A. Das Mündungsverhalten der vena (e) thyroidea (e) inferior (es). *Ann Anat.* 1992; 176:389–393.
11. Belli AM, Ingram CE, Heron CW, Husband JE. The appearance of the inferior thyroid veins on computed tomography. *Br J Radiol.* 1988; 61: 125–127.

Conflict of interest: None
Funding: None