

Incidence of the Third Head of Biceps Brachii in Western Indian Population

Padma Varlekar, Nilam K. Meghatar, C. D. Mehta

Department of Anatomy, Government Medical College, Surat, Gujarat

Abstracts: Background: Biceps brachii is muscle of the flexure compartment of the arm. Anatomic variation of the biceps brachii muscle is one of the most variations in upper limb. The most common variation is a third head, but four, five or even seven heads have been reported. This variation may present as a group of accessory fascicles arising from the coracoids process, Pectoralis major tendon, proximal head of the humerus, articular capsule of the humerus or from humerus itself. Aim: to report the occurrence of the third head of biceps brachii in a sample Indian population along the western region of India, and to compare with other racial groups from previous study. Method: A prospective evaluation was conducted on cadavers at Govt. Medical College, Surat in Gujarat. The upper limbs of 32 cadavers were dissected and observed for variation in the origin and insertion of the biceps brachii muscle bilaterally. Result: A third head for the biceps brachii muscle were found in six arms. The variations were bilaterally. The short & long head were normal however third head was humeral origin and also arose from pectoralis major tendon and inserted into the conjoined tendon of the biceps brachii muscle as usual. The variant was present in three males (9.37%, n=32). Conclusion: Awareness of incidence of this variation is necessary to avoid complication during pre-operative procedure or surgeries in the upper limb. [Varlkar P NJIRM 2011; 2(4) : 65-67]

Key Words: anatomical variants, biceps brachii muscle, third head of biceps brachii, pectoralis major, humeral head.

Author for correspondence: Dr. Padma Varlekar, Assistant Professor, Anatomy Department, Government medical College, Majura Gate, Surat, India. Email: padmavarlekar@yahoo.com

Introduction: The Biceps brachii is one of the muscle of anterior compartment of the upper arm. It is characteristically described as a two headed muscle, Short head & Long head. Short head originates from the tip of coracoid process of the scapula & Long head originates from the supraglenoid tubercle of the scapula. Distally these two head join to form a common tendon which insert in to the posterior rough part of the radial tuberosity & through the bicipital aponeurosis to the subcutaneous posterior border of ulna. In terms of the number & morphology of its head, the biceps brachii muscle is one of the most variable muscle in human body¹. The most common variation is a third head, but four, five or even seven heads have been reported². There are reports describing supernumerary bicipital heads, ranging from 3 to 7. Among them 3 headed variant represents the most common type that has been reported with a prevalence ranging from 7.5% - 18.3%. Testut (1902) has described the biceps brachii muscle as one of the muscle with most frequent anatomic variation. This variation may present as a group of accessory fascicles arising from the coracoids process, Pectoralis major tendon³, proximal head of the humerus, articular

capsule of the humerus or from humerus itself. This last variation is also known as the humeral head of the biceps brachii muscle. Several authors have reported the presence of the anomaly with a varying frequency, according to the studied population, Chinese 8%, European White 10%, African Black 12% & Japanese 18%.¹

Material and Methods: The upper limbs of 32 cadavers were dissected and observed for variation in the origin and insertion of the biceps brachii muscle bilaterally. Cadaver was placed in 10% formalin for adequate preservation. The dissection of both upper extremities (right and left) of the body was carried out according to the Instruction by Cunningham's Manual of practical Anatomy. Each upper limb was dissected by a longitudinal incision at the anterior aspect of the arm from the level of the acromion to the elbow junction. The skin, subcutaneous fat, & fascia were removed to expose the biceps brachii muscle. The nerve & blood supply of each head were carefully examined. The findings were photographed & length, width of the muscle was measured in centimeters.

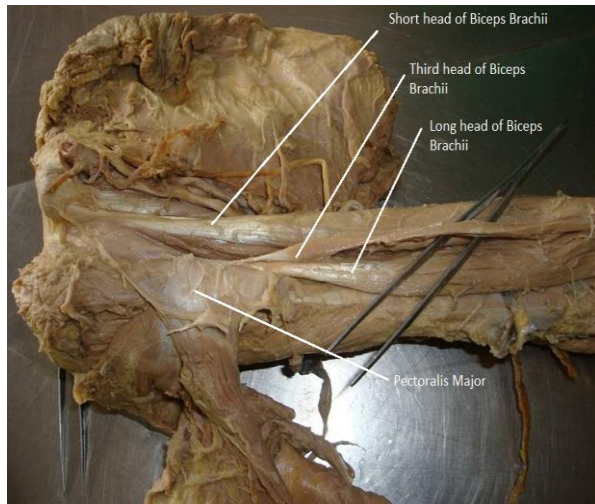


Figure 1: Showing short, long head and third head of biceps brachii originating from tendon of pectoralis major muscle.

Result: On the ventral aspect of the upper arm, during dissection the additional head of muscle was found bilaterally. The short & long heads of the biceps brachii muscle had their usual origin, insertion & courses. However the additional head of muscle originated from the pectoralis major tendon in one subject and from shaft of humerus (humeral head) in two subjects. We named it the third head of biceps brachii muscle which observed bilaterally. Additional head from the pectoralis major tendon was started as a thin tendon and then changed into 2cms wide muscle belly and travelled between the interval of the long and short head. Anteriorly the upper part of the third head of the biceps was undercover of distal part of the pectoralis major & posteriorly the brachialis muscle & humerus on the lower part, laterally the long head of biceps muscle, medially the median nerve, humeral artery, vein, lymphatic vessels. Humeral head was arising from the anteromedial aspect of the mid shaft of the humerus below the insertion of coracobrachialis and above the origin of brachialis muscle form 2cms wide muscle belly. In both cases the third head descend and merged with the other two heads to form a common tendon and was inserted into radial tuberosity. The innervations & blood supply of this accessory head were from the musculocutaneous nerve & the brachial artery, respectively. A total of 64 arms of 32 subjects were studied. Six arms were found to have a three headed biceps brachii muscle. The

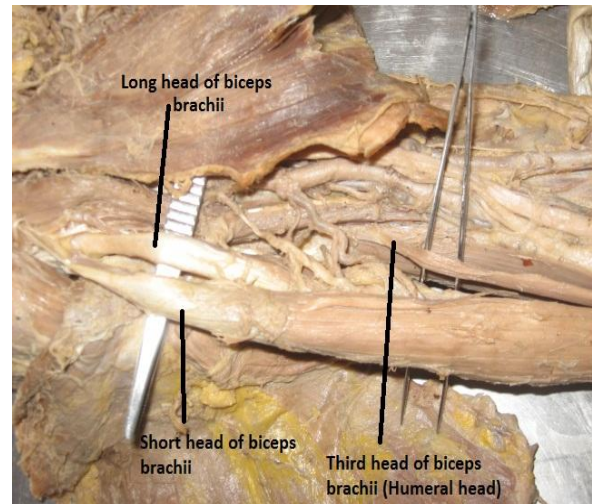


Figure 2: Showing third head of biceps brachii

originating from Humerus (Humeral Head) after retracting short and long head of biceps.

variant was present in three males (9.37%, n=32). It was found in three male subjects in right and left arm bilaterally.

Discussion: Gray's Anatomy reported the incidence of this variation to be as much as 10%, and this agrees with the observation in White European⁴. Study group for Black reported an incidence of 21.5%. So it seems that the incidence varies among ethnic groups. The appearance of these variants to evolutionary or racial trends⁵. Male cadavers were found to have this variant in 31.2% of the cases he studied and reported that the third head of biceps brachii was rare in whites and relatively high among blacks⁶. The incidence of third head of biceps brachii in 7.1% cases reported from southern coast of India⁷. In our study the incidence of biceps brachii 9.37% (six of 64) of male cadavers were found to have the third head of biceps brachii bilaterally. The aim of this study is to report the occurrence of the third head of biceps brachii in a sample Indian population along the western region of India, and to compare with other racial groups from previous study. Several authors have demonstrated that male is affected predominantly². In terms of the number and morphology of its head the biceps brachii muscle is one of the most variable muscles in the human body¹. The most common variation is a third head, but four, five or seven heads have been reported. The accessory head of Biceps brachii are classified

according to their location as superior, inferomedial and inferolateral humeral heads¹. Most of the accessories head of Biceps brachii belong to these 3 groups, rare variation have also been reported. The biceps brachii muscle is most frequent Anatomic variations⁸. This variation may present as a group of accessory fascicles arising from the coracoids process, Pectoralis major tendon³, proximal head of the humerus, articular capsule of the humerus or from humerus itself. The incidence of the third head of biceps brachii muscle has been reported in several articles. Embryological observation described this variation of the third head of Biceps brachii as a portion of the brachialis muscle supplied by the Musculocutaneous nerve, in which its distal insertion has been translocated from the ulna to radius and may enhance primarily supination and secondary flexion of the forearm⁸. The third head of the Biceps brachii muscle originating at the level of the lesser tuberosity of the humerus, running parallel to the short head of the Biceps brachii, that head to be dissected for proper visualization of the underlying articular capsule, during a standard arthrotomy with T-plasty capsulorrhaphy, in a case of chronic shoulder dislocation. It may affect the strength of elbow flexion and may also compress the neurovascular structure⁹.

Conclusion: The third head of biceps brachii may be an incidental finding at autopsy or during routine anatomical dissection. Unless symptomatic, the third head of biceps brachii may not be detected in clinical studies. An accessory head of biceps brachii muscle may become significant in pre-operative diagnostic procedure & during surgery of the upper limb. The occurrence of the third head of biceps brachii muscle is relatively high in male compare to female and quite significant in the Indian population.

References:

- Rodriguez- Niedenfuhr M, Vazquez T, Choi D, and Parkin I, Sanudo JR. Supernumerary humeral heads of the Biceps brachii muscle revisited. Clin Anat 2003, 16: 197-203.
- Asvat, E Candler, P & Sarmiento, E. High incidence of the third head of biceps brachii in South African population. J. Anat, 182:101-104, 1993.
- Sargon. M.F. Tuncali, D & Celik, H.H. An unusual origin for the accessory head of Biceps brachii muscle. Clin Anat, 9(3): 160-162, 1996.
- Bergman, R.A. Thompson, S.A. & Aifi. A.K. Catalogue of human variation. Munich, Urban & Schwarzenberg, 1984. P 27-30.
- Kopuze C.; Sancack, B. & Ozbenli, S. On the incidence of the third head of bicep brachii in Turkish neonates and adult. Acta Anat Nippon, 74(3):301-5, 1999.
- Khaledpour C. Anomalies of the biceps muscle of the arm]. Anat Anz 1985; 158:79- 85. German.
- Rai R, Ranade A V Third head of biceps brachii in an Indian population. Singapore Med J 2007; 48 (10): 931.
- Testut, L Tratado de Anatomia Humana. Barcelona, Salvat 1902. P 1022
- Warner, J. P.; Palleta, G. A. & Warren, R. F. Accessory Head of Biceps brachii, Case report demonstrating clinical relevance. Clin.Ortho. Res., 280:179-81, 1992.