

Study of variation in atypical foramina of dry human skull

Dr.Praveen R Singh* , Dr.C.J.Raibagkar**

*Associate Professor, **Ex.Professor & Head,Anatomy Department, Pramukhswami Medical College, Karamsad

Abstract : Foramina or openings in the skull are very important as they allow passage of important structures like nerves and blood vessels through them. Various people have studied variations in foramina as these variants have been found to be related to many disease states, which can be either acquired or inherited. Out of various skull foramina, we studied three atypical foramina named lacrimal, emissary sphenoidal & parietal in 103 dried human skulls. We looked for their presence unilaterally/bilaterally, their numbers, dimension and comparison bilaterally. Lacrimal foramen was absent bilaterally in 41% of the skulls while present unilaterally in 29% with an average size of 0.86 mm. Emissary sphenoidal foramen was absent bilaterally in 49% of the skulls, present unilaterally in 20% with an average size of 0.87 mm. When compared bilaterally 11% of the skulls showed difference of more than 0.5mm in emissary sphenoidal foramen while it was multiple in 2% of the skulls studied. Parietal foramen was absent bilaterally in 20% of the skulls while it was present unilaterally in 29% with an average size of 0.91 mm. When compared bilaterally 15% of the skulls had difference of more than 0.5mm. The foramen studied showed variation in different parameters observed which might be due to genetic, nutritional, environmental differences or some disease conditions. Knowledge of presence and variation in its anatomical parameter can be crucial for surgeons and anesthetists.

Key-words: parietal foramen, lacrimal foramen, emissary sphenoidal, anatomical variation, skull

Corresponding Author: Dr.Praveen R Singh, Associate Professor, Anatomy Department, Pramukhswami Medical College, Karamsad-388325, Gujarat, India. Email: praveenrs@charutarhealth.org

INTRODUCTION: Variations can be found in every system in the body and can rarely be labeled as abnormal.¹ Study of minor variants has been used for anthropological studies but many of these variations have also been found to be associated with a number of clinical conditions.² Skull, the most complex bony structure in the body houses the most vital organ, the brain. Minor variations in the ossicles, foramina and ridges of the cranium have aroused the curiosity of anatomist worldwide for many decades and for many reasons.

Foramina or openings in the skull are very important as they allow passage of important structures like nerves and blood vessels through them. Variations in foramina have been studied by various people as these variants have been found to be related to many disease states like osteopetrosis, osteoporosis, cruro syndrome, neurofibromatosis, brachymicrocephaly and mental retardation^{3,4,5,6} which can be either acquired or inherited. Studies on the variations have been conducted on dry human skull, but modern day researcher have the

advantage of technical advances particularly in the radiological techniques like CT Scan, MRI, PET etc to study these variations in living subjects as well. These studies have revealed differences in the size, shape, numbers and even locations of different foramina in different ethnic groups, age and sex in dry skull as well as living body. The knowledge of normal and abnormal variant in the skull foramina is important for various treatment modalities. Family studies on some of these variant foramina have shown them to be inherited usually by a dominant gene.⁷

Out of various skull foramina, three foramina named lacrimal, emissary sphenoidal & parietal are considered to be atypical foramina with expected variation in their presence & size, but have not been studied much and there is no availability of literature from Gujarat region.

Lacrimal foramen is an opening on the greater wing of the sphenoid bone near the superior lateral angle of the superior orbital fissure. This foramen acts as

a conduit between the middle cranial fossa and the orbit as it provides a route for an anastomosis between the orbital branches of the middle meningeal branch of the ophthalmic artery.^{8,9} It also has been referred to as the anastomotic foramen (Moore 1985), the lacrimal foramen (Basmajian, 1980), the foramen meningo-orbitale (Royle 1973), the foramen of Hyrtl (Lasjaunials, 1981) as the cranio-orbital foramen (Diamond 1990), as mentioned by Chritos G. and Mratin D. Cassel¹⁰.

Emissary sphenoidal foramen or foramen of vesalius is also known for its inconstant presence. This is a small, variable but consistently symmetrical structure located anteriomedial to the foramen ovale and lateral to the foramen rotundum and the vidian canal. It transmits an emissary vein through which the cavernous sinus and pterygoid plexus communicate. The symmetry of this foramen is such that asymmetry signifies abnormality, which might include invasion by nasopharyngeal melanoma, angiofibroma, neurofibromatosis and carotid cavernous fistula with drainage through emissary vein.¹¹

Parietal foramen may occasionally be absent on one or both the sides and have been known to be present in 60% of skulls.¹² These foramina are believed to be the remains of the fetal sagittal fontanelle. The parietal foramina are occasionally greatly enlarged. It is present in the parietal bone very close to the sagittal border at the posterior end. It allows passage of emissary vein that connects the superior sagittal sinus with the veins of the scalp.

Keeping in mind the surgical and clinical associations of skull foramina and poor availability of study on above said foramina, this study was undertaken to know the variation of these atypical foramina in the dry human skull of Gujarat region.

MATERIAL AND METHODS: The study was conducted in the department of anatomy, Pramukhswami Medical College, Karamsad. It included 103 dry adult skulls of human origin, collected from the department of anatomy and forensic medicine of various medical colleges in

Gujarat, the north-west region of India. The materials included in the study were dry adult skulls, compass, calipers, steel measuring tape, probe & camera. All the skulls collected were completely macerated, defatted, cleaned and made dry. These skulls belonged to adult age group. All the skulls were studied for their completeness. The presence and bilateral symmetry of the three paired foramina i.e. lacrimal, emissary sphenoidal & parietal were noted on both the sides. All the foramina were measured. Measurement was taken along the maximum diameter. Absence or presence of multiple foramen and the presence of abnormal foramina if any was noted. The measurements of the foramina were taken in the longest axis and probe was used to confirm potency of foramina and canals to rule out false passage. The results were compared with those obtained by other workers as cited in the literature.

RESULTS: In our study, lacrimal foramen was absent bilaterally in 41% of the skulls studied. In 29% of the skulls, it was present on only one side. The average size of foramen on right side was 0.82 mm while on the left side it was 0.94 mm, the total average size being 0.86 mm. The largest foramen measured 1.8 mm in size while the smallest one was 0.3 mm. When compared bilaterally 9% of the skulls showed difference of more than 0.5 mm. The lacrimal foramen was multiple in none of the skulls observed.

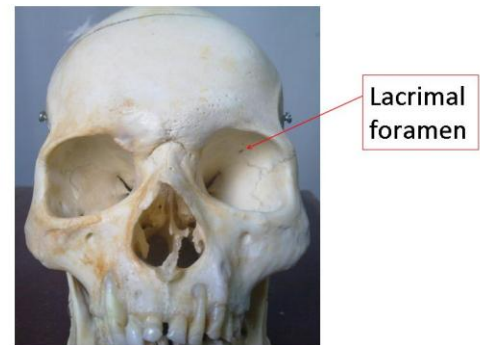
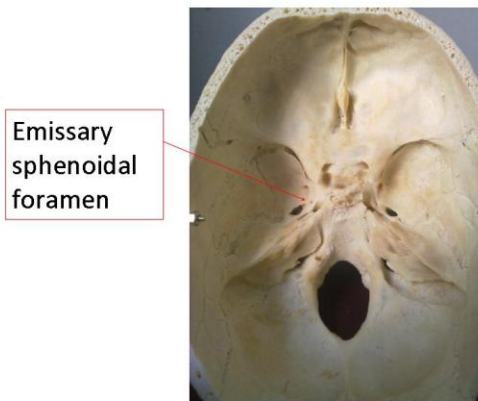
Emissary sphenoidal foramen was absent bilaterally in 49% of the skulls studied. In 20% of the skulls, the foramen was present on only one side. The average size of foramen on right side was 0.79 mm while on the left side it was 0.96 mm, the total average size being 0.87 mm. The largest foramen was 3.3 mm in size while the smallest was 0.3 mm. When compared bilaterally 11% of the skulls showed difference of more than 0.5mm. In addition, the emissary sphenoidal foramen was multiple in 2% of the skulls studied.

Parietal foramen was absent bilaterally in 20% of the skulls studied. In 29% of the skulls, the foramen was present on only one side. The average size of foramen on right side was 0.87 mm while on the

left side it was 0.95 mm, the total average size being 0.91 mm. The largest foramen studied was 1.5 mm in size while the smallest one was 0.3 mm in dimension. When compared bilaterally 15% of the skulls showed difference of more than 0.5 mm. Parietal foramen was multiple in none of the skulls observed.

DISCUSSION: Various workers have tried to explore the qualitative as well quantitative variation in the skull using geographically bound population as material and tried to make use of that information for various purposes. The variations of skull foramina

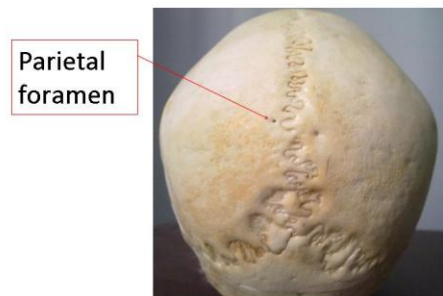
D Cassell¹⁰ in their study of lacrimal foramen in 50 adult dry skulls proved the inconsistent presence of this foramen. They could identify the foramen in half of the skulls studied. More than one foramen was found in 15% of the cases. Kwiatkowski J et al¹⁵ found multiple foramina in 4% of cases while we have found none of the skulls with multiple lacrimal foramen. Krishnamurthy A et al⁹ in their study found it to be present in 80.4% of the population while Kwiatkowski J et al¹⁵ found the incidence in his study to be 28%.



are important for their disease associations and surgical implications. In general, research in the earlier stages was descriptive, with little inclusion of sophisticated techniques. With the technical advances in the field of radio anatomy, voluminous amount of research has been done in skull base foramina using high-resolution computerized tomography, magnetic resonance imaging and positron emission tomography.^{13, 14}

Therefore, in the skulls that we studied, lacrimal foramen was present on the greater wing of sphenoid bone near the superolateral angle of the superior orbital fissure. When present it may provide a route for an anastomotic branch between orbital branch of middle meningeal artery and recurrent meningeal branch of ophthalmic artery.

We found lacrimal foramen to be absent bilaterally in 42 of the 103 skulls while it was present unilaterally in 30 skulls. None of the skulls had multiple foramina. Similar to our results, Bergman et al¹² found the foramen to be bilaterally absent in 28% with the unilateral presence in 31%. The dimension of foramen as obtained by them ranged from 0.3 mm to 4 mm while we had the values ranging from 0.3 to 1.8 mm with an average of 0.86 mm. 9% of the skulls showed more than 0.5 mm difference bilaterally. Christos Georgiou and Martin



Emissary sphenoidal foramen has been described as closed and open type by Kodama K et al¹⁶ who studied this foramen in Japanese juvenile and adult

skulls. The presence of this foramen was detected in 55% of juvenile and 21.75% of adult skulls. No difference was found in male or female and between left and right side. They noted that skull with two foramina followed it and those with three were least frequent. We found the foramen to be 0.87 mm in average diameter. Similar size is mentioned in literature. It is usually 1 mm in diameter but may be very slightly larger in some. In a study by Boyd,¹⁷ the foramen was found to be larger than 1 mm in about 5 % of cases. He found the foramen to be bilateral in 15% of cases and unilateral in about 22%. Gupta N et al¹⁸ in their study found the incidence of the foramen to be 32.85% and the incidence of bilateral and unilateral foramen vesalius was 22.85% and 20% respectively. We found the foramen to be absent bilaterally in 49% skulls with unilateral presence in 20% skulls. We have also obtained two skulls with multiple foramina.

Kodama K et al¹⁶ in their study of Japanese juvenile and adult skulls, found the foramen to be present in 55% of juvenile and 21.75% of adult skulls. They did not find any difference on left or the right side. Lanzieri C F et al¹¹ have found the foramen to be 1 mm to 2 mm in size. Ginsberg L E et al¹³ have found the foramen to be present, at least unilaterally in 80% of skulls evaluated by mean of high resolution CT. In our study 11% of the skulls showed more than 0.5 mm difference bilaterally.

Many researchers have studied the enlarged parietal foramina and tried to understand its evolution and significance.¹⁹ Many studies indicate an association between enlarged parietal foramina and disease states either hereditary or acquired. The familial occurrence is reported to be autosomal dominant.⁶ Other malformations which have been associated with parietal foramina are clavicular hypoplasia²⁰ brachymicrocephaly and mental retardation⁶, cerebral venous and cortical anomalies.⁵ All these associations suggest that aberrant vascular evolution during fetal development may affect cerebrovascular, brain or skull development. Size of parietal foramen more than 5 mm is significant for underlying disease in brain parenchyma and vasculature,⁵ but none of our skulls showed foramina of this size. Difference of more than 0.5 mm when

observed bilaterally was observed in 15 skulls in our study, which has striking similarity to the study done by Ronald Bregman.¹²

CONCLUSION: Amongst the three foramina, that we observed, there was maximum variability in the parameters of emissary sphenoidal foramen. It was absent bilaterally in 49%, present unilaterally in 20%, bilaterally different dimension in 11% & multiple in 2%.

Noting the important variation collectively in the three atypical foramina for being absent bilaterally, percentage wise distribution was emissary sphenoidal (49%), lacrimal (41%) & parietal (20%). Distribution of foramina which were present unilaterally in the skull were lacrimal (29%), parietal (29%) & emissary sphenoidal (20%). Foramina showing maximum number of bilaterally different sized foramina were parietal (15%), emissary sphenoidal (11%) & lacrimal (9%).

As foramen provide passage to the structures so wherever they are absent, there are chances that structure passing through them is also absent or passes through some other foramen. Similarly, if foramen is multiple there are chances that more than one related structures pass through them.

Knowledge of presence and variation in its anatomical parameter can be crucial for surgeons and anesthetists. Information on size & symmetry is important because of advancement in techniques such as MRI & CT scan making difficult diagnosis of pathological conditions of skull foramina possible. Variable shape, size, location & numbers of foramina in general have been found to be normal as well as associated with various clinical conditions.

Few of our findings are comparable with literature while some of the findings noted cannot be compared with the available literature to show that skulls of Gujarat origin have variations in measurement and number of foramina. The variation might be due to genetic, nutritional or environmental differences. Therefore, further study is required to find out probable causes of variation

in different foramina when compared with available literature.

REFERENCES:

1. Berry A.C., Berry R.J. Epigenetic variation in the human cranium. *J. Anat.* 1967;101: 361 - 379.
2. Wood J. F. The non-metrical morphological characteristic of the skull as criteria for racial diagnosis. Part 1. General discussion of the morphological characters employed in racial diagnosis. *J. Anat.* 1931; 65:179 - 195.
3. Richardson ML, Helms CA, Vogler JB 3d, Genant HK. Skeletal changes in neuromuscular disorders mimicking juvenile rheumatoid arthritis and hemophilia. *AJR* 1984;143:893 - 897.
4. Little BB, Knoll KA, Klein VR, Heller KB. Hereditary cranium bifidum and symmetric parietal foramina are the same entity. *Am J Med Genet.* 1990 Apr;35(4) 453 - 8.
5. Reddy AT, Hedlund GL, Percy AK. Enlarged parietal foramina - association with cerebral venous and cortical anomalies. *Neurology* 2000 Mar 14;54(5)1175 - 8
6. Shaffer LG, Hecht JT, Ledbetter DH, Greenberg F. Familial interstitial deletion 11(p11.12p12) associated with parietal foramina, brachymicrocephaly, and mental retardation. *Am J Med Genet.* 1993;45:581 - 3.
7. Golabi M, Carey J, Hall BD. Parietal foramina clavicular hypoplasia. An autosomal dominant syndrome. *Am J Dis Child.* 1984;138(6) 596 - 9.
8. Williams PL, Bannister LH, Martin MM et al. *Gray's Anatomy*. 38th ed. Churchill Livingstone, London 1995, pp 425-736.
9. Krishnamurthy A, Nayak SR, Prabhu LV, Mansur DI, Ramanathan L, Madhyastha S, Saralaya V. The morphology of meningo-orbital foramen in south Indian population. *Bratisl Lek Listy.* 2008;109(11):517-9.
10. Georgiou C, Cassell MD. The foramen meningo-orbitale & its relationship to the development of ophthalmic artery. *J. Anat.* 1992(119 - 25)
11. Lanzieri CF, Duchesneau PM, Rosenbloom SA, Smith AS, Rosenbaum AE. The significance of asymmetry of the foramen of Vesalius. Section of Neuroradiology, Cleveland Clinic Foundation, OH 44106. *AJNR Am J Neuroradiol* 1988; 9(6) 1201-4
12. Bergman R.A., Thompson S.A., Afifi A.K., Saadeh F.A., (1988). *Compendium of Human Anatomic Variation; World Literature, Catalog and Atlas.* Urban and Schwarzenberg, Munich and Baltimore.
13. Ginsberg LE, Pruett SW, Chen MY, Elster AD. Skull - base foramina of the middle cranial fossa - reassessment of normal variation with high - resolution CT. *JNR Am J Neuroradiol* 1994;15(2) - 283 - 91
14. Waitzman AA, Posnick JC, Armstrong DC, Pron GE. Craniofacial skeletal measurements based on computed tomography - Part I. Accuracy and reproducibility. *Cleft Palate Craniofac J.* 1992;29(5):489.
15. Kwiatkowski J, Wysocki J, Nitek S. The morphology and morphometry of the so-called "meningo-orbital foramen" in humans. *Folia Morphol(Warsz).* 2003;62(4):323-5.
16. Kodama K, Inoue K, Nagashima M. Studies On the Foramen Vesalius in the Japanese juvenile & adult skulls. *Hokkaido Igako zasshi.* 1997;72(6) 667 - 74
17. Boyd G.I. Emissary foramen of the cranium in arthropods. *J. anat.* 1930; (65)108 - 121.
18. Gupta N, Ray B, Ghosh S. Anatomic characteristics of foramen Vesalius. *Kathmandu University Medical Journal* 2005; 3(2) 155-158
19. Fein JM, Brinker RA. Evolution and significance of giant parietal foramina. Report of five cases in one family. *J Neurosurg.* 1972;37: 487 - 92
20. Garcia-Minaur S, Mavrogiannis LA, Rannan-Eliya SV, Hendry MA, Liston WA, Porteous ME, Wilkie AO. 2003. Parietal foramina with cleidocranial dysplasia is caused by mutation in *MSX2*. *Eur J Hum Genet* 11(11):892-5.