

Hemoperitoneum: Conservative Vs Operative Approach...A Dilemma**Kaushal D. Suthar** , Keshur J Varu***

*3rd Year Resident, ** Associate Proffesor,General Surgery,V.S.Hospital Ahmedabad

Abstract: Background: Haemoperitoneum should be open or not? - it is the dilemma that every surgeon come across whenever a case of hemoperitoneum arrives in emergency..!! Here we have tried to highlight the criteria which will be helpful in this regards. Aims & objective: This study was carried out to evaluate the results and to find out the criteria for decision-making for conservative or operative management in a case of hemoperitoneum.Methods:200 patients admitted during MAY 2014 TO MAY 2016 with hemoperitoneum were enrolled for the study and cases were evaluated for various variables like demographic data, injury classification, associated lesions, treatment, transfusions, morbidity and mortality, and hospital stay. Results: Out of total 200 patients, 76 patients was operated within 8 hours, out of which 22 patients underwent negative laparotomy. The remaining 124 patients were managed conservatively out of which 24 patients underwent laparotomy later because of the failure of the conservative management. Criteria which led to failure of conservative management and criteria which led to negative operative approach is discussed here. Conclusions: Conservative treatment is an adequate treatment in a great number of patients. Failure of conservative treatment did not show a higher incidence of complications or mortality but it should be performed in centers with experienced surgeons. [K Suthar Natl J Integr Res Med, 2018;9(1):57-61]

Key Words: conservative approach, criteria's for approach, hemoperitoneum, mortality, morbidity

Author for correspondence: Kaushal Suthar, B-304, Vandemataram Greens, Beside Bhagyashree Banquets, Sattadhar Cross Roads, Ghatlodiya, Ahmedabad-380061. E-Mail: krazykeshur@gmail.com M: 9033271659

Introduction: Hemoperitoneum is known as presence of blood in peritoneal cavity. Abdominal trauma is essential and the most common culprit for Hemoperitoneum. Most common cause of abdominal trauma with resultant haemoperitoneum is road traffic accidents (75 to 80%) followed by stab injuries. Blunt injury of abdomen is also a result of fall from height, assault with blunt objects, sport injuries, industrial mishaps, bomb blast and fall from riding bicycle. Several pathophysiological processes take place in a case of abdominal injury. Understanding the mechanisms of injury is crucial in the management of a patient with abdominal trauma. Apart from various abdominal organs, injury to other parts of body also plays part in ultimate outcome of patient. Many a time minor injury can be serious especially when involving solid organs of abdomen, so such cases should be thoroughly evaluated and managed accordingly. In spite of the best techniques and advances in diagnostic and supportive care, the morbidity and mortality remains at large. The reason for this could be due to the interval between trauma and hospitalization, delay in diagnosis, inadequate and lack of appropriate surgical treatment, postoperative complications and associated trauma especially to head, thorax and extremities. Other factors which influence outcome in solid organ injuries due to blunt abdominal trauma include extent of resuscitation hemodynamic instability¹, associated injuries to other parts of body and Glasgow coma scale. In view of increasing number of vehicles and road traffic

accidents, this study has been carried out to provide a deep glimpse in the management of hemoperitoneum due to abdominal trauma in context to study incidence rate amongst various age group and genders with clinical presentation, extent of involvement of various intraabdominal organs, various modes of management including investigations either ultrasound or CT scan² to detect intra-abdominal injuries and outcomes of conservative and operative management and to study various complications associated with organ injuries.

Method: 200 cases of hemoperitoneum with purely abdominal injuries were analyzed retrospectively to evaluate the criteria for conservative and surgical approach. Patient's data was collected who were admitted in hospital during MAY 2014 TO MAY 2016 at v.s. hospital, Ahmadabad and analysis of the details done.

Inclusion criteria for conservative approach:¹

1. Hemodynamically stable patient after initial resuscitation with systolic blood pressure of 90 mm of Hg or more.
2. pulse rate < 100/min
3. Radiological injury

Liver – grade 1, 2, 3 injuries with no active leak

Spleen – grade 1, 2, 3 injuries with no active leak

Kidney – grade 1, 2, 3 with no urine extravagation

Exclusion criteria:

1. Hemodynamically unstable patient with systolic blood pressure of less than 90 mmofHg despite of resuscitation and pulse rate> 100/min
2. Patients with penetrating abdominal injuries.
3. X-ray abdomen standing showing free gas under diaphragm.

4. radiological injury

- Liver – grade 4, 5 with active leak
- Spleen – grade 4,5 with active leak
- Kidney – grade 4,5 with urine extravagation.

Table No.1 Showing Grades of Injury in Solid Abdominal Organ

| Injury grade | Liver | Spleen | Kidney |
|--------------|--|--|--|
| Grade 1 | Hematoma-subcapsular,<10% surface area Laceration- capsular tear,<1 cm depth | Hematoma-subcapsular,<10% surface area Laceration- capsular tear,<1 cm depth | Contusion-microscopic or gross hematuria Hematoma-subcapsular hematoma with no parenchymal laceration |
| Grade 2 | Hematoma-subcapsular,10-50% surface area Laceration –capsular,1-3 cm depth | Hematoma-subcapsular,10-50% surface area,<5 cm in diameter Laceration –capsular,1-3 cm depth that does not involve trabecular vessel | Nonexpanding hematoma or cortical laceration less than 1 cm deep with no urine leak |
| Grade 3 | Hematoma-subcapsular,>50 % surface area with active bleed Laceration-capsular ,>3 cm depth | Hematoma-subcapsular,>50% surface area or expanding, ruptured hematoma,>5 cm diameter expanding Laceration->3 cm parenchymal depth or involving trabecular vessel | Parenchymal laceration extending >1 cm into cortex with no urine leak |
| Grade 4 | Ruptured interparenchyma with active bleed Laceration-parenchymal disruption of 25-75% hepatic lobe | Laceration-involving segmental or hillar vessels producing major devascularization,>25% spleen | Parenchymal laceration extending through the corticomedullary junction into the collecting system |
| Grade 5 | Laceration-parenchymal disruption of >75 % hepatic lobe. | Completely shattered spleen | Shattered kidney or avulsion of renal hilum |

As per the prior permission from the ethical committee all the patients were followed properly. After initial resuscitation of the trauma victims¹, Routine blood and urine tests were carried out in all the patients. Documentation of patients which included, identification, history, clinical findings, diagnostic tests, operative findings, operative procedures, complications during the stay in the hospital and during subsequent follow-up period, were all recorded in a proforma. Demographic data collected included the age, sex, occupation and nature and time of accident leading to the injury. Depending on the clinical findings, decision was taken for further investigations such as, diagnostic peritoneal lavage, x-ray abdomen and ultrasound². Each patients

underwent parecentesis, sonography and ct scan. The decision for operative or nonoperative management depended on the outcome of the clinical examination

and results of diagnostic tests. Patients selected for nonoperative or conservative management were placed on strict bed rest, were subjected to serial clinical examination which included hourly pulse rate, blood pressure, respiratory rate and repeated examination of abdomen and other system³.

Results: Out of 200 patients enrolled in study, 70% were male while 30% female patients were victims of blunt abdominal trauma. Road traffic accidents⁴ are major culprit for solid organ injuries in these patients (54%) followed by fall from height (24%) and assault on victim (14%). 64% patients were brought for

treatment within 5 hours of injury while 36% patients were brought for treatment within 24 hours.. More than 95% of patient presented with one or more abdominal symptoms, like abdominal pain, vomiting and/or abdominal distension. Other presentations include haematuria, bleeding per rectum, hematemesis and altered consciousness. Out of 200 patients, 76 patients were operated on the same day within 8 hours⁵, out of which 22 patients had negative findings in laparotomy. 124 patients who were managed conservatively, 24 patients underwent laparotomy because of the further deterioration and on laparotomy out of operated 24 patients⁶, 8 patients had negative findings. Rest 100 patients managed conservatively and went home.

Flow Chart No.1 Showing the Results of Management

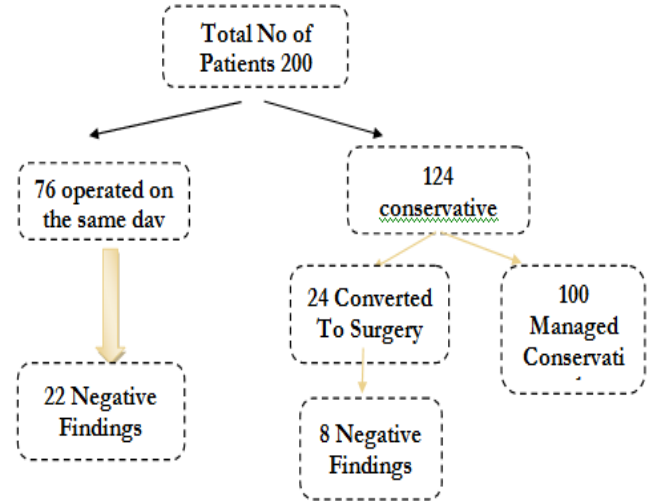


Table No 2: Comparison of hemodynamically stability of patients in different injuries.

| Hemodynamically stable | Liver | Kidney | Spleen | Mesentery | Combined |
|------------------------|-------|--------|--------|-----------|----------|
| Yes | 62 | 26 | 25 | 11 | 0 |
| No | 26 | 14 | 20 | 2 | 14 |

Table No 3: Grades of Injury In Organs In Study.

| Organ | Grade 1 | Grade 2 | Grade 3 | Grade 4 | Grade 5 |
|-----------|---------|---------|---------|---------|---------|
| Liver | 12 | 20 | 20 | 14 | 22 |
| Spleen | 10 | 7 | 4 | 8 | 16 |
| Kidney | 9 | 5 | 10 | 10 | 6 |
| Pancreas | 1 | | | | |
| Mesentery | 12 | | | | |
| Combined | 14 | | | | |

Discussion: This study consist of 200 patients who have developed solid organ injury due to various causes and brought to VS hospital, Ahmedabad . We analysed data for conservative approach and operative approach and found that 124 patients who were managed conservatively, 24 patients underwent laparotomy and 8 have negative findings. so we conclude that patients with grade 2, 3 injuries who was managed conservatively but underwent laparotomy because of the unstable vitals and not responded to blood products didn't have any active bleed from any organs. But all of them had hematoma and abdominal collection with abscess formation. At the time of admission, patients who were unstable despite blood products and enough resuscitation, presented with frank hematuria were shifted to

operation theatre. 76 patients were operated on the same day out of which 22 patients had negative outcomes as on exploration no active bleeding was found but only hematoma or multi organ injuries were found. Though 54 patients who got operated had

positive findings like expanding retroperitoneal hematoma, mesenteric bleed and hematoma, vascular pedicle injuries. So it is extremely hard to decide about the conservative approach or go for the exploration. It is always up to the treating surgeon but conservative approach is more effective in terms of less morbidity, less hospital stay , recovery. Operative approach too have its own benefits, can save the lives. When patient is getting managed conservatively, close observation time to time is much needed. If patient is not responding to blood products, hematocrit don't rise up, hypovolemia resist even after enough resuscitation and ct scan showing no active leak or no pedicle injury than it's the real dilemma , should go for exploration or not ?? , According to what we studied in this study is that if multiple organ is injured, if grading of the injury is below 3 we can further give time to patient to respond because on exploration also we won't get anything that will save the patient's life but further conservative approach and observation with some time can save the patient from exploration.

Table No 4: Criterias for Conservative Vs Operative Management and Findings

| 124 : Conservative Patients | 24 : Converted To Laparotomy | 8 : Negative Laparotomy | 16 : Positive Findings |
|--|--|-------------------------------------|-------------------------------------|
| Vitally stable | Blood pressure fall altered consciousness, SBP< 80mmhg, tachycardia >110/m | No active bleeding | Active bleeding from traumatic site |
| No active leak on ct scan | Active leak on ct scan | Collected blood | Combined organ injuries |
| Distention not increasing | Abdominal distention> 6 cm in 24 hour | Pelvic and retroperitoneal Hematoma | Intestinal disruption |
| Hematocrit static, blood needed < 250 ml | Hematocrit decrease > 2% in 24 hour despite blood products | | Mesenteric oozing |
| Grade 1,2,3 injuries | Grade 4,5 injuries | Grade 2 injuries | Grade 3 injuries |

Table No 5: Comparison Of Operative Management.

| 76 : Emergency Laparotomy | 54 : Positive Findings | 22 : Negative Findings |
|---|------------------------|--|
| Vitally unstable | Expanding hematoma | Pelvic haematoma or retroperitoneal hematoma not expanding |
| Abdominal distention | Mesenteric bleed | Combined organ injuries, no active bleed from any organ |
| Hematuria, active penetrating injury , | Active organ bleed | Hematoma at local vessel |
| Not responding to blood transfusion and resuscitation | Grade 4,5 injuries | Grade 1,2 injuries. |
| Active leak on ct scan | Intestinal disruption | |

76 patients who were operated on the same day of admission, 22 patients had negative findings on laparotomy.

Conclusion: Blunt trauma of abdomen is a major cause of morbidity and mortality in young and economically productive age-group⁷. Road traffic accident is the major causative agent. Availability of emergency resuscitation and trauma care services, especially near highways helps in lowering the mortality. With investigations like ultrasonography and computed tomography scan, there is a paradigm shift in the management of non-penetrating trauma abdomen from operative to non-operative mode. Conservative line of management is safe and effective in a hemodynamically stable patient without any signs of peritonitis. If after conservative approach, patients suddenly start to worsen in terms of vitals⁸, rather than going for operative approach we should consider aspiration of abdominal abscess, polytrauma patients should be examined again to miss out fracture or injury. Re imaging can give a good idea about if active bleeding restarted or not. These considerations can save us from the negative laparotomies.

So we conclude that, vitally unstable patient with hemoperitoneum can be managed conservatively if,⁹

- Grade 3 or less injury
- Intra abdominal abscess formation due to collected blood can make patient unstable

- No active bleed from one organ but collective organ injuries

References:

1. Ciraulo DL, Luk S, Palter M, Cowell V, Welch J, Cortes V, Orlando R, et al. Selective hepatic arterial embolization of grade IV and V blunt hepatic injuries: an extension of resuscitation in the nonoperative management of traumatic hepatic injuries. *J Trauma* 1998;45(2):353- 358; discussion 358-359
2. Richards JR, Schleper NH, Woo BD, Bohnen PA, McGahan JP. Sonographic assessment of blunt abdominal trauma: A 4-year prospective study. *J Clin Ultrasound* 2002;30:59–67.
3. Davis JJ, Cohn I, Nance FC. Diagnosis and management of blunt abdominal trauma. *Ann Surg* 1976; 183(6):672-8.
4. Kenneth D, Boffard, Bowley. Accident and emergency surgery. In: Russel RCG, Williams NS, Bulstrode CJK, edi, Bailey and Love's short practice of surgery. 24th ed. London: Arnold publications. 2004. p. 270-86.
5. Farrath S, Parreira JG, Perlingeiro JA, Solda SC, Assef JC. Predictors of abdominal injuries in blunt trauma. *Rev Col Bras Cir* 2012;39(4):295-301

6. Bodhit AN, Bhagra A, Stead LG. Abdominal Trauma: Never Underestimate It. Case Rep Emerg Med 2011;850625.
7. Gourgiotis S, Vougas V, Germanos S, Dimopoulos N, Bolanis I, Drakopoulos S, Alfaras P, et al. Operative and nonoperative management of blunt hepatic trauma in adults: a single-center report. J HepatobiliaryPancreatSurg 2007;14(4):387-391.
8. Kozar RA, Moore JB, Niles SE, Holcomb JB, Moore EE, Cothren CC, Hartwell E, et al. Complications of nonoperative management of high-grade blunt hepatic injuries. J Trauma 2005;59(5):1066-1071.
9. Christmas AB, Wilson AK, Manning B, Franklin GA, Miller FB, Richardson JD, Rodriguez JL. Selective management of blunt hepatic injuries including nonoperative management is a safe and effective strategy. Surgery 2005;138(4):606-610

| |
|----------------------------|
| Conflict of interest: None |
|----------------------------|

| |
|---------------|
| Funding: None |
|---------------|

| |
|---|
| Cite this Article as: K Suthar, K Varu. Hemoperitoneum: Conservative Vs Operative Approach: A Dilemma. Natl J Integr Res Med 2018; 9(1):57-61 |
|---|