

## Chromoblastomycosis

Dr. Harshada Shah\*, Dr. K.Verma\*\*, Dr. P.L.Dhand\*\*\*, Dr. Rajesh Soni\*\*\*\*, Ms. Pragya Shakya \*\*\*\*

\*Prof. & Head, Dept. of Microbiology, \*\*Prof. & Head, Dept. of Skin & Venereal Disease, \*\*\*Prof. & Head, Dept. of Pathology, \*\*\*\*Assistant Professor, \*\*\*\*P.G. Student, Dept. of Microbiology, RDGMC, Ujjain

**Abstract:** Chromoblastomycosis is a chronic fungal infection primarily of skin and subcutaneous tissue caused by a variety of dematiaceous fungal species belonging to different genera. We report a case which remains undiagnosed for 15 years although it presented with the most common manifestation. It was diagnosed and treated with excellent clinico-microbiological and histo-pathological correlation.

**Key words:** Chromoblastomycosis, *Cladosporium carionii*, Copper penny bodies.

**Corresponding Author:** Dr. Harshada Shah, Professor & Head, Dept of Microbiology, R.D.Gardi Medical College, Surasa, Agar Road, Ujjain (MP) 456006, E –mail: sharshada1955@yahoo.com

**INTRODUCTION:** Chromoblastomycosis is a chronic, relatively uncommon, localized mycotic infection of the skin and subcutaneous tissue. Normally, it follows a traumatic implantation of dematiaceous fungi. The lesions range from verrucoid, ulcerated, crustate or cauliflower like growth to raised or flat plaques. Satellite lesions develop following auto-inoculation and by lymphatic spread to adjacent areas. The disease has been described worldwide, but the incidence is greater in subtropical regions. Large numbers of cases have been reported from Madagascar and Brazil. Farming is the most common occupation associated with this lesion<sup>1</sup>. In India, most of the cases have been reported in belts from North to South sparing the Eastern and Western regions<sup>2</sup>. We present a case of Chromoblastomycosis from Central India.

**CASE REPORT:** A 50 year old male agriculturist from Ujjain district in Madhya Pradesh visited the Skin OPD of C.R Gardi hospital in Jan, 2008. He presented with a 15 years long history and a cauliflower like lesion associated with itching and depigmentation of right lower limb. History revealed that it began with a small papular lesion on the external surface of right foot with itching. He went pole to post to seek medical attention until the lesion increased in size over a period of last 5 years. He also tried several home remedies. He was diagnosed as a case of tuberculosis at other center and received anti-tubercular treatment without

getting any clinical response. The lesion continued to progress and reached up to his knee (fig.1).

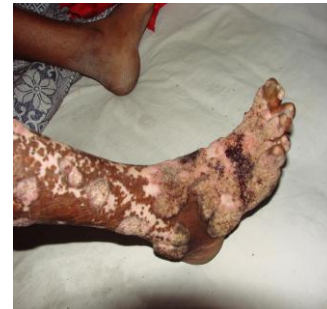

Fig 1

Initial KOH mount showed a fair number of round, non-septate structures resembling fungal spores. The skin biopsy done at our center revealed a pseudoepitheliomatous hyperplasia with micro abscesses and granulomatous infiltrate (fig.2).

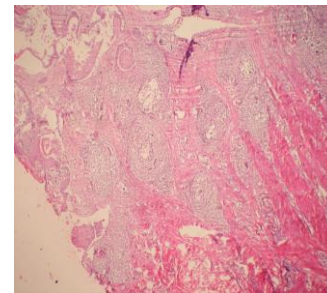


Fig 2

Classical copper penny bodies with brown pigmentation (sclerotic/ Meddler bodies) were present amidst the inflammatory infiltrate (fig.3).

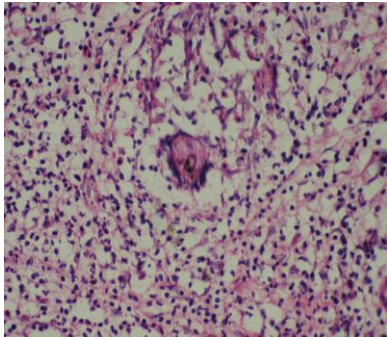


Fig 3

Culture on SDA with chlormphenicol and cycloheximide from skin scrapings revealed fungal colonies, which were identified as *Cladosporium carroionii* based on colony morphology and microscopy (fig.4)<sup>3</sup>.

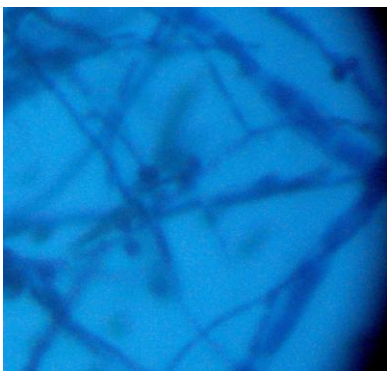


Fig - 04 Crooked hyphae

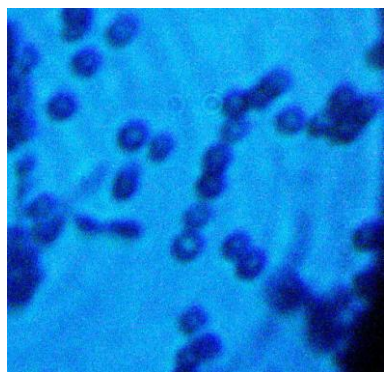


Fig - 04 spherical / oval conidia in chains

Hematological & biochemical parameters were within normal limits. X-ray chest was normal. The patient was treated with Terbinafine and Itraconazole resulting in improved mobility and substantial drying of lesions with warty changes in first 3 months of the treatment. Unfortunately in spite of our efforts the patient could not be followed up beyond 6 months.

**DISCUSSION:** Chromoblastomycosis usually occurs on hands, feet and upper legs. In our patient the lesion extended from foot up to the knee joint. It developed gradually starting as papular lesion to a cauliflower like growth. This is a common development reported in several other studies. A case of primary involvement of face has been reported by<sup>4</sup>. Usually the lesions remain confined to skin and subcutaneous tissue. However, hematogenous and lymphatic dissemination of the mycotic infection with fatal outcome has been documented in rare cases.

The disease occurs commonly between 20-40 years of age with male preponderance. In a review of 34 patients by<sup>5</sup>, the patients aged from 12 to 80 years with a male to female ratio of 5.8:1. The above mentioned was a male who got infected at the age of 35 years. Indian patients with subcutaneous pheohyphomycosis are affected at an earlier age<sup>2</sup>. Culture was positive in 72% of cases and sclerotic bodies were observed in 84% cases. In our case, the histopathology revealed sclerotic bodies and the culture was also positive. Although, a relatively higher prevalence (15%) *Fonsecaea compacta* has been observed<sup>6</sup>, we identified *Cladosporium carroini*. A case of chromoblastomycosis caused by *Fonsecaea pedrososi* presenting as a small plaque on the left upper arm: has been reported in review of cases of dematiaceous fungal infections in Japan<sup>7</sup>.

Extracutaneous involvement has been reported in 24 % of cases<sup>8</sup>. Surprisingly with 15 years long history there was no extra cutaneous involvement in this case.

The characteristic histological and culture findings described for the disease were present in this patient. The clinical and histological features of

chromoblastomycosis are often misdiagnosed as squamous cell carcinoma or cutaneous tuberculosis, if a high level of suspicion and early diagnosis is not made. Similarly our patient was treated for cutaneous tuberculosis for two years.

Numerous studies reported from India describe the distribution of the disease in the country in a belt from north to south, more so in sub-Himalayan belt<sup>6, 9,10</sup>. There are sporadic reports from eastern and western regions. Since, there are sparse reports from our region, we report this case.

Intra-lesional or systemic administration of amphotericin-B, flucytosine, calciferol with or without potassium iodide and INH has produced better results than ketoconazole, thiabendazole and topical heat and X-ray therapy. Variable results with ketoconazole alone have been reported. In the above referred case, terbinafine and itraconazole halted the progression of the fungus.

In our opinion, a high clinical suspicion by the dermatologist and collaborative efforts done by the clinician with the pathology and microbiology laboratory has resulted into an excellent diagnosis which was unfortunately not revealed during last 15 years in spite of approaching several clinicians, from various places by the patient. Secondly, lack of microbiology facilities at most of the places may lead to under or wrong diagnosis leading to delay in proper treatment in these patients.

#### REFERENCES:

1. Seema V. Pradhan et al; Indian Journal of Dermatology, Venerology and Leprology 2007, Vol 73, Page no 176
2. Sharma NL, Mahajan V, Sharma RC, Sharma A., 2002., Subcutaneous pheohypomycosis in India- a case report and review. Int. J. Dermatol. Vol 41(1), p-16-20.
3. Jagdish Chander – Textbook of medical mycology – 3rd edition – 2009.P -181
4. Rakesh Bharti, S K Malhotra, Singh Manjit Bal, – Indian journal of dermatology, venereology and leprology, 1995, vol – 61(1), p – 54,55
5. Sharma NL, Sharma RC, Grover PS, Gupta ML, Sharma AK, Mahajan VK(1999)., Chromoblastomycosis in India. Int. J .Dermatol 38(11)., 846- 51.
6. Rajendran C, Ramesh V, Misra RS, Kandhari S, U. preti HB, Datta K K(1997) . Chromoblastomycosis in India. Int. J. Dermatol 36(1), p-29-33.
7. Kikuchi Y, Kondo M, Yaguchi H, Hiruma M, Ikeda S. 2007. A case of chromoblastomycosis caused by *Fonsecaea pedrososi* presenting as a small plaque on the left upper arm: a review of reported cases of dematiaceous fungal infection in Japan. Nippon Ishinkin Gakkai Zasshi. 48(2) 85-9.
8. 8.. Chromoblastomycosis in India – Nandlal Sharma, Ramesh Chander Sharma, Prem Singh Grover, ML Gupta, AK Sharma, VK Mahajan – International journal of dermatology – 2001, v – 38(Nov), p – 846 -851.
9. Vyas MC, Joshi YR, Bhargava N, Joshi KR, Tanwar RK. 2000. Cerebral chromoblastomycosis – a rare case report of cerebral abscess and brief review of literature – a case report.Indian J. Pathol. Microbiol.43 (1), p 81- 10.
10. Garg N, Devi IB, Vajramani GV, Nagarathna S, Sampath S, Chandramouli BA, Chandramukhi A, Shankar SK.Central nervous system cladosporiosis: an account of ten culture-proven cases. Neurol India, 55(3): 282-8.