

## Fine Needle Aspiration Cytology of Breast: Current Perspective on The Role In Diagnosis

Biren J. Parikh\*, Bhumi M. Shah\*\*, Swati B. Parikh\*\*\*, Jayshree M. Shah\*\*\*\*

\* Assistant Professor, \*\*3rd Year Resident Doctor, \*\*\*\* Professor & Head, Pathology Department, AMC MET Medical College, Ahmadabad, India

\*\*\* Associate Professor, Sheth V.S. General Hospital & Smt. NHL Municipal Medical College, Ahmadabad, India

**Abstract:** Background: Breast cancer is the common malignant lesion in women. Fine-needle aspiration cytology (FNAC) of the breast is a minimally invasive yet maximally diagnostic method. Aim: The aim was to study the cytomorphological features of breast lesions and to evaluate the diagnostic accuracy of fine needle aspiration cytology in breast lesions. Methods: This study was carried out on 175 patients who presented with palpable lumps in breast in the Department of Pathology; AMC MET Medical College, Ahmadabad, India, from January 2015 to August 2016. Cytological diagnosis was given and histopathological correlation was made, whenever available. Results: Out of 175 cases of breast lesions, 128 (73.14%) were benign & 41 (23.43%) were malignant. Fibro adenoma (40%) was the most common benign lesion and ductal carcinoma (23.43%) was the most common malignant lesion. Sensitivity, specificity, positive predictive value & negative predictive value were found to be 97.5%, 100%, 100% & 98.48% respectively with diagnostic accuracy to be 99.04%. Conclusion: FNAC is a simple, cost effective procedure that can be carried out at outpatient department. FNAC should be practised as there is high diagnostic accuracy of the method. [Biren P NJIRM 2017; 8(4):73-77]

**Key Words:** Breast lesions, Ductal carcinoma, Fibroadenoma, Fine needle aspiration cytology, Histopathology

**Author for correspondence:** Bhumi M. Shah, E/403, Haridham Society, Near Bapa Sitaram Chawk, New Naroda, Ahmedabad-382345, Gujarat, India. E-Mail: dr.bhumishah403@gmail.com M: 9409419659

**Introduction:** Breast cancer is the leading cause of morbidity and mortality.<sup>1,2</sup> Fine needle aspiration cytology (FNAC) is widely accepted as a reliable technique in the initial evaluation of breast lumps. The procedure is simple, safe, cost effective, minimally invasive, rapid and can be carried out at outpatient department.<sup>3,4</sup> It is highly sensitive, specific and diagnostically accurate.

A breast mass is generally palpable when it exceeds 2cm in size. The likelihood of a palpable mass of being malignant increases with age. Only 10% of breast masses under the age of 40 are malignant compared to 60% of masses over the age of 50 years.<sup>5</sup>

Investigation of a palpable breast lump involves "Triple test" which analyses clinical and radiological findings in conjunction with pathologic features (FNAC) for the diagnosis as well as to reduce the risk of missed diagnosis to < 1%.<sup>6</sup> The primary goal of aspiration cytology is to separate malignant lesions that require more radical therapy from benign ones that may be conservatively managed.

### Aims and Objectives:

To study the cytomorphological features of breast lesions. To correlate FNAC findings with clinical and histopathological findings. To find the diagnostic accuracy of fine needle aspiration cytology in breast lesions.

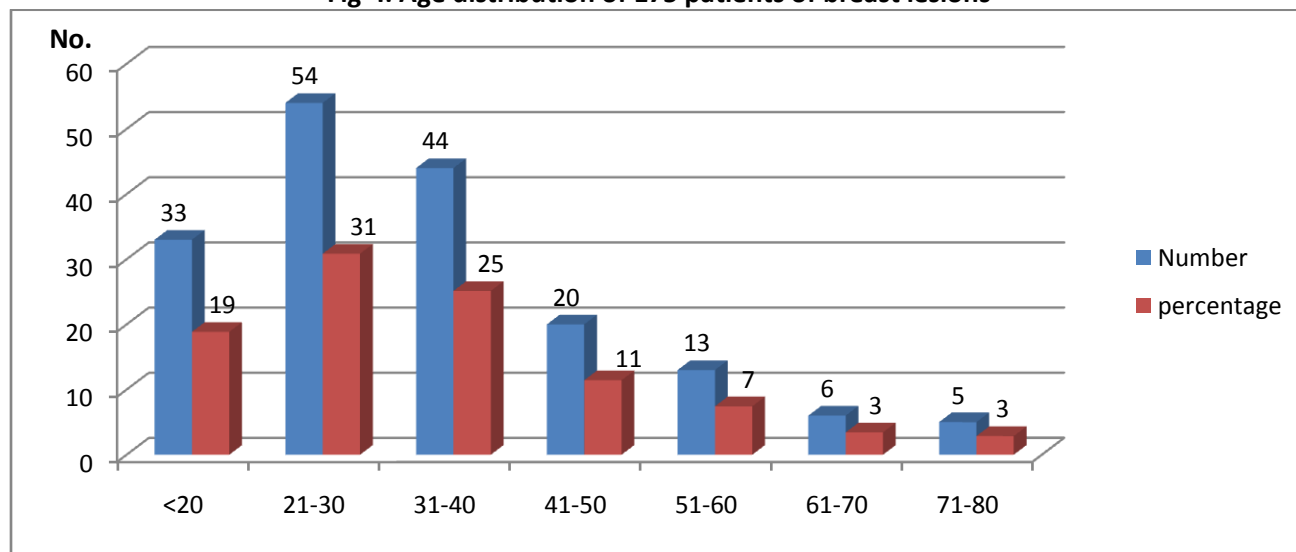
**Method:** A total of 175 cases of palpable breast lumps referred to the cytology section of pathology department, AMC MET Medical College Ahmadabad, India; during the time period from January 2015 to August 2016 were included in the study. Prior to aspiration, detailed clinical history was taken & physical examination of breast lump was carried out along with palpable axillary nodes. The procedure was carried out with a 21 or 23 gauge needle attached to a 10 cc airtight disposable syringe. The sample was obtained with aspiration and non-aspiration techniques with minimum passes to minimize hemorrhage. Samples were smeared onto glass slides. Wet-fixed smears were stained with Haematoxylin and Eosin (H&E) stain. In cystic lesions, the aspirated fluid was centrifuged and smears were made from sediment. In cystic lesions, after aspirating the fluid; re-aspiration from remaining solid nodule was attempted. FNAC results were categorized by the criteria recommended by National cancer institute consensus conference on breast FNAC<sup>7</sup> & specific diagnosis was given whenever possible.

The diagnostic accuracy of FNAC was calculated by correlating with histopathological results whenever available.

**Result:** The age range of 175 patients included in this study was from 10–80 years. Breast lesions were more common in the age group of 21-30 years (Fig-I). In the

3rd decade benign lesions and in the 4th decade malignant lesions were common.

**Fig- I: Age distribution of 175 patients of breast lesions**



Among all cases, 3 (1.71%) were male and 172 (98.29%) were female patients.

In 88 cases (50.28%), the lesions were located in the right breast and in 81 (46.29%) cases lesions were located in the left breast. In 6 (3.43%) cases, bilateral lesions were observed.

**Table-I: Presenting Symptoms & signs in 175 cases**

Signs and symptoms	No of cases
Lump	175(100%)
Pain	52(29.71%)
Fever	24(13.71%)
Nipple discharge	18(10.29%)
Nipple retraction	28(16%)
Axillary lymphadenopathy	20(11.43%)

Table-II depicts the categorization & cytological diagnosis of 175 cases. Out Of 175 patients of breast lesions, 05 (2.86%) cases were categorized as Inadequate/insufficient for evaluation. A total 128 (73.14%) cases were fallen in benign category. Amongst all benign breast lesions, fibroadenoma was the most common followed by fibrocystic change, inflammatory breast lesion, benign proliferative breast lesion and phyllodes tumour. One (0.57%) case was labelled as suspicious for malignancy and 41 (23.43%) cases were categorised as malignant lesions; all of which were ductal carcinoma.

**Table-II: Cytomorphological categories & Diagnosis of 175 cases of Breast Lesions**

Category(n=175)	Cytological Diagnosis	No. of cases (n=175)
Inadequate/Insufficient (n=05)(2.86%)	-	05 (2.86%)
Benign (n=128)(73.14%)	Fibroadenoma	70(40%)
	Fibrocystic Disease of Breast	22(12.57%)
	Mastitis	21(12%)
	Benign Proliferative Breast Lesion	14(8%)
	Benign Phyllodes Tumour	01(0.57%)
Atypical/Indeterminate(n= 0) (0%)	-	00(00%)
Suspicious of malignancy ( n= 1)(0.57%)	Epithelial hyperplasia with atypia	01(0.57%)
Malignant (n=41)(23.43%)	Ductal carcinoma of Breast	41(23.43%)

Out of total 175 cases studied by cytology, histopathological correlation was obtained in 105 cases. (Table -III)

**Table-III: Cyto-Histopathological Correlation (n=105)**

Cytological Diagnosis	Total	Histopathological Diagnosis	
		Malignant	Benign
Malignant	39	39 True Positive	00 False Positive
Benign	66	01 False Negative	65 True Negative
Total	105	40	65

In our study sensitivity, specificity, positive predictive value & negative predictive value were found to be 97.5%, 100%, 100% & 98.48% respectively with diagnostic accuracy to be 99.04%.

**Discussion:** FNAC of breast lump is an accepted and established method to determine the nature of breast lump with high degree of accuracy.<sup>8,9</sup> The application of Fine needle aspiration (FNA) for the diagnosis of palpable breast masses was first introduced by Martin and Ellis<sup>10</sup> in 1930, and since then, it has been established as an important tool in the evaluation of breast lesions. Most of the patients with breast lump are in a state of anxiety. To reduce unnecessary surgical procedures as well as at the same time to minimize delay in the diagnosis & to institute prompt treatment, FNAC plays an important role.

In the present study, 5 cases (2.86%) were categorised as unsatisfactory for evaluation because of very scanty cellularity or only haemorrhagic aspirate. Benign lesions constituted of 128 cases (73.14%); of which predominant lesion was fibro adenoma. Amongst 41 cases (23.43%) of malignant lesions, all were typified as ductal carcinomas. Other studies<sup>11,12,13,14</sup> reveal similar distribution of benign and malignant lesions.

One case (0.57%) was found to be suspicious for malignancy by FNAC because of smears having atypical cells suggestive but not diagnostic of malignancy. This case turned out to be malignant by histopathological examination. Other studies also noted an increase in rate of malignancy on histopathology in lesions which were previously diagnosed under the category of “suspicious lesions for malignancy” (Table-IV).

In the present study, one case, which was diagnosed as benign breast lesion by FNAC was diagnosed as a malignant breast lesion by histopathological examination (False Negative). This was a male patient with unilateral breast swelling. FNA revealed aspiration of haemorrhagic fluid. On smear study, low cell yield was noted with no significant cellular atypia. So, FNA diagnosis of benign breast lesion probably gynecomastia with cystic change was rendered. However, subsequent histopathology revealed the diagnosis of intracystic papillary carcinoma. Pitfalls of FNAC in papillary breast lesions have been reported in literature reviewed.<sup>15,16,17</sup>

**Table- IV: Cyto-histopathological correlation with other studies**

Studies	No. Of Benign Lesion	Histological diagnosis		No of Malignant lesions	Histological diagnosis		No of suspicious cases	Histological diagnosis		Sensitivity	Specificity
		Benign	Malignant		Benign	Malignant		Benign	Malignant		
Tiwari M <sup>11</sup>	16	15 (93.75%)	01 (6.25%)	05	00 (00%)	05 (100%)	-	-	-	83.3%	100%
O Neil S et al <sup>18</sup>	166	153 (92.17%)	13 (7.83%)	401	03 (0.75%)	398 (99.25%)	125	41 (32.80%)	84 (67.20%)	97%	78%
Zhang Qin et al <sup>12</sup>	215	213 (99.07%)	02 (0.93%)	73	00 (00%)	73 (100%)	28	02 (7.14%)	26 (92.86%)	97.1%	97.3%
A.Z.Mohammed et al <sup>13</sup>	61	58 (95.08%)	03 (4.92%)	27	00 (00%)	27 (100%)	02	00 (00%)	02 (100%)	90.6%	100%
Sahil I et al <sup>14</sup>	46	45 (97.83%)	01 (2.17%)	43	00 (00%)	43 (100%)	02	00 (00%)	02 (100%)	97.82%	100%
Present study	66	65(98.48%)	01(1.52%)	38	00 (00%)	38 (100%)	01	00 (00%)	01 (100%)	97.5%	100%

In our study, a 100% cytohistopathological correlation was observed for malignant lesions. Zhang Qin et al<sup>12</sup>, A.Z.Mohammed et al<sup>13</sup>, Tiwari M<sup>11</sup>, Sahil et al<sup>14</sup> also observed the same results in their studies. In the study of O Neil et al<sup>18</sup> large numbers of suspicious cases of malignancy were confirmed as benign lesions in histopathology; which might be due to inter observer variability to label the cases in suspicious category.

Diagnostic accuracy in our study was reported to be 99.04%. Accuracy rates of 84-99.5% have been reported in various series<sup>19</sup>.

**Conclusion:** Fine needle aspiration cytology is a simple, cost-effective, highly accurate, quick and relatively less painful procedure which can be used for the diagnosis of breast lumps. It provides high diagnostic accuracy. Some difficulties and limitations need to be mentioned, viz. both false-negative and false-positive results can occur. However, these can be avoided or minimized by experience and expertise of cytopathologist. So, it is concluded that FNAC should be used as a routine diagnostic procedure to maximize the availability of effective health care to patients with breast lesions.

**References:**

1. Leopold G.koss, Editor. Koss Diagnostic cytology. 5th ed. Lippincott Williams& Wilkins: Philadelphia; 2006. pp1081-84.
2. Muddegowda PH, Lingegowda JB, Kurpad RK, Konapur PG, Shivarudrappa AS, Subramaniam PM. The value of systematic pattern analysis in FNAC of breast lesions: 225 cases with cytohistological correlation. *J cytol.* 2011;28:13-9.
3. Rimm DL, Stastny JF, Rimm EB, Ayer S, Frable WJ: Comparison of the costs of fine needle aspiration and open surgical biopsy as methods for obtaining a pathologic diagnosis. *Cancer*; 1997; 81: 51-56.
4. Silverman JF, Lannin DR, O'Brien K, Norris HT: The triage role of fine needle aspiration biopsy of palpable breast masses. Diagnostic accuracy and cost effectiveness. *ActaCytol*; 1987; 31: 731-736.
5. Susan C. Lister. *The Breast*. In, Kumar, Abbas, Fausto, Aster(Ed). Robbins and Cotran Pathologic basis of disease. 8th edition. Philadelphia, Pennsylvania, Saunders, 2010; 1066-8.
6. Joan Cangiarella and Aylin Simser. *Breast*. In Svante R Orell (Editor), Gregory F. Sterrett (Ed).

- Orell and Sterrett's Fine Needle Aspiration Cytology. 5th edition. Philadelphia, Churchill Livingstone, 2012; 156-7.
7. National Breast Cancer Centre. 2004. Breast fine needle aspiration cytology and core biopsy: a guide for practice, National Breast Cancer Centre, Camperdown, NSW
8. Kaufman Z, Shpitz B, Shapiro M, et al. Triple approach in the diagnosis of dominant breast mass: combined physical examination, mammography, and fine-needle aspiration. *J SurgOncol*, 1994; 56: 254-7.
9. Purasiri P, Abdalla M, Heys SD, Ah-See AK, McKean ME, Gilbert FJ, Needham G, Deans HE and Eremin O. A novel diagnostic index for use in the breast clinic. *J R Coll Surg Edinb*, 1996;41: 30-4
10. Martin HE, Elis EB. Biopsy by needle puncture and aspiration. *Ann Surg*, 1930;92:169-81
11. Tiwari M. Role of FNAC in diagnosis of breast lumps. *Kathmandu University Medical Journal*. 2007; 5: 215-17
12. Zhang Qin, Nie Shigui, Chen Yuhua, Zhou Limei. Fine Needle Aspiration Cytology of Breast Lesions: Analysis of 323 Cases. *The Chinese-German Journal of Clinical Oncology* 2004; 3(3): 172-74.
13. Mohammad AZ, Edino ST, Ochicha O, Alhassan SU. Value of fine needle aspiration biopsy in preoperative diagnosis of palpable breast lumps in resource-poor countries: a Nigerian experience. *Annals of African Medicine*. 2005; 4(1): 19-22.
14. Sahill. Panjavani et al., Utility of Fine Needle Aspiration cytology in evaluation of breast lesions :journal of clinical and diagnostic fresearch. 2013dec, Vol7(12):2777-2779.
15. Asmund Berner. Fine-needle Aspiration Cytology of breast. *Ultrastruct Patho*, 35(4), 162-167, 2011
16. P. H. Levine, J. Waisman, and G. C. H. Yang, "Aspiration cytology of cystic carcinoma of the breast," *Diagnostic Cytopathology*, vol. 28, no. 1, pp. 39-44, 2003.
17. DPrathiba, Shaline Rao, Kasthuri Kshitija, and Leena Dennis Joseph Papillary lesions of breast – An introspect of cytomorphological features; *Journal of Cytology*, Vol. 27, No. 1, January-March, 2010, pp. 12-15
18. O'Neil S, Castelli M, Gattuso P, Kluskens L, Madsen K, Aranha G. Fine-needle aspiration of 697 palpable breast lesions with histopathologic correlation. *Surgery*. 1997; 122(4): 824-28.

19. Wilkison EJ, Schuetteke CM, Ferrier CM, Franzini DA. Fine needle aspiration of breast masses. An analysis of 276 aspirates. *ActaCytol.* 1989; 33: 613-19.

Conflict of interest: None
Funding: None
Cite this Article as: Biren P, Bhumi S, Swati P, Jayshree S. Fine Needle Aspiration Cytology of Breast: Current Perspective on The Role In Diagnosis. <i>Natl J Integr Res Med</i> 2017; 8(4):73-77