

Malignant Melanoma: A Case Report With Literature Review

Prakash Gadodia*, **Ritesh Wadhvani****, **Akshay Dhobley****, **Namrata Patil****,
Vinod Kumar Patil***, **Vinita Murgod*****

*Professor & Head, **Reader, ***Lecturer, Department of Oral Pathology, SDDC, Parbhani, Maharashtra, India

Abstracts: Primary malignant melanoma of the oral cavity is a rare and aggressive neoplasm. They tend to metastasize or locally invade tissue more readily than other malignant tumours in the oral region. Prognosis of oral melanoma is comparatively poor and so an early diagnosis and follow-up is critical. Here we report a case of oral melanoma, pigmented macular type, in maxillary anterior gingival region in a 60 year old female patient. [Gadodia P NJIRM 2016; 7(1):120-124]

Key Words: Melanoma, neoplasm.

Author for correspondence: Dr. Prakash Gadodia, Professor & Head, Department of Oral Pathology, SDDC, Parbhani, Maharashtra, India. [Email: gadodia.prakash@gmail.com](mailto:gadodia.prakash@gmail.com)

Introduction: Oral Malignant melanoma is a potentially aggressive tumour of melanocytic origin and was first described by Weber in 1859.^{1,2} It accounts for 0.2% to 8% of all the melanomas and 0.5% of all the malignant neoplasms of the oral cavity.³ It is more commonly seen in Japanese population than in other groups. In Japan, oral melanomas account for 11-12.4% of all melanomas. This percentage is higher than the 0.2-8% reported in the United States and Europe.⁴ In the East, mucosal malignant melanoma seems to be more common than the West.⁵ The most common locations in oral cavity are the palate and maxillary gingiva. Metastatic melanoma most frequently affects the mandible, tongue, and buccal mucosa. Oral melanomas seem to be more aggressive and they spread and metastasize more rapidly than other oral cancers or cutaneous melanomas.⁴ Most cases of oral melanoma occur between the fourth and the seventh decade of life, with an average of 55-57 years and having a predilection for the male gender with a male to female ratio of 2.8:1.⁶ The clinical presentation of this condition may vary widely which is divided into following five types: Pigmented nodular type, pigmented macular type, pigmented mixed type, non-pigmented nodular type and non-pigmented mixed type.⁷ The clinical coloration has a wide range, which can appear as black, grey, purple and reddish. The tumours are asymmetric, irregular in outline and occasionally multiple. The symptoms of the oral mucosal melanoma include: bleeding, pain (it often appears late) and presence of melanotic pigmentation.⁴ Non pigmented forms of malignant melanoma often cannot be distinguished clinically from other benign or malignant oral tumours which can only be diagnosed through biopsy and immunohistochemistry.⁷ Its aetiology is unknown, although sometimes it is placed on pre-existing long-term melanosis involving 33 to 55% of the mucosal melanomas of the head and neck, other possible etiological factors for this neoplasia are: mechanical

trauma such as denture irritation, use of tobacco and prolonged exposure to formaldehyde and alcohol.⁸ Many genes are implicated in the development of melanoma, including CDKN2A (p16), CDK4 (chromosome 12q15), RB1, CDKN2A (p19) and PTEN/MMAC1.⁹ Delayed detection may be the reason for the poor prognosis of oral malignant melanomas with the 5-year survival rate being between 15% to 38%. Early recognition and immediate treatment may greatly improve the prognosis.¹⁰

Case Report: A 60 yrs old female patient reported to the department with chief complaint of mild pain and swelling in upper left front region of jaw since 2 months. (Fig.1) She gave history of trauma to upper teeth 2 months back, few days after which she noticed small gingival growth that region, which was surgically removed but it reappeared in 4 days. The patient gave history of pigmentation in the same area since last 40 years, and had hyperthyroidism since last 10 years. The habit of tobacco quid chewing and paan chewing since 15 years. Intraoral examination revealed, gingival growth 1 x 1.5 cm in the labial aspect of 22,23. (Fig.2) The inter-dental papilla was swollen and covered the labial aspect of involved teeth partially. The growth was sessile and appeared to arise from the inter-dental papilla of 22 and 23 and the attached gingiva. Black pigmentation was seen on the gingivae from 11 to 24 labial as well as palatal aspect. (Fig.2, 3) Intra oral periapical radiograph did not reveal any abnormality (Fig.4). Based on the clinical appearance, it was provisionally diagnosed as Nevus transforming to Oral Melanoma, oral melanotic macule. Incisional biopsy was performed after the routine hematologic investigations were within normal limits. (Fig.5) Three small pieces of gross tissue were received for histopathological examination soft in consistency and brownish black colored. (Fig.6) Hematoxylin & Eosin stained sections of these tissues revealed a parakeratinised stratified

squamous epithelium with atypical melanocytes throughout the epithelium and also invading in the underlying connective tissue stroma. These features suggested the diagnosis of Oral Melanoma. (Fig.7,8,9) Immunohistochemical staining with HMB45 showed positive results and thus the diagnosis was confirmed.(Fig 10)

Fig.1 showing the clinical photograph of the frontal profile of the patient



Fig.2 showing pigmentation in relation to enlarged gingivae in left maxillary anterior region

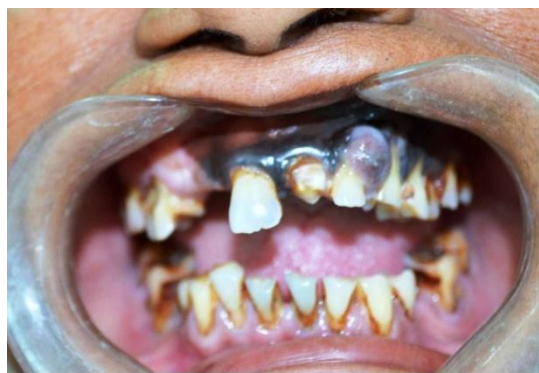

Fig.3 showing pigmentation in relation to the palatal aspect of enlarged gingivae in left maxillary anterior region

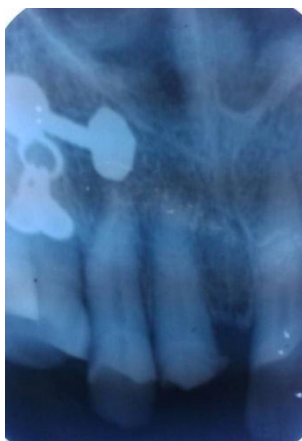

Fig.4 showing the IOPAR in the affected region with no distinct findings

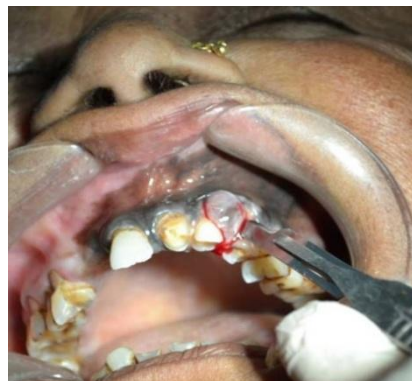

Fig.5 showing the affected region being biopsied

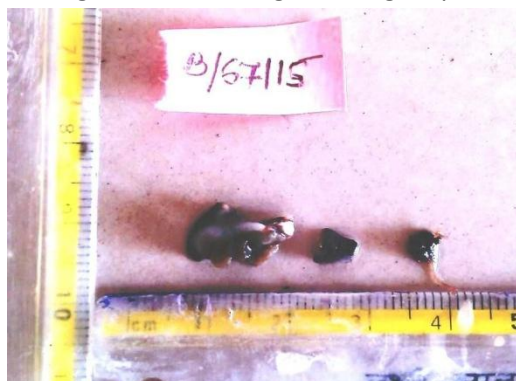

Fig.6 showing the excised gross specimen

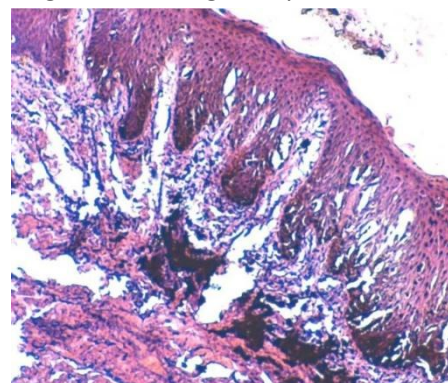


Fig.7 showing H&E stained section showing pigmentation throughout the epithelium (low power, 10X)

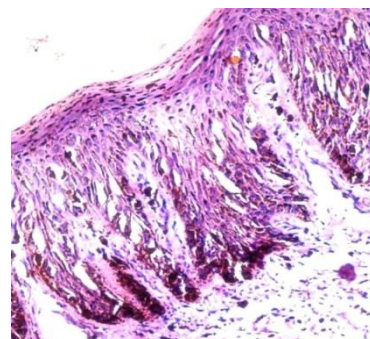


Fig.8 showing H&E stained section with parakeratinised stratified squamous epithelium with melanocytic pigmentation (low power, 10X)

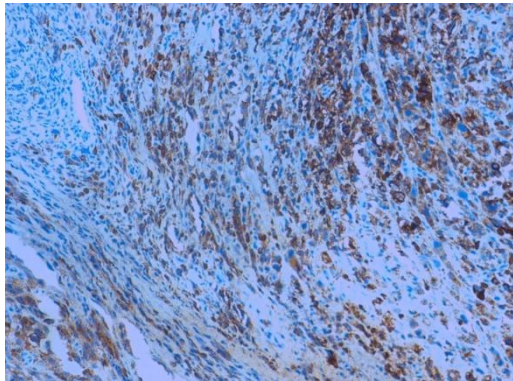


Fig.9 showing atypical, spindle shaped, malignant melanocytes (high power, 40X)

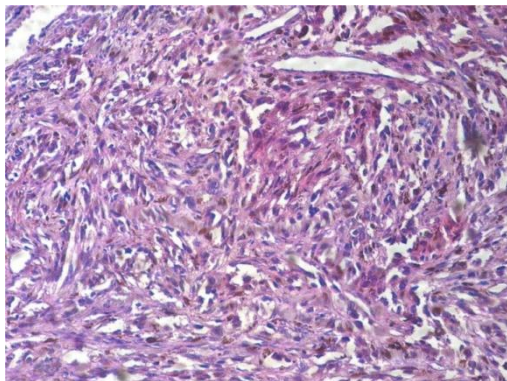
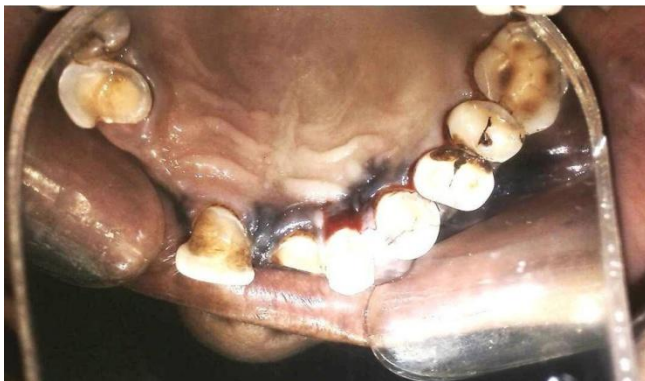

Fig. 10 showing HMB 45 positivity (scanner view)



Discussion: Oral malignant melanomas are extremely rare lesions, accounting for approximately 2% of all melanomas with a male preponderance. The initial symptom and sign of oral melanoma is generally a pigmented growth or swelling showing a smooth, intact or ulcerated overlying mucosa. Satellite foci may surround the primary tumour. Uniformly brown or black or variation of colour, with black, brown, grey, purple, and red shades, or depigmentations may be seen. Some of these tumours are amelanotic which are rare, and are

difficult to diagnose. Oral Melanoma has an initial phase characterized by radial growth followed by a phase of invasion of the underlying tissues (the so-called “vertical growth phase”).¹¹ A simple TNM clinical staging, recognizing three stages, has shown to be of prognostic value. A recent histopathological microstaging for Stage I subclassifies it into three levels:¹²

Stage I: Primary tumour present only (Tany NOMO)

Level I: pure in situ melanoma without evidence of invasion or in situ melanoma with “micro-invasion”

Level II: invasion up to the lamina propria

Level III: deep skeletal tissue invasion into skeletal muscle, bone, or cartilage

Stage II: Tumour metastatic to regional lymph nodes (Tany N1M0)

Stage III: Tumour metastatic to distant sites (Tany Nany M1)

The traditional histologic staging for cutaneous melanoma (e.g., Clark level) cannot be applied to the mucosa because the mucosa lacks histologic land marks analogous to papillary and reticular dermis. Breslow thickness, the single most important histologic prognostic factor in localized cutaneous melanoma, has not been found to be useful in head and neck malignant melanoma.¹³ Greene *et al* suggested the following criteria for a lesion to be considered as primary malignant melanoma of the oral cavity: 1) demonstration of malignant melanoma both histologically and clinically; 2) the presence of junctional activity; and 3) the inability to demonstrate any other primary site. Based on these criteria, this case could be considered as a primary oral malignant melanoma.¹⁴ Malignant cells of Oral Melanoma shows presence of atypical melanocytes showing wide range of shapes, including spindle, plasmocytoid, clear cell, and epithelioid ones with considerable pleomorphism with large, irregular hyperchromatic nuclei, and prominent nucleoli, and have readily detectable mitotic activity.

In most instances, the cells of melanoma contain melanin granules, but they may demonstrate no melanin production (amelanotic melanoma) which may mimic poorly differentiated carcinoma. The melanocytes may be arranged irregularly at the epithelial connective tissue interface or may be distributed in aggregates. Oral Melanoma can be histologically sub-classified into

(1) in-situ melanoma, which is limited to the epithelium and the epithelial-connective tissue interface; (2) melanomas with an invasive pattern, in which the neoplasm extends into the connective tissue; (3) melanomas with a combined pattern of invasive melanoma with in situ component.¹¹

Differential diagnosis for oral melanoma includes oral melanotic macule, smoking-associated melanosis, melanoplakia, pituitary-based Cushing's syndrome, post inflammatory pigmentation, melanoacanthoma, melanocytic nevi of the oral mucosa, blue nevi, spitz nevi, Addison's disease, Peutz-Jeghers syndrome, amalgam tattoo, Kaposi's sarcoma, physiologic pigmentation and many other conditions sharing macroscopic characteristics with oral melanoma.¹⁵ For distinguishing melanomas from other tumours immunohistochemical stains should be used for accurate diagnosis which includes S-100 protein, gp100 (HMB-45) and Mart-1 (Melan-A), these can also be useful in identification of micrometastases in lymph nodes. Tyrosinase, microphthalmia transcription factor in adjunct can also be used as to confirm the diagnosis. The Antibody HMB-45 reacts with the melanosomal glycoprotein gp 100, showing a positive staining in active early melanosome formation and showing epithelioid lesions intensely immunoreactive for HMB-45. It is considered as more specific but less sensitive than the S- 100 protein, an acidic calcium binding protein, which is a very sensitive marker for nevus and melanoma cells, and even spindled lesions appear intensely immunoreactive for S-100 protein.¹⁶

Melan-A is considered to be specific for melanoma cell lines, as a product of the MART-1 gene it is a melanocytic differentiation marker which is recognized on melanomas as an antigenic target of T lymphocytes.¹⁷ Ki-67 is commonly used as an adjunct in distinguishing benign nevi from melanoma.¹⁸ Fine needle aspiration or exfoliative cytology of primary pigmented lesions is contraindicated. It has been suggested that cutting into a malignant neoplasm during an incisional biopsy or other invasive procedure could result in accidental dissemination of malignant cells within the adjacent tissues (seeding) or even in the blood or lymphatic stream, with the subsequent risk of local recurrence, or regional or distant metastasis. The most common sites of metastasis are lung, bone, brain, and liver, with widespread involvement occurring in advanced disease. CT and MRI studies should be undertaken to explore regional metastases to the submandibular and cervical

lymph nodes.¹ Excision of the primary lesion is preferred using an intraoral approach involving at least 1.5 cm of healthy tissue. Neck dissection should be carried out for cases with preoperatively confirmed lymph node metastases and the choice of the neck dissection modality should be determined by the extent and the level of the nodes.¹⁹

Surgery can be combined with radiotherapy, chemotherapy, or immunotherapy even though the effectiveness of such therapies is mostly unknown. Other irradiation modalities such as intraoral mould (⁶⁰Co, ¹⁹²Ir, or ¹⁹⁸Au), intraoral electron beam or interstitial brachytherapy have also been used with variable results.¹² Dacarbazine, platinum analogs, nitrosoureas, microtubular toxins, dimethyl triazeno imidazole carboxamide (DTIC), nimustine hydrochloride, or vincristine have been used as adjuvant therapy or postoperative chemotherapy. IFN- α 2b, IL-2, BCG, anti-Fas antibody, IL2, and cytokines have also shown varied results.¹ The prognosis of Oral Melanoma is poor. A tumour thickness greater than 5 mm, presence of vascular invasion, necrosis, polymorphous tumour cell morphology and the inability to properly resect the lesions with negative margins have been associated with poor survival in patients with primary Oral melanoma. Gingival melanoma has a better 5-year survival rate than palatal melanoma.²⁰

Conclusion: Primary oral mucosal melanomas are exceedingly rare and biologically aggressive malignancies. Oral Melanomas clinically mimic many other pigmented lesions of the oral cavity and thus is overlooked or clinically misinterpreted as a benign pigmented process until it is well advanced. Thus immediate treatment should be instituted to facilitate its early diagnosis, as a prerequisite for timely treatment and better prognosis of this rare pathology.

References:

1. Meleti M, Ren'e Leemans C, Mooi WJ, Vescovi P, van der Waal I. Oral malignant melanoma: A review of the literature. *Oral Oncology* 2007;43:116-121.
2. Ullah H, Vahiker S, Singh M, Baig M. Primary malignant mucosal melanoma of the oral cavity: A case report. *Egypt J Ear Nose Throat Allied Sci* 2010;11:48-50.
3. Guevara-Canales Janet O, Gutierrez – Morales Mario M, Sacsquispe-Cortreras Sonia J, Sanchez-Lihon Juvenal, Morales-Vadillo Rafael. Malignant Melanoma of the Oral Cavity: Review of the

- Literature and Experience in a Peruvian Population. *Medicina Oral, Patología Oral y Cirugía Bucal* 2012;17:e206-e211.
4. Elomrani F, Mouzount H, Ouziane I, Khmamouch R, Ikhoyali S, Boukir A, et al. Melanoma of the Oral Cavity: About Two Cases and Review of Literature. *International Journal of Clinical Medicine* 2013;4:191-194.
 5. Reddy CR, Ramachandra T, Ramulu C. Primary malignant melanoma of the hard palate. *J Oral Surg* 1976;34:937-939.
 6. Gu GM, Epstein JB, Morton TH Jr. Intraoral melanoma: Long-term follow-up and implication for dental clinicians: A case report and literature review. *Oral Surg Oral Med Oral Pathol Oral Radiol Endod* 2003;96:404-413.
 7. Cockerell CJ. The pathology of melanoma. *Dermatol Clin* 2012;30:445-468.
 8. Ulusal BG, Karatas O, Yildiz AC, Oztan Y. Primary malignant melanoma of the maxillary gingiva. *Dermatol Surg* 2003;29:304-307.
 9. Singh M, Lin J, Hocker TL, Tsao H. Genetics of Melanoma Tumorigenesis. *British Journal of Dermatology* 2008;158:15-21.
 10. D'Silva NJ, Kurago Z, Polverini PJ, Hanks CT, Paulino AF. Malignant Melanoma of the Oral Mucosa in a 17-Year-Old Adolescent Girl. *Archives of Pathology & Laboratory Medicine* 2002;126:1110-1113.
 11. Barker BF, Carpenter WM, Daniels TE, Kahn MA, Leider AS, Lozada-Nur F, et al. Oral mucosal melanomas: The WESTOP Banff workshop proceedings. *Oral Surg Oral Med Oral Pathol Oral Radiol Endod* 1997;83:672-679.
 12. Patel SG, Prasad ML, Escrig M, Singh B, Shaha AR, Kraus DH, et al. Primary mucosal malignant melanoma of the head and neck. *Head and Neck* 2002;24:247-257.
 13. Prasad L. Primary Mucosal Melanoma of the Head and Neck: A Proposal for Microstaging Localized, Stage I (Lymph Node-Negative) Tumors. *Cancer* 2004;10:
 14. Greene GW, Haynes JW, Dozier M, Blumberg JM, Bernier JL. Primary malignant melanoma of the oral mucosa. *Oral Surg Oral Med Oral Pathol* 1953;6:1435-1443.
 15. Hashemi MS Pour. Malignant Melanoma of the Oral Cavity: A Review of Literature. *Indian Journal of Dental Research* 2008;19:47-51.
 16. Blessing K, Sanders DS, Grant JJ. Comparison of immunohistochemical staining of the novel antibody melan-A with S100 protein and HMB-45 in malignant melanoma and melanoma variants. *Histopathology* 1998;32:139-146.
 17. Kawakami Y, Eliyahu S, Delgado CH, Robbins PF, Rivoltini L, Topalian SL, et al. Cloning of the gene coding for a shared human melanoma antigen recognized by autologous T cells infiltrating into tumor. *Proc Natl Acad Sci USA* 1994;91:3515-3519.
 18. Ohsie SJ, Peter G. Immunohistochemical Characteristics of Melanoma. *Journal of Cutaneous Pathology* 2008;35:433-444.
 19. Umeda M, Shimada K. Primary malignant melanoma of the oral cavity: Its histological classification and treatment. *British Journal of Oral and Maxillofacial Surgery* 1994;32:39-47.
 20. Hicks MJ, Flaitz CM. Oral mucosal melanoma: Epidemiology and pathobiology. *Oral Oncology* 2000;36:152-169.

Conflict of interest: None

Funding: None

Cite this Article as: Gadodia P, Wadhvani R, Dhobley A, Patil N, Patil V, Murgod V. Malignant Melanoma: A Case Report With Literature Review. <i>Natl J Integr Res Med</i> 2016; 7(1): 120-124
--