

Dermoid Cyst: A Case Report

Dr. Sonal Madan*, Dr. Deval Mehta**, Dr. Smit Desai***

*Professor, **Professor and HOD, ***P.G.Resident, Department of Oral And Maxillofacial Surgery, College Of Dental Sciences And Research Centre, Ahmedabad, Gujarat, India

Abstract: Dermoid cysts of the Pre-auricular area are extremely rare. We report one case of Pre-auricular dermoid Cyst. Case involved a gradually enlarging mass of the superior and anterior aspect of the pre-auricular region on left side. During the operation, a lesion was found just under the skin, not fixed parotid or adjacent cartilage. Histologically, specimen contained desquamated squamous epithelium and keratin in the lumen. Dermoid cysts at the pre auricular region are rare and a diagnostic challenge, but, it should be considered as a differential diagnosis in cases of painless long standing enlargement of parotid gland which is soft in consistency. [Desai S NJIRM 2015; 6(6):113-115]

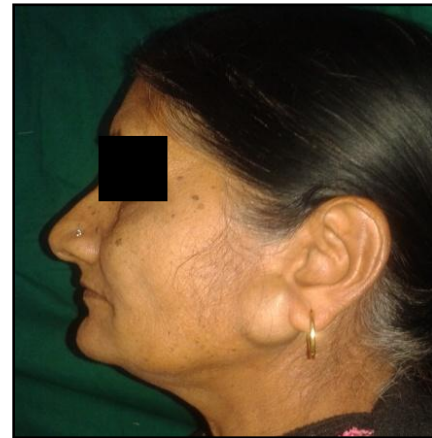Key Words: Dermoid, Epidermoid, Pre-Auricular lesions

Author for correspondence: Dr.Smit Desai, Department of Oral And Maxillofacial Surgery, College Of Dental Sciences And Research Centre, Ahmedabad: 382 115. E- mail: smitdesai11@yahoo.com

Introduction: Dermoid cyst is a benign congenital tumor formed by cells abnormally separated at the period of fusion of viviparous tissues.¹ Dermoid cyst is known as proliferation of epithelial tissue of the congenital tumor, contained in the first pharyngeal arch (branchial arch) and medial epithelial seam of the second pharyngeal arch, but can occasionally be acquired. This cyst can be histologically classified as dermoid cyst, epidermoid cyst, and teratoma, and it consists of stratified epithelium lined by laminated keratin material containing adnexal structures of skin, such as sebaceous gland, sweat gland, hair follicles, and hair.^{1,2}

Case History: A 58-year-old female patient presented to our outpatient department with a complaint of painless swelling on the left side of the face in front of the ear for 15 years. The swelling was insidious in onset and gradually progressed to reach the present size. There was no history of pain, fever, difficulty in swallowing, or any discharge from the swelling. There were no other swellings present anywhere else in the body. There wasn't any sign of paresthesia. There was also no history of trauma or any previous surgeries reported in the facial region. On examination, there was a localized spherical swelling in the left pre auricular region. The swelling was 4 × 3 cm in size and extended around 2 cm below the lobule of the left ear and absent of punctum (figure-1). There was lifting of the ear lobe and the colour over the swelling was of bluish in colour compare to skin colour with no surface discharge. On palpation, the swelling was doughy, pitting in consistency, non-tender, and non-pulsatile and was movable below the skin. There were not any palpable lymphnodes. Intraorally, there was no swelling present and completely edentulous arch.

Figure 1



Ultrasound was carried out and it showed hyperechoic cystic lesion which displaces parotid gland posteriorly. There was no vascularity in the lesion and no evidence of calculi in the duct or glands. So the lesion was confirm to the epidermal layer which is not involving parotid gland. Blood chemistry was absolutely normal there is no raised counts. Dermoid cyst, Epidermoid cyst, and lipoma were made as our Provisional diagnosis.

Patient underwent surgical intervention under general anaesthesia for excisional biopsy. skin incision was given with 15 no blade as the skin was very fragile careful dissection was done (figure-2). the plane was differentiated with methylene blue and lesion was removed without touching the parotid gland (figure-3). Skin Closure was done with ethilon 5-0 (figure-4). histopathological examination revealed stratified squamous epithelium with an intraluminal laminated keratinized material confirming the diagnosis of Dermoid cyst in the left pre auricular region (figure-5). Post operatively the healing was uneventful and

regular follow up for a year showed no signs of recurrence (figure-6).

Figure 2

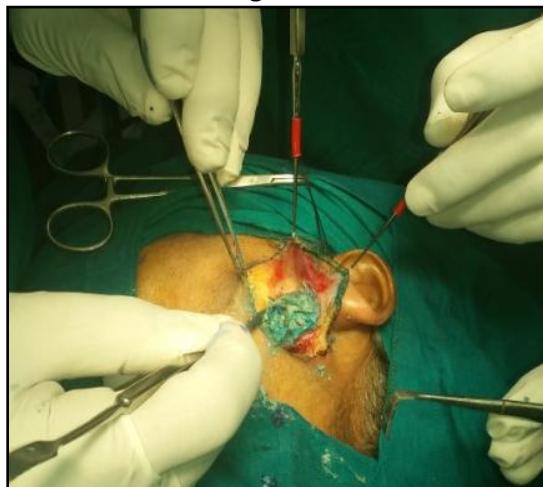

Figure 3

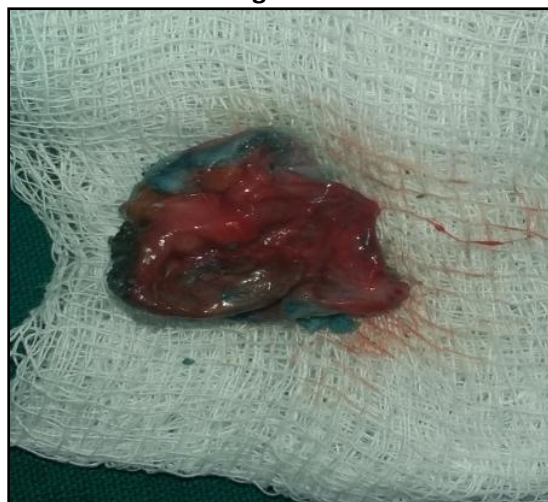

Figure 4

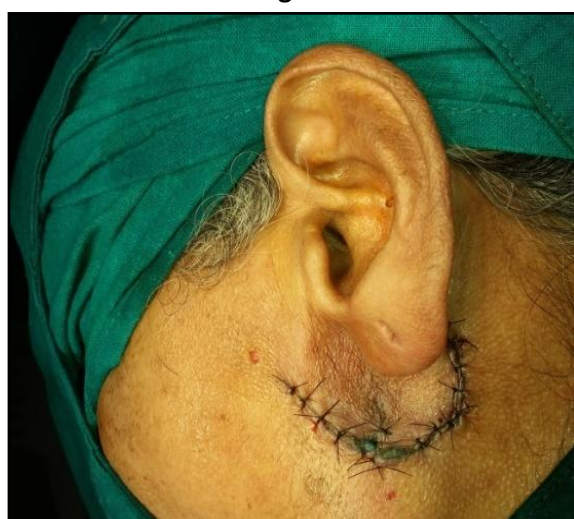
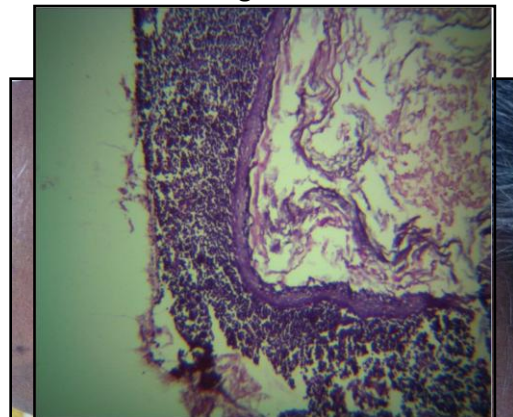


Figure 5



Discussion: Dermoid cysts arise from developmental epithelial remnants or they are secondary to traumatic implantation of epithelial fragments.³ Dermoid cyst of parotid gland is a very rare benign cystic lesion and is seen in young to middle age adults.⁴ The cysts clinically are painless swellings without any attachment to the overlying skin or involvement of facial nerve.⁵ If the cyst stays for longer time, it might get infected forming sinus or fistulas.⁶ The different causes of swelling in the parotid region may include branchial cleft cyst which is “congenital”, or may be “acquired” due to inflammation, obstruction, neoplasm, calculi and trauma.⁴ Also if it occurs in the submandibular region, it can be mistaken for salivary gland abscess, neoplasm, tuberculous lymphadenitis, metastatic node, or any cyst.⁷

The diagnosis can be proven by various investigations like, ultrasound, and CT . The diagnosis of the cystic lesion is challenging due to difficulty in determining the benign or malignant processes. Malignant lesions are frequently suspected when there is a rapid enlargement with associated lymphadenopathy or facial nerve paralysis.⁴

Surgical excision of lesion is the treatment of choice.^{1,2,6,8} Care should be taken not to rupture the cyst which can lead to recurrence and also to preserve the vital structures during surgery.⁶ Histopathological examination of the cyst is required for confirmation of diagnosis. Histologically, dermoid cyst has stratified squamous epithelial lining and is usually filled with cheesy material or keratin.in our case histologically findings were same. Recurrence is very rare.^{8,9,10}

Conclusion: Dermoid cysts at the pre auricular region are rare and a diagnostic challenge, but, it should be considered as a differential diagnosis in cases of painless long standing enlargement of parotid gland which is soft in consistency.

References:

1. Moon IH, Lee WH, Joo JB, Cho JE. A case of postauricular dermoid cyst. *Korean J Otolaryngol-Head Neck Surg* 2005;48:1294-6.
2. Ikeda M, Muto J, Omachi S. Dermoid cyst of the auricle: report of two cases. *Auris Nasus Larynx* 1990;16:193-7.
3. H. G. Burkitt, C. R. G. Quick, and D. T. Gatt, *Essential Surgery: Problems, Diagnosis and Management*, Churchill Livingstone, Langmans, 1990.
4. C. Sanglee and H. Kaunkin, "Iatrogenic epidermoid cyst in the parotid gland: a case report," *Journal of the Korean Association of Oral and Maxillofacial Surgeons*, vol. 37, pp. 237–240, 2011.
5. D. Baschinsky, A. Hameed, and S. Kehyani, "Fine needle aspiration cytological features of dermoid cyst of parotid gland. A report of two cases," *Diagnostic Cytopathology*, vol. 20, no. 6, pp. 387–388, 1999.
6. P. N. Hegde, H. L. Kishan Prasad, Y. Sunil Kumar et al., "A rare case of an epidermoid cyst in the parotid gland which was diagnosed by fine needle aspiration cytology," *Journal of Clinical and Diagnostic Research*, vol. 7, no. 3, pp. 550–552, 2013.
7. J. Rosai, "Major and minor salivary glands," in *Ackermans Surgical Pathology*, R. J. Mosby, Ed., pp. 815–856, Mosby, St Louis, Mo, USA, 8th edition, 1996.
8. R. Kar, V. Thorawade, M. Jagade et al., "An unusual case of epidermal cyst in submandibular space," *International Journal of Otolaryngology and Head & Neck Surgery*, vol. 3, pp. 213–215, 2014.
9. G. W. Back, F. Fahmy, and A. Hosni, "Submandibular salivary duct cyst mimicking an external laryngocele," *Journal of Laryngology and Otolaryngology*, vol. 114, no. 4, pp. 305–307, 2000.
10. P. Mukunyadzi, "Review of fine-needle aspiration cytology of salivary gland neoplasms, with emphasis on differential diagnosis," *American Journal of Clinical Pathology*, vol. 118, pp. S100–S115, 2002.

Conflict of interest: None
Funding: None
Cite this Article as: Madan S, Mehta D, Desai S. Dermoid Cyst: A Case Report. <i>Natl J Integr Res Med</i> 2015; 6(6): 113-115