



Small incision cataract surgery and phacoemulsification: A comparison of central foveal thickness by OCT

Junaid S Wani², Surraya I Parray^{1*}, Afroz A Khan²

ABSTRACT

Aim

There is huge backlog of cataracts in India, which is the most common cause (62.6%) of reversible blindness. Since small incision cataract surgery is equally good and safe procedure for conducting cataract extractions we conducted a study to see the effect of phacoemulsification and small incision cataract surgery on foveal thickness by optical coherence tomography.

Materials and methods

In a prospective study 60 patients were randomly distributed to undergo small incision surgery or phacoemulsification (thirty in each group). They were evaluated selectively and subjected to Preoperative OCT and Postoperative OCT at Week 1 and 4 respectively by Spectral Domain Optical Coherence Tomography and the values of Central Foveal Macular Thickness (CFT) were compared.

Results

In phacoemulsification group, the average central foveal thickness (CFT) preoperatively, at week 1, week 4 was 200.33, 207.33 and 201.67 respectively. In SICS group, the average CFT preoperatively, at week 1 and week 4 was 203.66, 215.33 and 211.86 respectively. The mean CFT in phacoemulsification and SICS group was compared at week 1 post operatively and week 4 and the difference was statistically non-significant, ($p=0.58$ at week 1 and 0.057 at week 4).

Conclusion

There is subclinical increase in foveal macular thickness postoperatively in both phacoemulsification and small incision cataract surgery. The difference in degree of increase between the two groups was statistically insignificant. In our opinion small incision cataract surgery is safe and effective mean of treating cataracts, especially in a country like India which has huge backlog of cataract patients and where majority of trainees use SICS for cataract surgery.

Keywords: Cataract, Macular Edema, OCT, SICS

INTRODUCTION

There are nearly 45 million blind people in the world, of which 12 million are living in India.¹ As per the world health organization (WHO) estimates the blind population will double by 2020 due to rise in

population and longevity. Cataract is the commonest cause of blindness (62.6%) followed by uncorrected refractive errors (19.7%), corneal blindness (0.90%), glaucoma (5.80%), surgical complications (1.20%),

GJMEDPH 2015; Vol. 4, issue 6

¹Registrar, Department of Ophthalmology, Government Medical College, Srinagar

²Associate Professor, Department of Ophthalmology, Government Medical College, Srinagar

*Corresponding Author:

Surraya I Parray
Department of Ophthalmology,
Government Medical College, Srinagar, J
and K, India
surrayaparray@gmail.com

Conflict of Interest—none

Funding—none



posterior capsular opacification (0.90%) and posterior segment disorders (4.70%).²

Cataract is by far the most common reversible cause of blindness. Management of cataract is by planned surgery, which at present includes phacoemulsification and small incision cataract surgery. A closer look at these two procedures reveals phacoemulsification to be the procedure of choice of most surgeons and in a survey almost 100% of responding surgeon members of the American society of cataract and refractive surgery preferred it. The advantages include small incision, less chance of induced astigmatism and shorter hospital stay. In comparison small incision cataract surgery can be done for any cataract type and is preferred procedure in specific situations like in cases where the nucleus is very dense, pupil dilates poorly, posterior synechia are present or zonular integrity is a question. Small incision cataract surgery seems a better choice in such situations and can provide greater margin of safety. However, the main disadvantages compared with phacoemulsification include greater chance of induced astigmatism, lesser stability of the postoperative refraction, greater degree of early post-operative inflammation and a higher rate of posterior capsular opacification. Majority of the trainees, especially in developing countries learn the manual small incision technique initially followed by phacoemulsification.^{3,4} Cystoid macular edema (CME) is a painless disorder which affects the central retina or macula. Since its first description and recognition in 1974, CME has been recognized as the most common cause of decreased vision postoperatively in case of uneventful cataract surgeries.^{5,6} The aim of our study was to compare the effect small incision cataract surgery and phacoemulsification on central foveal thickness using optical coherence tomography.

MATERIALS AND METHODS

The study was conducted in the postgraduate department of ophthalmology, government medical

college, Srinagar, India over a period of one year from March 2013 to March 2014. A total of 60 patients were included in the study. Patients underwent thorough ophthalmological evaluation which included preliminary torch light, visual acuity, slit lamp examinations, detailed fundus examination, intraocular pressure, and optical coherence tomography (OCT) which was done thrice in each patient. First OCT was done preoperatively and subsequent two OCTs were done postoperatively at week 1 and week 4. Central foveal thickness (CFT) was noted and along with visual acuity on each visit. Sixty patients were randomly distributed to undergo small incision surgery or phacoemulsification (thirty in each group). Patients included had various morphological cataracts. Patients with complicated cataracts, post uveitic, diabetic, pseudoexfoliative cataracts etc and where fundus could not be visualized preoperatively were not included in the study. Data was computed and analyzed using SPSS software version 11. The p value of <0.05 was considered significant.

RESULTS

In our study, patients were randomly divided into two groups, phacoemulsification and SICS group each containing 30 patients. There was no difference between the groups in terms of age, gender and pre-operative visual acuity (0.09). The central foveal thickness was measured in both groups at day 0, week 1 and week 4. The comparison between the two groups is given in table 1.

On day 0, the mean foveal thickness in SICS group was 200.3 (range 180-230) and in phacoemulsification group was 203.6 (range 170-240). At week 1, the mean foveal thickness showed an increase in both groups; in SICS group it was 207.3 (range 200-240) and in phacoemulsification group it was 215.3 (range 180-250). At week 4, the mean foveal thickness in SICS group had come down to 201.66 (range 190-230) and in phacoemulsification group it reduced to 211.8 (range 180-290).



Table 1 Central Foveal thickness in Phacoemulsification and SICS groups at pre operatively and on follow up

	PHACO EMULSIFICATION			SICS		
	Day 0	Week 1	Week 4	Day 0	Week 1	Week 4
N	30	30	30	30	30	30
MIN	180	200	190	170	180	180
MAX	230	240	230	240	250	290
AVG MEAN	200.333	207.333	201.667	203.667	215.333	211.867
SD	13.767	12.015	13.917	19.911	18.896	24.963

The pattern of change in mean central foveal thickness (CFT) in phacoemulsification group and SICS group at week 1, week 4 is depicted in Figure 1 and Figure 2 respectively. The mean CFT in phacoemulsification and SICS group was compared

at week 1 post operatively and week 4 and the difference was statistically non-significant as depicted in table 2. ($p=0.58$ at week 1 and 0.057 at week 4)

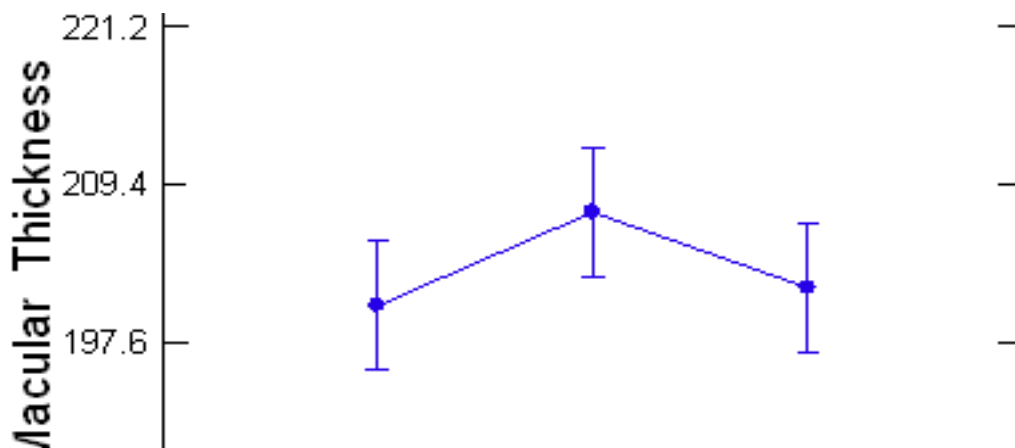


Figure 1 Mean macular thickness in Phacoemulsification Group

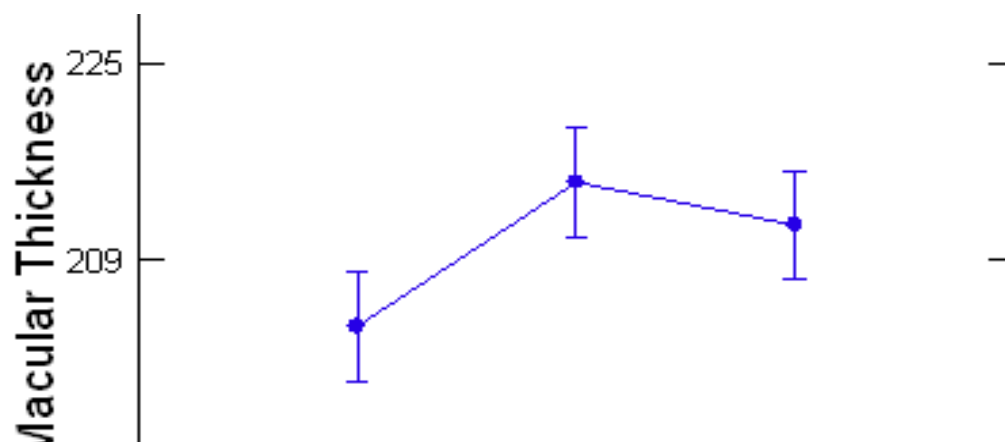


Figure 2 Mean macular thickness in SICS Group



Table 2 Comparison of central foveal thickness in Phacoemulsification and SICS groups

Week	Phacoemulsification		SICS	Significance
	Avg. Mean	Avg. Mean	P Value	
Week 1	207.33	215.333	0.055	Insignificant
Week 4	201.667	211.867	0.057	Insignificant

DISCUSSION

CME is the cystic accumulation of intra-retinal fluid in the outer plexiform and inner nuclear layer of the retina as a result of breakdown of blood retinal barrier. We conducted the study in postgraduate department of ophthalmology to see the effect of both phacoemulsification and small incision cataract surgery and followed them to a period of month post operatively. In both groups we found the there was an increase in central foveal thickness postoperatively at end of first week and at the end of 4 week. The increase in thickness was more at the end of first week compared to 4th week. The difference between foveal thickness between the SICS and phacoemulsification group was statistically insignificant. This was comparable and consistent with what was reported by Gerasmos and et al who showed that thickness of the retina preoperatively was significantly smaller (150 ± 18.8) then the thickness of retina on week 1 (171.8 ± 21) and week 2 (159 ± 19) and returned to initial level at week 4; however, changes in macular thickness could still be found detectable at week 4.⁷ Biro and colleagues found no difference between the preoperative and postoperative day 1 foveal and perifoveal retinal thickness.⁸ Degenring et.al found increase in foveal and perifoveal diameter on postoperative days 7,30 and 60.⁹ Cheng et al reported no increase in mean foveal thickness at week 1 postoperatively.¹⁰

CONCLUSION

There is subclinical increase in foveal macular thickness postoperatively in both phacoemulsification and small incision cataract surgery. The difference in degree of increase between the two groups was statistically insignificant.

In our opinion small incision cataract surgery is safe and effective mean of treating cataracts, especially in a country like India which has huge backlog of

cataract patients and where majority of trainees use SICS for cataract surgery.

REFERENCES

1. Jose R. Present status of the national programme for control of blindness in India. *Commun Eye Health J Indian*. 2008;21:5103-4.
2. Verma R, Khanna P, Prinja S, Rajput M, Arora V. The National programme for control of blindness in India. *Australas Med J*. 2011;4(1):1-3.
3. Blumenthal M, Assia E. Extracapsular cataract extraction. In : Nordan LT, Maxwell WA, Davidson JA, eds. *The surgical rehabilitation of vision*. New York: Gower Medical Publishing, 1992:10:1-10.
4. Thomas R, Naveen S, Jacob A. Visual outcome and complications of residents learning phacoemulsification. *Indian J Ophthalmol* 1997;45:215-219.
5. Flach AJ. Cyclo-oxygenase inhibitors in ophthalmology. *Surv Ophthalmol*. 1992;36(4):259-284.
6. Flach AJ. The incidence, pathogenesis and treatment of cystoid macular edema following cataract surgery. *Trans Am Ophthalmol Soc*. 1998;96:557-634
7. Georgopoulos GT, Papaconstantinou D, Niskopoulou M, Moschos M, Georgalas I, Koutsandrea C. Foveal thickness after phacoemulsification as measured by optical coherence tomography. *Clin Ophthalmol*. 2008; 2(4): 817-820.
8. Biro Z, Balla Z, Kovacs B. Change of foveal and perifoveal thickness measured by OCT after phacoemulsification and IOL implantation. *Eye (Lond)*. 2008 Jan; 22(1):8-12.
9. Degenring RF, Vey S, Kampeter B, Budde WM, Jonas JB, Sauder G. Effect of uncomplicated phacoemulsification on the central retina in diabetic



- and non-diabetic subjects. Graefes Arch Clin Exp Ophthalmol. 2007; 245(1):18-23.
10. Cheng B, Liu Y, Liu X, Ge J, Ling Y, Zheng X. Macular image changes of optical coherence tomography after phacoemulsification. Zhonghua Yan Ke Za Zhi. 2002; 38(5):265-7.