

**A rare case of Gastric Perforation in an Infant with  
Bronchopneumonia: A case report and Review of Literature**

Jayakumar P<sup>1</sup>, Hemanthkumar B<sup>2</sup>, Haris Vijila Rani M<sup>3</sup>

<sup>1</sup>Department of General Surgery, <sup>2,3</sup> Department of Pediatric Surgery,  
Government Rajaji Hospital and Madurai Medical College,  
Madurai, Tamilnadu, India

---

**ABSTRACT**

Gastric perforation in infant is a rarely reported but with high mortality condition. Here we report a case of gastric perforation associated with bronchopneumonia and gastric ulcer disease in an infant. Early diagnosis and management are the important factors in reducing the mortality.

**Key Words:** Bronchopneumonia, Gastric Perforation, Gastric Ulcer, Infant

Corresponding author mail: [drjayakumar1999@gmail.com](mailto:drjayakumar1999@gmail.com) M: +91 9444512351

Conflict of interest: Nil

Case report is Original: Yes

---

**INTRODUCTION**

Gastric perforation in infant is a rarely reported condition. Gastric perforation is associated with unclear etiology and high mortality. Highest mortality was noted in gastric perforation among the gastrointestinal perforations. Mortality ranges from 22% to 88% in the reported literature [1-4,9,10,20]. Etiological factor implicated for gastric perforation was idiopathic, iatrogenic, ulcer disease, Aerophagy, Gastric distension, difficult airway management, esophageal intubation, Nasal ventilation, Mechanical ventilation, preterm infants, Low birth weight, anomalous babies, Sepsis,

Pneumonia, Necrotizing enterocolitis, Trachea esophageal fistula, Meconium plug and Corticosteroid treatment [1-9,11-17].

Here we report a rare case of gastric perforation at the age of three months due to bronchopneumonia and stress induced gastric ulcer disease.

**CASE REPORT**

A three month old, 3 kg female infant admitted in pediatric ICU with Complaints of breathlessness for 10 days and history of (h/o) fever for four days. The infant was brought from an orphanage home with h/o aspiration of feeds followed by breathlessness, treated with IV fluids and antibiotics

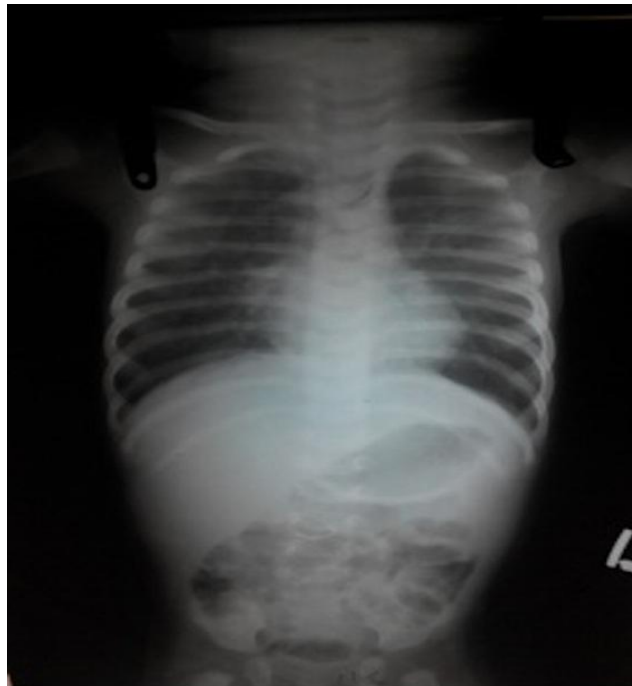
and the infant was not improving, due to progressive increase in respiratory distress and fever infant was referred here for further management. h/o low grade continuous fever for 11 days which was relieved with antipyretic medication. h/o multiple abscess in the scalp since the admission in home. Past history is not known.

On examination child is anemic, dyspneic and tachypenic.

Chest X-ray shows bilateral infiltration and haziness at Left upper and Right middle lobes (Figure.1).

Intercostal and subcostal retraction noted. Respiratory system has no added sounds and cardiovascular system is clinically normal. Abdomen not distended, Soft, Bowel sounds heard, liver palpable 5cms below costal margin, span-8cm, firm in consistency, not tender. Spleen is not palpable.

**Figure1:** X-ray before Gastric Perforation



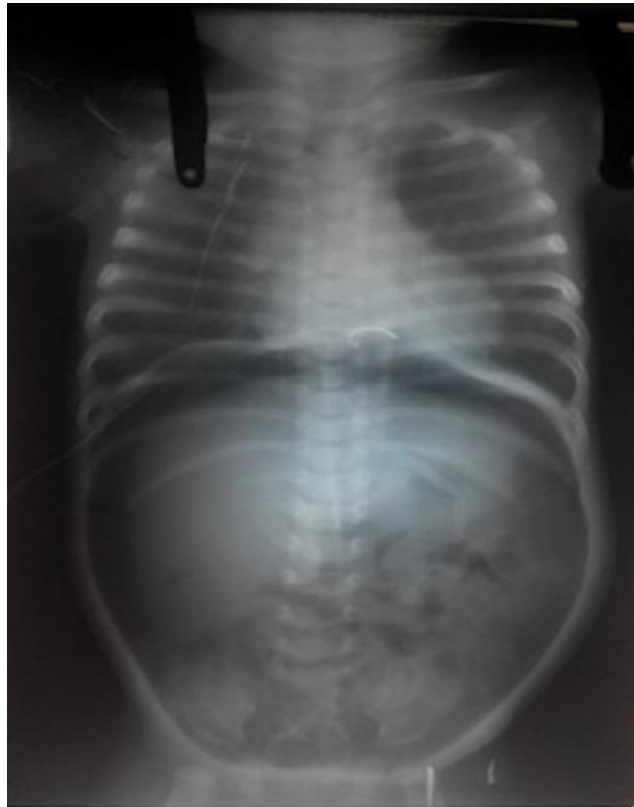A patient was provisionally diagnosed as either Aspiration pneumonitis/ or Bronchopneumonia and treated with nasal O<sub>2</sub>, Nil Per Oral (NPO), IV fluids antibiotics and

antipyretics. Patient improved on the second day of admission. Third day the child had an episode of melena. Transfusion of Whole Blood and Fresh Frozen Plasma are given. Melena and

respiratory distress reduced in the following day. But the child developed abdominal distension which was progressive which leads to respiratory

distress again, X-ray abdomen erect shows pneumoperitonium (Figure.2) but not in the previous X-ray taken before abdominal distension.

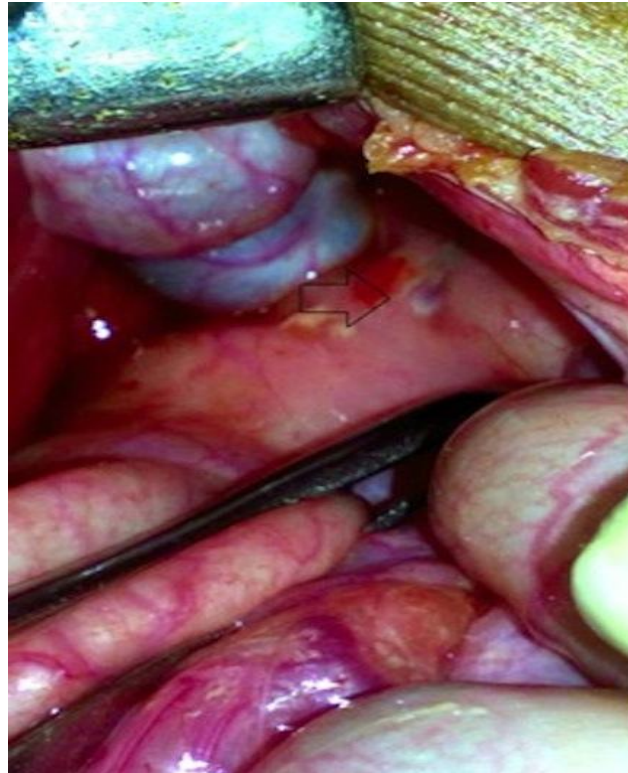**Figure 2:** X-ray after Gastric perforation showing pneumoperitonium



The patient was shifted for laparotomy findings were pneumoperitonium and sealed gastric perforation in the anterior wall of prepyloric region of stomach (Figure.3), which was closed with

reinforcing stitches. Patient improved, passed stools, started on oral feeds and skin sutures were removed on 10<sup>th</sup> post operative day, but the patient expired on the 11<sup>th</sup> post operative day due to bronchopneumonia.

**Figure 3:** Intra-operative picture - Arrow showing sealed gastric perforation



### **DISCUSSION**

In this case, cause of suspected gastric perforation was hypoxia induced by aspiration pneumonia and gastric ulcer disease, because of episode of melena in the hospital followed by abdominal distension. H<sub>2</sub> receptor blockers or Proton Pump Inhibitors (PPI's) might have been used in this NPO case after the episode of melena, H<sub>2</sub> receptor blocker was initiated post operatively. Other accompanying cofactors influencing gastric perforation in this case were sepsis in the form of multiple scalp abscess, Pneumonia and aerophagy due to respiratory distress.

Iatrogenic gastric perforation may be ruled out because of nasogastric tube was inserted after the abdominal distension and appearance of perforation was not showing fresh mucosa which was confirmed during laparotomy.

High mortality due to gastrointestinal perforation was associated with overwhelming sepsis, immaturity of systems, immune depression and multiorgan failure. Mortality rate was high among the infants compared to older children<sup>[1,9]</sup>. Histopathologically chronic inflammatory changes and ischemia

were noted in studies. Pathogenesis implicated for perforation is ischemia and hypoxia. Time between the onset of symptom to intervention plays a main roll in the survival [3,20,21].

With the onset of signs of stress induced Peptic ulcer disease can be handled with prophylactic H2 blocker or PPI's, which can reduce gastric secretion and further erosion [13-16]. Treatment for gastric perforation is primarily surgery by gastrorhaphy and drainage, with poor general condition of the patient, flank drain or conservative management also reported with success [2,7,18,19].

Intensive care unit physician should have suspicion of gastric perforation, in infants with gastric distension and pneumoperitoneum, particularly with hypoxic and ischemic conditions to improve outcome of the gastric perforation cases.

### **CONCLUSION**

Although a rare but very high mortality condition, high suspicion of gastric or intestinal perforation is necessary for early identification and intensive treatment of the same for favorable outcome.

---

### **REFERENCES**

- 1) Grosfeld JL, Molinari F, Chaet M, Engum SA, West KW, Rescorla FJ, Scherer LR 3rd. Gastrointestinal perforation and peritonitis in infants and children: experience with 179 cases over ten years. *Surgery*. 1996 Oct;120(4):650-5; discussion 655-6.
- 2) Ghribi A, Krichene I, Fekih Hassen A, Mekki M, Belghith M, Nouri A. Gastric perforation in the newborn. *Tunis Med*. 2013 Jul;91(7):464-7.
- 3) Oztürk H, Onen A, Otçu S, Dokucu AI, Gedik S. Gastric perforation in neonates: analysis of five cases. *Acta Gastroenterol Belg*. 2003 Oct-Dec;66(4):271-3.
- 4) Duran R, Inan M, Vatansever U, Aladağ N, Acunaş B. Etiology of neonatal gastric perforations: review of 10 years' experience. *Pediatr Int*. 2007 Oct;49(5):626-30.
- 5) Qin H1, Yao H, Zhang J. Gastric rupture caused by acute gastric distention in non-neonatal children: clinical analysis of 3 cases.

- 6) Mishima T, Kohara N, Tajima Y, Maeda J, Inoue K, Ohno T, Kitasato A, Watanabe T, Irie J, Adachi T, Kuroki T, Eguchi S, Kanematsu T. Gastric rupture with necrosis following acute gastric dilatation: report of a case. [Surg Today](#). 2012 Oct;42(10):997-1000. doi: 10.1007/s00595-012-0162-4. Epub 2012 Mar 13.
- 7) Kara CS, İlçe Z, Celayir S, Sarimurat N, Erdogan E, Yeker D. Neonatal gastric perforation: review of 23 years' experience. [Surg Today](#). 2004;34(3):243-5.
- 8) Leone RJ Jr, Krasna IH. 'Spontaneous' neonatal gastric perforation: is it really spontaneous? [J Pediatr Surg](#). 2000 Jul;35(7):1066-9.
- 9) Kuremu RT, Hadley GP, Wiersma R. Neonatal gastric perforation. [East Afr Med J](#). 2004 Jan;81(1):56-8.
- 10) Tan CE, Kiely EM, Agrawal M, Brereton RJ, Spitz L. Neonatal gastrointestinal perforation. [J Pediatr Surg](#). 1989 Sep;24(9):888-92.
- 11) Hutchinson GH, Alderson DM, Turnberg LA. Fatal tension pneumoperitoneum due to aerophagy. [Postgrad Med J](#). 1980 Jul;56(657):516-8.
- 12) Offerman SR, Holmes JF, Wisner DH. Gastric rupture and massive pneumoperitoneum after bystander cardiopulmonary resuscitation. [J Emerg Med](#). 2001 Aug;21(2):137-9.
- 13) Edwards MJ, Kollenberg SJ, Brandt ML, Wesson DE, Nuchtern JG, Minifee PK, Cass DL. Surgery for peptic ulcer disease in children in the post-histamine2-blocker era. [J Pediatr Surg](#). 2005 May;40(5):850-4.
- 14) Ward RM, Kearns GL. Proton pump inhibitors in pediatrics : mechanism of action, pharmacokinetics, pharmacogenetics, and pharmacodynamics. [Paediatr Drugs](#). 2013 Apr;15(2):119-31. doi: 10.1007/s40272-013-0012-x.
- 15) Rosen R. Gastroesophageal reflux in infants: more than just a phenomenon. [JAMA Pediatr](#). 2014 Jan;168(1):83-9. doi: 10.1001/jamapediatrics.2013.2911.
- 16) López-Alonso M, Moya MJ, Cabo JA, Ribas J, del Carmen Macías M, Silny J, Sifrim D. Twenty-four-hour esophageal impedance-pH monitoring in healthy preterm neonates: rate and characteristics of acid, weakly acidic, and weakly alkaline gastroesophageal reflux. [Pediatrics](#). 2006 Aug;118(2):e299-308. Epub 2006 Jul 10.
- 17) Gudmundsson G. Infantile colic: is a pain syndrome. [Med Hypotheses](#). 2010 Dec;75(6):528-9. doi:

10.1016/j.mehy.2010.07.014. Epub  
2010 Aug 21.

18) Aydın M, Zenciroğlu A, Hakan N,  
Erdoğan D, Okumuş N, Ipek MS.  
Gastric perforation in an extremely low  
birth weight infant recovered with  
percutaneous peritoneal drainage. *Turk  
J Pediatr.* 2011 Jul-Aug;53(4):467-70.

19) Zerella JT, McCullough JY.  
Pneumoperitoneum in infants without  
gastrointestinal perforation. *Surgery.*  
1981 Feb;89(2):163-7.

20) Byun J, Kim HY, Noh SY, Kim  
SH, Jung SE, Lee SC, Park KW.  
Neonatal gastric perforation: A single  
center experience. *World J Gastrointest  
Surg.* 2014 Aug 27;6(8):151-5. doi:  
10.4240/wjgs.v6.i8.151.

21) Srivastava UK, Singh DP, Gupta  
A, Jagdeep. A Report of Two Cases of  
Gastric Perforation in Neonates. *J  
Indian Assoc Pediatr Surg.* 2004 Jan-  
Mar: Vol 9: 35-38.