

Heryln - Werner - Wunderlich Syndrome associated with Rectovesical fistula and Neural tube defect: A Rare Presentation

Anjali Verma¹, Geeta Gathwala², Poonam Mehta³, Manoj Yadav⁴, Ravi Yadav⁵, Sandeep Taparia⁶

ABSTRACT

Herlyn – Werner – Wunderlich syndrome (HWWS) is an uncommon combined Mullerian and Mesonephric duct anomaly, and its presentation in neonatal period is even rarer. Symptoms generally occur after menarche about 12 to 13 years old and it is usually diagnosed by pelvic magnetic resonance imaging. Our case is 1 day old asymptomatic newborn with all the features of this syndrome that came to our attention during diagnostic workup of rectovesical fistula and meningomyelocele. The aim of this article is to share our experience of coincidental association of this syndrome along with other malformations and focus the attention on the importance of high level of suspicion of HWWS in neonatal period which leads to early diagnosis and treatment.

Keywords: Herlyn – Werner – Wunderlich syndrome, meningomyelocele, newborn, renal agenesis

¹Senior resident, ²Head of Department, ³Assistant Professor, ^{4,5,6}Junior resident
Department of Pediatrics, PGIMS, Rohtak, Haryana, India

Corresponding author mail: dranjali604@gmail.com

Conflict of interest: No conflict of interest

INTRODUCTION

The Wolffian (mesonephric) ducts and the Mullerian (paramesonephric) ducts are the two paired urogenital structures from which the internal genital organs and the lower urinary tract derive. Herlyn – Werner – Wunderlich (HWW) syndrome is one of the rare anomaly of urogenital tract which is characterised by the triad of uterus

didelphys, obstructed hemivagina and ipsilateral renal agenesis.^[1,2]

Association of renal anomalies with mullerian defects is known whereas incidence of rectovesical fistula is not mentioned in literature as per our knowledge. In addition, little is reported about spinal malformations associated with this syndrome.

Here, we are reporting a case of 1 day neonate with HWW syndrome which is associated with rectovesical fistula and meningomyelocele which have never been seen earlier in literature.

CASE REPORT

A full term female newborn with birth weight 2.4 kg, who was delivered vaginally at a tertiary care hospital, was detected to have imperforate anus and sacral swelling during routine examination by paediatrician attending delivery. Baby cried immediately at birth and was asymptomatic. Patient was passing meconium through urethral opening thus indicating some communication between urinary and

gastrointestinal system. Mother was 22 years old, primigravida had uneventful antenatal period. There was no history of any drug intake and radiation exposure during the pregnancy.

On clinical examination, there was no anal opening and a hypertrophied clitoris with prominent hooded appearance was present. A swelling of 3 cm diameter was also present in lumbosacral region. Patient was moving lower limbs and there was no urinary incontinence. There was neither facial dysmorphism nor any limb deformities were present. Patient was normally feeding and was passing urine and stool through a single opening.

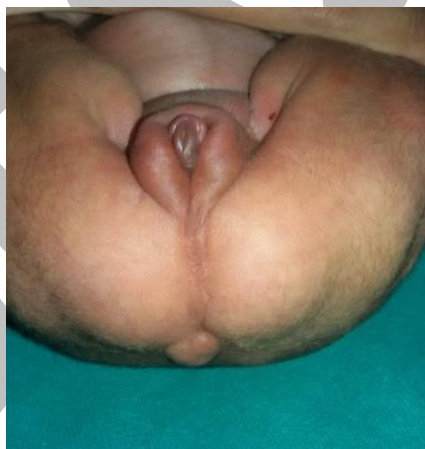

Figure 1: Newborn showing imperforate anus and sacral swelling

In view of some congenital malformations, all investigations to look for other malformations were done. Ultrasonography

of abdomen and pelvis showed absence of right kidney in renal fossa with uterine didelphus where as ultrasound of skull came

out to be normal. For better lineation, we further investigated with MR pelvis which revealed that there were two uterine bodies, two cervixes and two vagina. Right hemivagina is distended with fluid suggestive of presence of distal transverse septum. There was small fluid collection in left uterine cavity due to slight compression

of left hemivagina by distended right hemivagina. Also, there was agenesis of right kidney. There was presence of gas in urinary bladder thus indirectly indicating the presence of rectovesical fistula. Fistulogram could not be done as attendants did not give consent for invasive procedure.

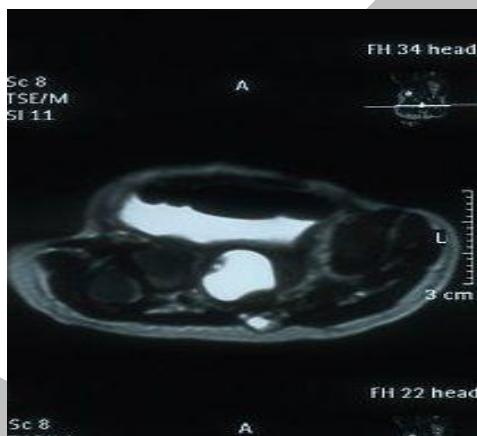


Figure 2: Axial T2 weighted image showing two separate uterine cavities, two separate cervixes and dilatation of right hemivagina. Also, there is presence gas in urinary bladder indicating rectovesical fistula

In addition, sacral canal was opened posteriorly (spina bifida) through which thecal sac was protruding out. Few neural elements also appeared to be protruding out along with thecal sac (meningomyelocele).

Spinal cord was low lying i.e. reaching upto S3 and tethered. Other routine hematological and biochemical investigations were normal. Chest radiograph and echocardiography were normal.

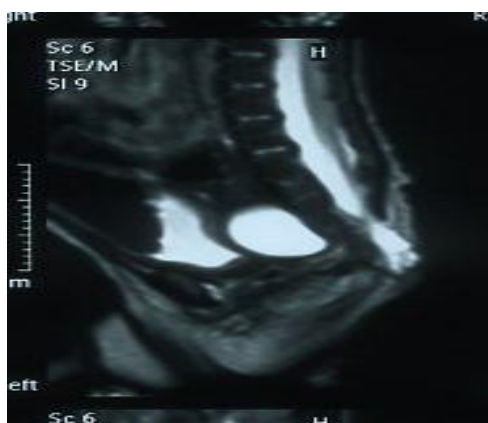

Figure 3: Saggital T2 W MRI showing meningocele with tethering of cord

DISCUSSION

In 1971, the association of renal agenesis with ipsilateral blind hemivagina was reported as Herlyn- Werner syndrome [3], where as the association of renal agenesis, bicornuate uterus with isolated hematocervix, and a simple vagina was reported by Wunderlich in 1976. [4] HWWS constitutes 0.16-10% of all Mullerian duct abnormalities. The incidence of HWWS has been estimated to be 1 in 20,000 females. Only six cases are reported in literature with early onset of this syndrome under 5 years of age. [5-10]

This syndrome is a rare variant within the spectrum of mullerian duct anomalies. The most basic classification of mullerian ductal defects consists of (a) agenesis and hypoplasia, (b) defects of vertical fusion, and (c) defects of lateral fusion. Indeed, HWWS may represent a

failure of vertical and lateral fusion of mullerian structures. The actual incidence of mullerian anomalies is unknown.

HWWS patients most commonly present at puberty, a few years after menarche, although it can present in adulthood as primary infertility and has also been reported in a neonate, presenting as a mass prolapsing per vaginum. Patients with HWWS are usually asymptomatic until menarche when they present a hydrometrocolpos on the side of obstructed hemivagina producing a mass effect and pain. [11-12]

The cases reported in newborns are accidental due to prenatal and postnatal detection of renal anomalies. However, the diagnosis of HWWS may be delayed by several months because menstruation is often normal. If this syndrome is suspected, the diagnosis is simply and it can be made

by ultrasound and computed tomography and/or MRI of the abdomen and pelvis^[13]. Resection of the vaginal septum is the treatment of choice for obstructive hemivagina.^[11]

The exact etiology, pathogenesis, and embryologic origin of HWW syndrome are still not known. Embryologically, Wolffian ducts play an important role in the development of internal genital organs and kidneys. Incomplete or absent fusion of hemiuteri at eighth week of gestation results in the formation of 2 hemiuteri.

The female reproductive tract develops at the same time and close to the urinary tract and kidneys from the development of two pairs of Wolffian ducts (mesonephric duct) and Mullerian ducts (paramesonephric duct). The classic renal manifestation of this syndrome is ipsilateral renal agenesis, but reports of duplicated kidneys, dysplastic kidneys, rectovesical bands or crossed fused ectopia have also been described.^[8] In our case we found association of this syndrome with rectovesical fistula and imperforate anus which was not seen earlier.

Similarly, few cases of spinal malformations with HWWS has been seen, mainly association of congenital scoliosis

has been reported.^[14] Here we found presence of neural tube defect in form of meningomyelocele along with HWWS although its etiology is not very clear. The prevalence of congenital scoliosis among patients with HWWS was 8.57%,^[14] much higher than the incidence of congenital scoliosis among general population (1/1000) but incidence of neural tube defects is not known. Both genetic variant and environment factors during pregnancy might play roles in the potential mechanisms in the pathogenesis of spinal malformations of HWWS. As the number of cases increases, the etiology, clinical manifestation and the natural history of the syndrome will become clearer.

CONCLUSION

The main aim of this report is focussing the attention on the possible early presentation of this syndrome that should be suspected in all neonates (females) with renal malformations such as renal agenesis, meningomyelocele and rectovesical fistula confirmed post-natal or suspected prenatal. Sometimes correct diagnosis can be difficult due to absence of specific findings on physical examination and non specific symptoms which delays the diagnosis. MRI is however the best imaging modality to

diagnose the syndrome. It could be desirable to achieve to an early diagnosis and treatment of HWW syndrome in order to relieve symptoms, preserve normal fertility and prevent several medical complications.

REFERENCES

1. Karaca L., Pirimoglu B., Bayraktutan U., Ogul H., Oral A., Kantarci M. Herlyn–Werner–Wunderlich syndrome a very rare urogenital anomaly in a teenage girl. *J. Emerg. Med.* 2014;(December (8)) pii: S0736-4679(14) 1108-1.
2. Van Leerdam L.E., Beerendonk C.C., Klein W.M., Sir O. Herlyn–Werner–Wunderlich syndrome. *Nederlands Tijdschrift Voor Geneeskunde.* 2014;158(December):A78 86. Dutch.
3. Herlyn U., Werner H. Simultaneous occurrence of an open Gartner-duct cyst: a homolateral aplasia of the kidney and a double uterus as a typical syndrome of abnormalities. *Geburtshilfe Frauenheilkd.* 1971;31:340–347.
4. Wunderlich M. Unusual form of genital malformation with aplasia of the right kidney. *Zentralbl Gynakol.* 1976;98:559–562.
5. Pansini L. Acute urinary retention due to didelphys uterus associated with an obstructed hemivagina in a 5-month-old infant. *J. Pediatr. Surg.* 1988;23:984–985.
6. Roth M., Mingin G., Dharamsi N., Psooy K., Koyle M. Endoscopic ablation of longitudinal vaginal septa in prepubertal girls a minimally invasive alternative to open resection. *J. Pediatr. Urol.* 2010;6(October (5)):464–468.
7. Sanghvi Y., Shastri P., Mane S.B., Dhende N.P. Prepubertal presentation of Herlyn–Werner–Wunderlich syndrome a case report. *J. Pediatr. Surg.* 2011;46(June (6)):1277–1280.
8. Vivier P.H., Liard A., Beurdeley M., Brasseur-Daudruy M., Cellier C., Le Dosseur P., Dacher J.N. Uterus didelphys hemihydrocolpos and empty ipsilateral lumbar fossa in a newborn girl: involuted dysplastic kidney rather than renal agenesis. *Pediatr. Radiol.* 2011;41(September (9)):1205–1207.
9. Wu T.H., Wu T.T., Ng Y.Y., Ng S.C., Su P.H., Chen J.Y., Chen S.J. Herlyn–Werner–Wunderlich syndrome consisting of uterine didelphys, obstructed hemivagina and ipsilateral renal agenesis

- in a newborn. *Pediatr. Neonatol.* 2012;53(February (1)):68–71. Epub 2012 January 24.
10. Han B.H., Park S.B., Lee Y.J., Lee K.S., Lee Y.K. Uterus didelphys with blind hemivagina and ipsilateral renal agenesis (Herlyn–Werner–Wunderlich syndrome) suspected on the presence of hydrocolpos on prenatal sonography. *J. Clin. Ultrasound.* 2013;41(July–August (6)):380–382.
11. Yavuz A., Bora A., Kurdoğlu M., Goya C., Kurdoğlu Z., Beyazal M., Akdemir Z.J. Herlyn–Werner–Wunderlich syndrome merits of sonographic and magnetic resonance imaging for accurate diagnosis and patient management in 13 cases. *Pediatr. Adolesc. Gynecol.* 2014
12. Wang J., Zhu L., Lang J., Liu Z., Sun D., Leng J., Fan Q. Clinical characteristics and treatment of Herlyn–Werner–Wunderlich syndrome. *Arch. Gynecol. Obstet.* 2014;290(November (5)):947–950.
13. Tanaka Y.O., Kurosaki Y., Kobayashi T. Uterus didelphys associated with obstructed hemivagina and ipsilateral renal agenesis: MR findings in seven cases. *Abdom. Imaging.* 1998;23:437–441.
14. Li Zheng MD; Yu Xin MD; Shen Jianxiong MD; Liang Jinqian MD. Scoliosis in Herlyn–Werner–Wunderlich Syndrome: A Case Report and Literature Review. *Medicine (Baltimore).* 2014 Dec;93(28):e185.