

## Adult Neuroblastoma of Adrenal gland: Two case report

Bhatt Krutika R<sup>1</sup>, Trivedi Priti P<sup>2</sup>, Shah Manoj J<sup>3</sup>

### **ABSTRACT**

**Introduction:** Neuroblastoma of the adrenal gland is an extremely rare tumor in adulthood although it is one of the most common malignancies in childhood. The median age of onset is 2 years, with more than 95% of patients younger than 10 years at diagnosis. Considering the location of primary neuroblastoma and the fact that in some instances convincing documentation to support a diagnosis is lacking, these tumors can be diagnosed as other small, round-cell tumors, such as primitive neuroectodermal tumor (PNET)/Ewing's sarcoma (ES) and olfactory neuroblastoma. Case Reports: Here we present 2 cases of adult neuroblastoma in 23 and 27 years old male patients diagnosed in stage III and IV respectively. Both these patients showed poor outcome. **Conclusion:** Adults with neuroblastoma have significantly worse outcome than children. This may be due to tumor biology, more virulent clinical course, or possibly due to the fact that adults are less sensitivity or have poor tolerance to pediatric chemotherapy regimens.

**Key Words:** adrenal gland, Adult neuroblastoma, Ewing's sarcoma

<sup>1</sup>Resident, <sup>2</sup>Professor, <sup>3</sup> Professor and Head of Department

Department of Pathology, Gujarat Cancer and Research Institute, Ahmedabad, Gujarat, India

Corresponding author mail: [dr.krutika25@gmail.com](mailto:dr.krutika25@gmail.com)

Conflict of interest: None

### **INTRODUCTION**

Neuroblastoma is the most common extracranial solid tumor in children and accounts for about 8% of cancers in patients under 15 years of age.<sup>1</sup> It is almost exclusively a pediatric neoplasm: the median age at onset is 2 years, and more than 95% of patients are less than 10 years old at diagnosis. It is rare in adolescents and even more so in adults ( $\geq 20$  years) with no more than 65 cases reported in review of literature till date.<sup>2</sup> Age at which it is diagnosed has important prognostic importance with best prognosis in infants

under 1 year of age and carrying worse prognosis in adults.<sup>3,4,5,6</sup>

The locations of primary neuroblastomas in adults are similar to the locations in younger patients, with the abdomen and pelvis being the most common areas of occurrence, followed by thorax, head or neck, and extremities. Neuroblastoma of the adrenal gland is extremely rare disorder and only 25% of the neuroblastoma cases arise from adrenal glands, although abdomen is the most common site of origin (75%) in adulthood.<sup>6</sup> In addition, because of the rarity of adult adrenal neuroblastoma,

little is known about its clinicopathological, imaging, histologic and immunohistochemical features.<sup>7</sup>

Herein we have presented two cases of adult males who were diagnosed with advanced staged adrenal Neuroblastoma.

### **CASE REPORT 1:**

A 23 year old male presented with pain in right flank, hypochondriac region and upper back with history of weight loss since 2 years. Complete physical examination and routine investigations were within normal limits. 24-hour urine vanillylmandelic acid level (VMA) was slightly elevated (16 mg/24 hours, normal range is between 2-10 mg/24 hours)). Ultrasonography (USG) of abdomen revealed a retroperitoneal mass measuring 13.0 x 10.0 x 15.0 cms in right suprarenal region reaching upto midline, displacing right kidney anteriorly.

Computed tomography scan (CT) of abdomen revealed a large hypodense solid mass in right suprarenal, paraspinal and prevertebral region, displacing inferior vena cava (IVC) anteriorly and right kidney laterally, crossing midline and displacing head of pancreas anteriorly. Superiorly mass extended up to inferior surface of right lobe of liver and showed loss of plane of fat with

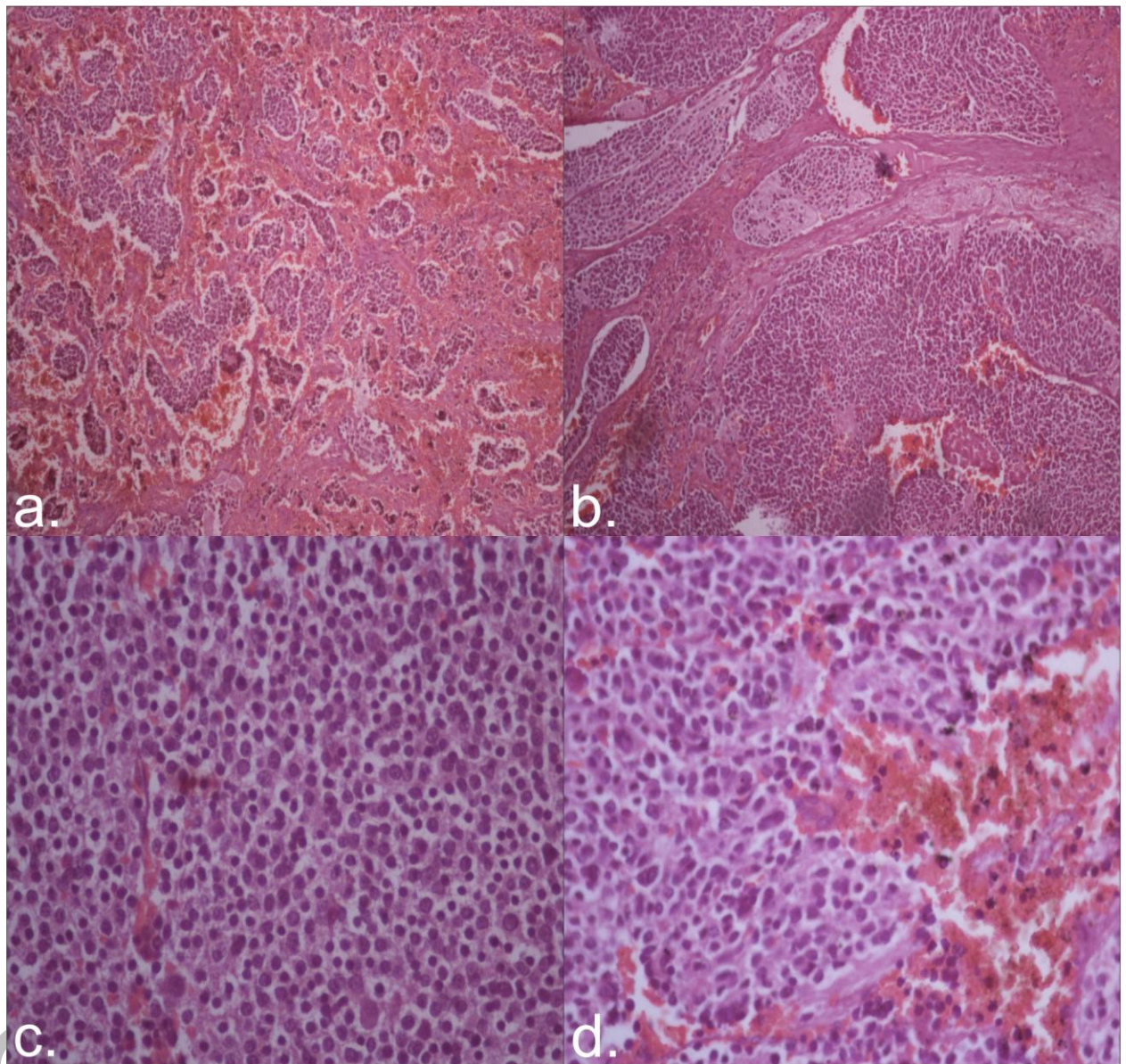
it and mass compressed IVC and right upper ureter.

USG guided Fine Needle Aspiration (FNA) and biopsy were done and reported as Neuroblastoma with postivity for neuron specific enolase (NSE) and negativity for neurofilament (NF) and CD99 on Immunohistochemistry(IHC).

Bone marrow biopsy showed marrow uninvolved by tumor.

On exploratory laparotomy, mass was found in right suprarenal region, completely plastered in retroperitoneum, infiltrating liver and encasing IVC and aorta upto the level of common iliac vessels. So patient was declared inoperable and three nodules were excised from mass and sent for histopathology report. Grossly three nodules were of 2.0, 2.8 and 3.5 centimeters in maximum diameter with grey white solid cut surface.

Morphology showed sheets of small round, blue cells with hyperchromatic irregular nuclei and scant amount of cytoplasm in background of light pink fibrillary neuropil. Ganglionic cells were also evident(less than 5%) with focal areas of necrosis and were reported as poorly differentiated Neuroblastoma (stroma poor) [Figure-1]



**Figure 1:** a & b. -- Low power view (10x) show sheets of small round blue cells in background of light pink fibrillary neuropil with hemorrhage and necrosis  
c. & d. -- Sheet of small round, blue cells with hyperchromatic irregular nuclei and scant amount of cytoplasm

IHC showed positivity for NSE and Synaptophysin and negativity for vimentin, CD99 and AE1.

MIB 1 showed proliferative index of 70-80%. (Figure 2)

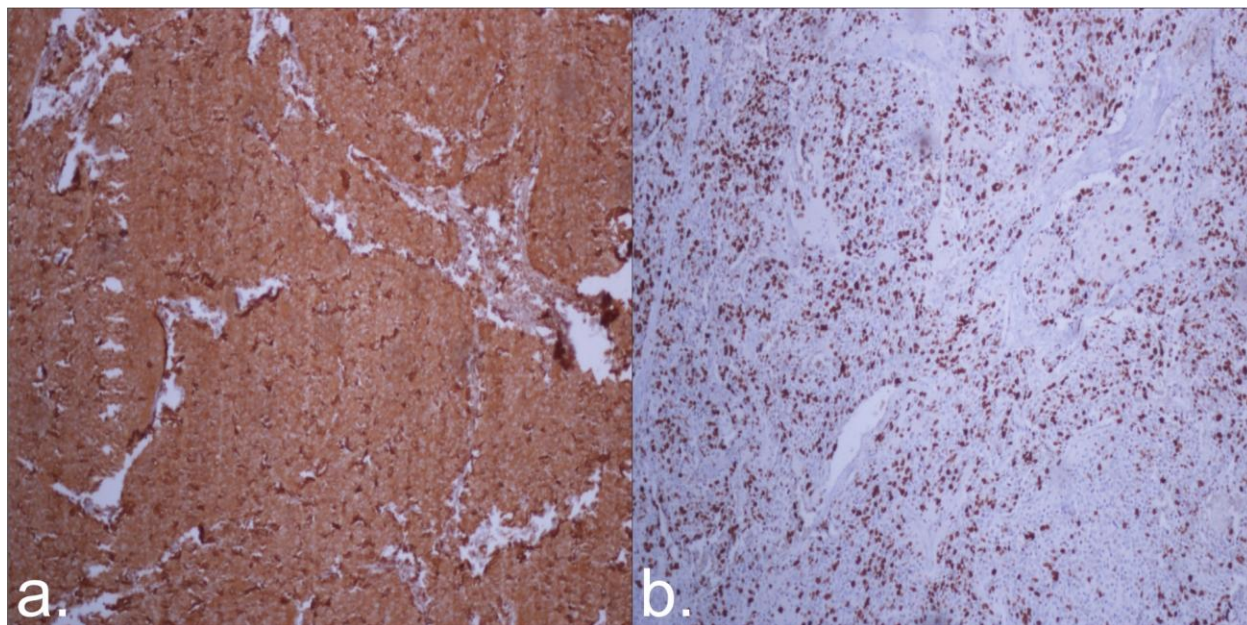


Figure 2: a) NSE positive b) MIB 1

The disease was graded as stage III (unresectable tumor with or without regional LN metastasis) using the international neuroblastoma staging system (INSS).

Patient was planned for palliative chemotherapy as per DOG 9341 regimen, followed by surgery and/or radiotherapy after reassessment. But patient didn't come for further treatment and was lost to follow up.

### **CASE REPORT 2**

A 27 year male presented with right hypochondriac region pain and enlargement of abdomen since 1.5 year. Physical

examination revealed abdominal lump in right lumbar region with enlarged right supraclavicular LNs. 24 hour urine VMA level was elevated (25 mg/24 hours). Routine laboratory investigations were within normal limits.

CT scan abdomen revealed mass in right hypochondrium involving right suprarenal, upper pole of right kidney, and right lobe of liver, crossing midline and encasing aorta, Intrahepatic portion of IVC and portal vein and displacing pancreas anteriorly. Mild pleural effusion noted in right side.

(Figure3)

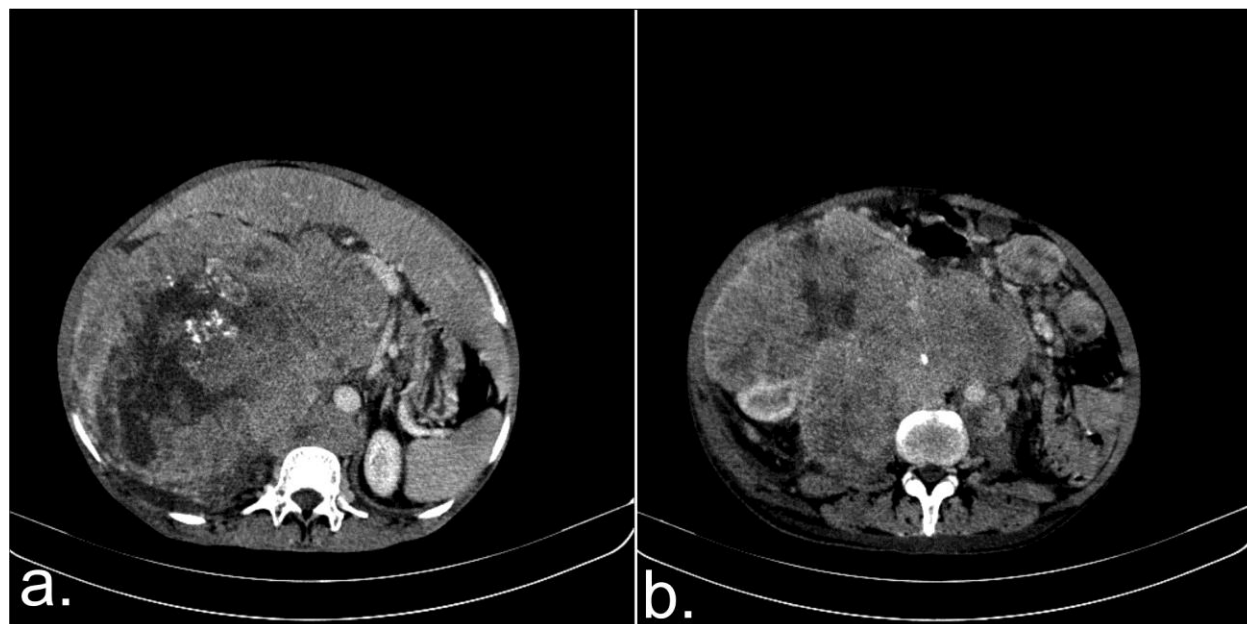


Figure 3: a & b- mass in right hypochondrium involving right suprarenal, upper pole of right kidney, and right lobe of liver, crossing midline and encasing aorta with microcalcification

USG guided FNAC and Biopsy were done which morphologically showed small round, blue cells with hyperchromatic irregular nuclei and scant amount of cytoplasm in background of light pink fibrillary neuropil. IHC showed positivity for NSE and Synaptophysin and negativity for vimentin, CD99 and AE1. MIB 1 showed proliferative index of 80-85%.

Disease was graded as stage IV (unresectable tumor involving liver, crossing midline and metastasising to distant LNs) using the INSS.

Patient was given palliative chemotherapy as per OPEC regimen

protocols which consisted of Sequence of slow intravenous vincristine 1.5mg/m<sup>2</sup> on day 1, cisplatin 60mg/m<sup>2</sup> on day 2, and etoposide 150mg/m<sup>2</sup> on day 4 for 2 cycles at interval of 3 weeks. On response evaluation follow up repeat CT scan abdomen was done after 2 months, which revealed enlargement of previously existing mass with internal necrosis and calcification with multiple heterogeneously enhancing soft tissue density lesions in anterior mediastinum, pre and para tracheal regions, omentum, mesentery, both lobes of liver and mid para-aortic region. It suggested

metastasis from the primary tumour. Patient died six months post diagnosis.

### **DISCUSSION**

Adrenal neuroblastoma is rare in adults and adolescents. When present in adults they are associated with aggressive to indolent course and worse prognosis; with ultimate survival being less than 5%.<sup>6,8</sup> Neuroblastomas commonly arise from the adrenal medulla but may arise from sympathetic ganglia at any site. Common sites of origin in adults include the abdomen, pelvis, mediastinum, thoracic spine, and the olfactory region.<sup>9</sup>

Very little is known about its clinicopathological features and imaging findings. In addition many a times due to lack of convincing documentation it is misdiagnosed as small round cell tumors, PNET/ES or olfactory neuroblastoma.<sup>10</sup>

Treatment of adult neuroblastoma includes surgery with adjuvant chemotherapy with or without radiotherapy. Our both cases presented as advanced disease in stage III and IV and were declared inoperable. Case 1 was lost to follow up. While case 2 showed aggressive course on subsequent evaluation after chemotherapy with increasing in size of tumor on CT scan

and worsening condition. Patient died six months post diagnosis.

### **CONCLUSION**

On concluding, adrenal neuroblastoma in adulthood is very rare but should be considered in the differential diagnosis of atypical adrenal masses. CT scan and histopathology report with aid of IHC are very useful in diagnosis and in assessment of resectability of this tumor. Nevertheless, both the cases were diagnosed in advanced stage and prognosis was poor in these cases

### **REFERENCES**

1. Gurney JG, Ross JA, Wall DA, Bleyer WA, Severson RK, Robison LL. Infant cancer in the US histology-specific incidence and trends, 1973 to 1992. *J Pediatr Hematol Oncol* 1997;19:428-32
2. Panovska-Stavridis I, Ivanovski M, Hadzi-Pecova L, Ljatic A, Trajkov D, Spiroski M, et al. A case report of aggressive adult neuroblastoma mimicking acute leukemia with fulminant course and fatal outcome. *Prilozi* 2010;31:349-59.
3. Evans AE, D'Angio GJ. Age at diagnosis and prognosis in children with neuroblastoma. *J Clin Oncol* 2005;23:6443-44.

4. Coldman AJ, Fryer CJH, Elwood JM, SonleyMJ. Neuroblastoma influence of age at diagnosis, stage, tumor site, and sex on prognosis. *Cancer* 1980;46:1896-1901.
5. Gaspar N, Hartmann O, Munzer C, Bergeron C, Millot F, Cousin-Lafay L, et al. Neuroblastoma in adolescents. *Cancer* 2003;98:349-55.
6. Franks L, Bollen A, Seeger RC, StramDO,Matthay KK. Neuroblastoma in adults and adolescents an indolent course with poor survival. *Cancer* 1997;79:2028-35.
7. Hasegawa T, Hirose T, Ayala A, Ito S, Tomaru U, Matsuno Y, et al. Adult neuroblastoma of the retroperitoneum and abdomen clinicopathologic distinction from primitive neuroectodermal tumor. *The Am J Surg Pathol* 2001;25(7):918-24.
8. Esiashvili N, Goodman M, Ward K, Marcus R, Johnstone A. Neuroblastoma in adults Incidence and survival analysis based on SEER data. *Peditr Blood Cancer* 2007;49:41-46.
9. Franks L, Bollen A, Seeger RC, StramDO,Matthay KK. Neuroblastoma in adults and adolescents an indolent course with poor survival. *Cancer* 1997;79:2028-35.
10. Hasegawa T, Hirose T, Ayala A, Ito S, Tomaru U, Matsuno Y, et al. Adult neuroblastoma of the retroperitoneum and abdomen clinicopathologic distinction from primitive neuroectodermal tumor. *The Am J Surg Pathol* 2001;25(7):918-24.