
**Acute primary Psoas abscess in a Hepatitis B positive child presenting as hip
Pathology- A rare case report**

Ganesh Singh Dharmshaktu,¹ Irfan Khan,² Shailendra Singh Bhandari³

ABSTRACT

Hip pain and related complaints have many differentials but psoas abscess as cause of it is not common phenomenon. Furthermore, such settings can further delay the diagnosis by diversion. Good clinical acumen and appropriate use of modern imaging modalities is instrumental to diagnose it early for better management. The presented case highlights importance of looking ‘beyond hips’ and ascertain the diagnosis in doubtful cases with advance imaging techniques. The case is unreported account of primary psoas abscess presenting acutely as a hip case in a hepatitis B positive child. Early drainage of pus is cornerstone of prompt recovery with good predicted outcome.

Key Words: Hepatitis B, Hip, Psoas Abscess, Infection

¹Assistant Professor, ²Senior Resident, ³Associate Professor

Department of Orthopaedics, Government Medical College Haldwani, Uttarakhand.

Corresponding author mail: drganeshortho@gmail.com.

Conflict of interest: None

INTRODUCTION

Mynter described pus in the psoas muscle as ‘psoitis’.¹ The condition can be primary or secondary on basis of associated lesions present. Clinically psoas abscess presents with very non specific clinical features often leading to delayed diagnosis and poor prognosis.² Groin or hip pain with or without localized swelling can be a pointer to probable hip pathology requiring appropriate investigations and treatment. A knowledge of possible mimics of similar

conditions helps in ruling out other pathologies with relevant methods.

CASE REPORT

A seven year old child presented to us with pain in the right lower limb and difficulty in bearing weight since last three days. There was no history of any trauma to the region or previous similar or related event. Clinical examination was unremarkable except a flexion deformity of the hip and difficulty to examine for other findings because of pain. There was

tenderness at and around the anterior hip and groin region. There was no local rise of temperature corresponding to the abovementioned sites although there was mild fever since last night which got transiently relieved by certain medication provided by a local practitioner.

A provisional diagnosis of transient synovitis was made and patient admitted for

the rest and supportive, symptomatic treatment. The child was put on bed rest and pain relieving medications. Skin traction on the affected extremity was placed with one brick of weight with appropriate counter-traction in view of the flexion deformity correction. Traction was also intended to relieve muscle spasm and pain. (Figure1)

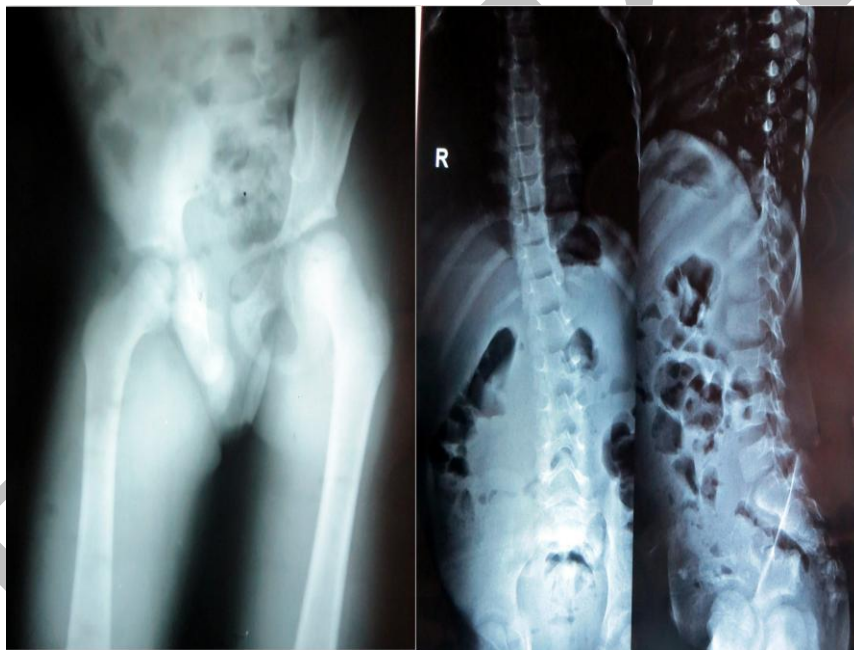

Figure 1: Skiagram showing hip flexion deformity and unremarkable spine abnormality

The patient was put on intravenous empirical broad spectrum antibiotics after negative hip aspiration under aseptic conditions. The basic blood investigations including complete and differential counts along with erythrocyte sedimentation rate (ESR) and C- reactive protein (CRP). The

child was temporarily relieved with medications with pain and fever recurring on discontinuation of treatment.

The total leukocyte count (TLC) was raised double the normal limits to 26600cells/cmm. and neutrophils

constituting 90% of it besides low haemoglobin of 7 g%. His other remarkable investigation was positivity to Hepatitis B antigen (HBsAg antigen) by ELISA card test which was confirmed by polymerase chain reaction (PCR) test. His ESR was raised to 38 mm in first hour by Wintrobe's method. Other investigations including liver and renal function tests were unremarkable. The radiographs couldn't be done properly and showed flexion deformity of right hip without any gross bony lesion. The child was transfused two units of packed red cells

as per the pediatric consult to improve the hemoglobin. The ultrasonography of the whole abdomen suggested a large right psoas collection having septations with about 750 ml. of volume while the contra-lateral psoas muscle was normal. The child underwent magnetic resonance imaging (MRI) scan and the key findings confirmed the presence of isolated right psoas collection extending into upper thigh and right postero-lateral abdominal wall. There was no evidence of vertebral focus of infection. (Figure 2, 3)

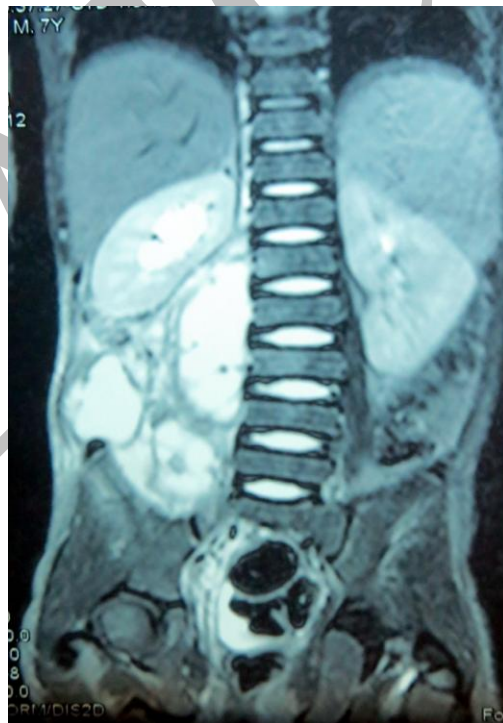


Figure 2: Transverse MRI section showing primary Psoas abscess.

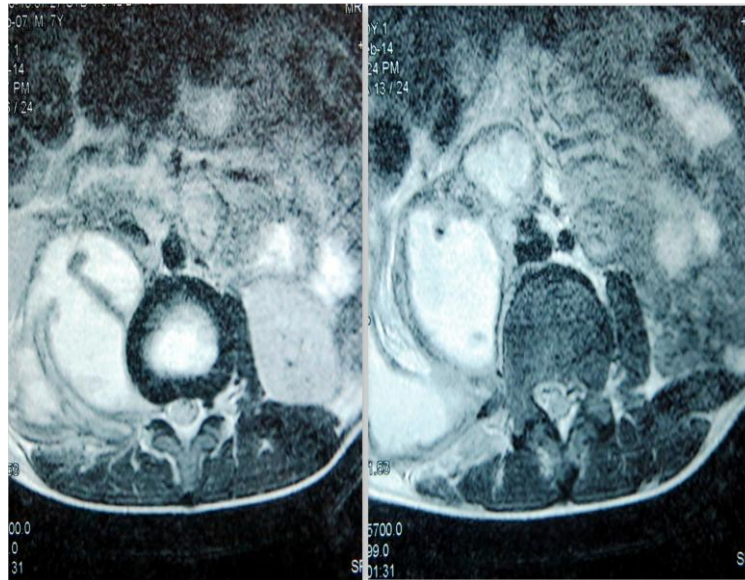


Figure 3: Coronal section showing Psoas abscess

The child was planned for surgical evacuation and drainage of collection in view of recalcitrant fever and pain to decrease bio-load and promote early recovery. The child was surgically managed under the universal precautions and aseptic conditions following informed consent of the parents .The collection was drained by lateral approach by standard techniques and there was purulent collection evacuated and sent for Gram's, Acid Fast Bacilli and fungal stain along with culture- sensitivity. The investigations were positive for *Staphylococcus aureus* infection with sensitivity to ampicillin- sulbactam and linezolid which were added into the treatment.

The child was planned for surgical evacuation and drainage of collection in view of recalcitrant fever and pain to decrease bio-load and promote early recovery. The child was surgically managed under the universal precautions and aseptic conditions following informed consent of the parents .The collection was drained by lateral approach by standard techniques and there was purulent collection evacuated and sent for Gram's, Acid Fast Bacilli and fungal stain along with culture- sensitivity. The investigations were positive for *Staphylococcus aureus* infection with sensitivity to ampicillin- sulbactam and linezolid which were added into the treatment.

RESULTS

The patient had dramatic improvement in all clinical profile after the surgery with blood investigation including ESR supporting it. The child was relieved of the fever and pain in the following couple of days and there was no fresh complaint in later course of

treatment. The flexion deformity was relieved on post operative radiographic evaluation.(Fig.4) The incision healed uneventful and child was pain-free and performing activities of daily living when reviewed in periodic follow up bimonthly and finally after a year.

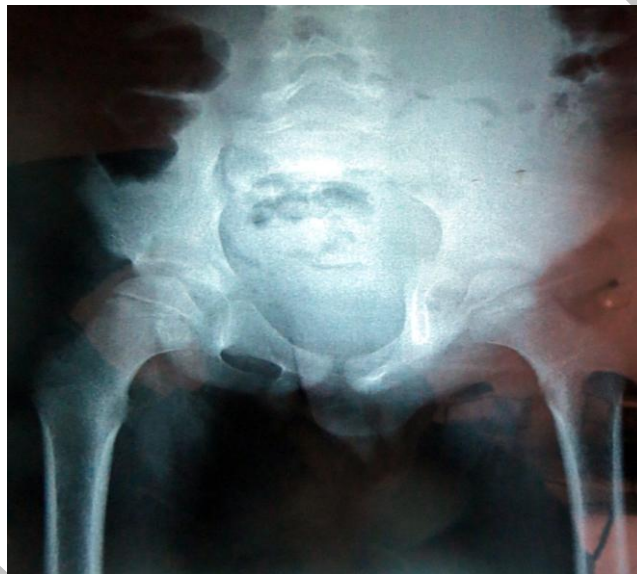

Figure 4: Corrected flexion deformity after the treatment.

DISCUSSION

Primary psoas abscess has been an uncommon variant and reported less in frequency compared to secondary ones. Haematogenous seeding or hematoma from local trauma are proposed mechanisms for developing primary abscess.³ Primary abscess have no associated gastrointestinal, genitourinary, spinal or traumatic lesion present as a causative factor.⁴ Common

presentation include fever, flank or abdominal pain.⁴ The number of more cases are being diagnosed with the advent of newer imaging modalities like computerized tomography (CT) or magnetic resonance imaging (MRI).⁵

Nonspecific clinical feature and laboratory reports may be reason for delayed diagnosis or neglect. Pain over the hip region and painful movements mimic hip

pathologies and diagnostic tests for the same thus further delaying the diagnosis.^{6,7} Newer diagnostic aid like CT or MRI are instrumental in reaching diagnosis in doubtful cases.⁸ Most common pathogenic organism associated with primary abscess is *Staphylococcus aureus* and usually single organism is the cause.⁹ Good outcome is reported with conservative or surgical drainage if the early diagnosis and antibiotic coverage is taken care of.¹⁰

The choice of open or percutaneous drainage is a matter of decision making and our team preferred open drainage of pus. Prognosis is reported good with early treatment of the condition.¹¹ Hepatitis B infection can also be a risk factor for the same. The psoas abscess has been reported in cases of immune-compromised status but not very frequently in cases with concomitant hepatitis B positivity. The presented case is a rare occurrence of primary psoas abscess in a hepatitis B positive child and has not been reported earlier as per the literature search done by authors.

REFERENCES

1. Mynter H: Acute psoitis. Buffalo Med Surg J 1881, 21:202-210.
2. Cronin CG, Lohan DG, Meehan CP, Delappe E, McLoughlin R, O'Sullivan GJ, McCarthy P: Anatomy, pathology, imaging and intervention of the iliopsoas muscle revisited. Emerg Radiol 2008, 15:295-310.
3. Isabel L, MacTaggart P, Graham A, Low B. Pyogenic psoas abscess. Aust N Z J Surg 1991; 61:857-860.
4. Hernández-Ros R, Hernández-Belmonte A. Psoas Abscess: Primary or Secondary? Indian Pediatr. 2013;50:345-6.
5. Santaella RO, Fishman EK, Lipsett PA. Primary vs secondary iliopsoas abscess. Presentation, microbiology, and treatment. Arch Surg. 1995;130(12):1309-13.
6. Penado S, Espina B, Francisco Campo J. Abscess of the psoas muscle. Description of a series of 23 cases. Enferm Infecc Microbiol Clin. 2001;19(6):257-60.
7. Bresee JS, Edwards BS, Edwards MS. Psoas abscess in children. Pediatr Infect Dis J 1990; 9:201-206.

8. Williams MP. Non-tuberculous psoas abscess. Clin Radiol 37:253–256.
9. Ricci MA, Rose FB, Meyer KK. Pyogenic psoas abscess: worldwide variations in etiology. 1986;World J Surg 10:834–843.
10. Lopez VN, Ramos JM, Meseguer V, Arellano JLP, Serrano R, Ordonez MAG et al. Microbiology and outcome of iliopsoas abscess in 124 patients. Medicine 2009, 88:120-130.
11. Baier PK, Arampatzis G, Imdahl A, Hopt UT: The iliopsoas abscess: aetiology, therapy, and outcome. Langenbecks Arch Surg 2006,391:411-417.