

Role of Advanced imaging in the Diagnosis of Sialolithiasis- A case report series

Dr. Swati Reddy¹, Dr. Swapnali Chaudhari², Dr. Shweta Saddu³, Dr. R.S. Birangane⁴

ABSTRACT

Radiographic examination is essential in diagnosing a variety of salivary gland pathologies. Plain radiography, sialography, ultrasonography, computed tomography, cone-beam computed tomography, magnetic resonance imaging, and nuclear scintigraphy/positron emission tomography all play roles in the diagnosis of salivary gland pathologies. Each of these imaging modalities has its own advantages and disadvantages. Sialolithiasis is the most common salivary gland disease. In this case series we have discussed the importance of various imaging modalities in the diagnosis of sialolithiasis with the help of five case reports. Key words: Occlusal radiograph, Orthopantomograph (OPG), computed tomography (CT), Magnetic resonance imaging (MRI), and Cone beam computed tomography (CBCT)

¹Post graduate student, ²Reader, ³Senior lecturer, ⁴Principal and Head

Department of Oral Medicine & Radiology, PDU Dental College, Kegaon, Solapur, India.

Corresponding author mail: dr.swatireddy@gmail.com

Conflict of interest: None

INTRODUCTION

Sialolithiasis, a Mealtime syndrome is the well known cause of inflammatory disease affecting major salivary glands, mainly submandibular gland.¹ These stones vary in number, sizes and shapes. They are located in the efferent duct in distal or proximal part and are rarely seen intraparenchymally.²

In sialolithiasis the variety of imaging modalities are used to know the exact location of sialolith, its dimensions, and its effect on the duct and the gland. Conventional radiography is the primary diagnostic modality. Occlusal radiograph

is indicated when sialolith of submandibular duct is suspected. However, when the salivary stones are poorly mineralized or when located in the proximal duct, they are not visualized on occlusal radiograph. Orthopantomograph (OPG) can detect the presence of sialoliths but sometimes, the sialoliths get superimposed over bone or teeth making it difficult to differentiate from intrabony lesions. Sialography can be performed for detection of radiolucent sialoliths. However, it has limitations like, invasive procedure, use of contrast media, and possible failure of the technique.³

Advanced imaging modalities have overcome most of the limitations of conventional radiography in diagnosis of sialolithiasis. In this case series we have presented five cases where different imaging modalities were used for the

CASE PRESENTATIONS

Case 1

A 25 year old female patient reported to the outpatient department with the complaint of swelling in submandibular region since 2 years. The swelling was acute & painful during meals which gradually subsided on its own in about 2 to 3 hours.

diagnosis and treatment planning of sialolithiasis. Why those imaging modalities were selected and what additional information they provided will be discussed.

On investigation, occlusal radiograph showed a radiopacity which was present within the soft tissue of the floor of mouth on left side near the lingual cortical plate in 32-34 region, oval in shape & approximately 6 X 4 mm in size (Figure 1). The radiographic diagnosis of sialolith within distal part of left submandibular duct was made.

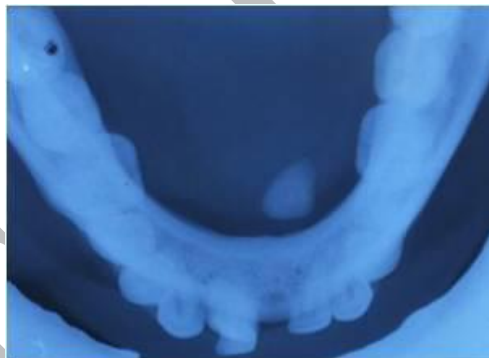

Figure1: Standard occlusal radiograph showing a well defined radio-opaque structure within soft tissue in left side.

Case 2

A similar case of 31 year old male patient reported with intermittent swelling in left submandibular region since 7 years. On radiographic investigation, occlusal radiograph did not reveal any abnormality. Panoramic radiograph showed a round

radiopacity measuring about 8mm in diameter, below the inferior alveolar nerve canal distal to 38. (Figure 2a) Computed Tomography showed a hyperdense area measuring approximately 8.7 X 6 mm, at the proximal part of the left submandibular duct. Hence the final diagnosis of left

submandibular gland duct sialolithiasis was made. (Figure 2b)

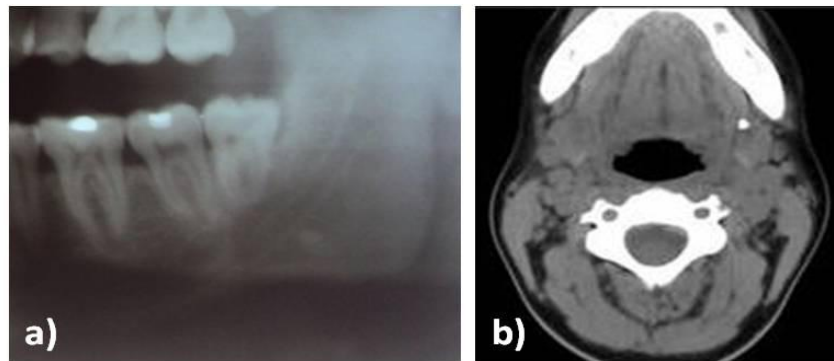


Figure 2: a) Cropped OPG showing well defined, roughly oval radiopaque structure below the inferior alveolar nerve canal distal to 38 b) CT scan showed a hyper dense area measuring approximately 8.7 X 6 mm, at the proximal part of the left submandibular duct.

CASE 3

Another case of 35 year old female patient reported a swelling in left submandibular region since 20 days.

Extraoral examination showed a well defined swelling below the lower border of mandible measuring about 4x3 cm. On Bimanual palpation, left submandibular gland was firm and tender with purulent discharge through duct opening. Left submandibular and submental lymph nodes were palpable.

Radiographic examination revealed an irregular radiopaque structure medial to 38

on occlusal radiograph.

Orthopantomograph showed a well defined, roughly oval radio opaque structure at apical area of 37, measuring approximately 10X6 mm in size. (Figure 3a)

Post contrast CT scan showed enlarged left submandibular gland with contrast enhancement and a single hyperdense area measuring approximately 1.0 X 0.7cm, in the proximal portion of the left submandibular gland duct. (Figure 3b,3c)

Hence the diagnosis of chronic sialadenitis secondary to sialolithiasis with left submandibular gland was made.

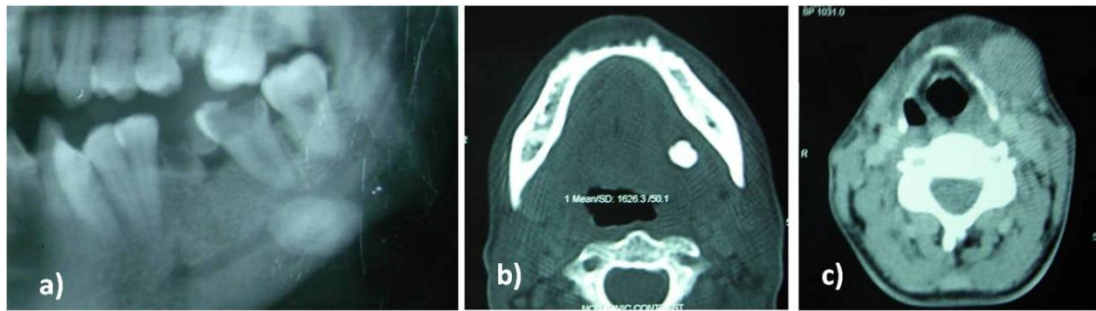


Figure 3: a) Cropped panoramic radiograph showed a well defined radiopaque structure at apical area of 37. b) CT scan showed a single hyper dense area c) CT (soft tissue window) scan showed enlarged left Submandibular gland with contrast enhancement.

Case 4

A 48 year old female patient reported with the chief complaint of swelling in right side of the face since 1year. Swelling appeared while eating and subsided on its own in 2-3 hours.

Intra oral examination showed reduced salivary secretion of parotid gland. There was mucoid discharge from the opening of right parotid gland after milking of gland.

Conventional radiography did not reveal any pathology. Sialography showed ductal blockage near the orifice of right parotid duct.

CT scan of the patient showed a small calculus in the right parotid duct in its terminal part. (Figure 4a) Parotid Gland Plain and Gadolinium enhanced Magnetic

Resonance Imaging revealed dilatation of right Stensen's duct and secondary ducts within the right parotid gland. (Figure 4b) The right parotid gland was slightly smaller in size than left and showed mild heterogeneously high signal intensity on T₂ weighted sequences with heterogeneous enhancement on administration of contrast. The stone was not evident on MRI but the effect of this small calculus on the ductal system was clearly seen. Hence the diagnosis of sialolithiasis with chronic sialadenitis showing dilatation of right Stensen's duct and secondary ducts within the right parotid gland was made.

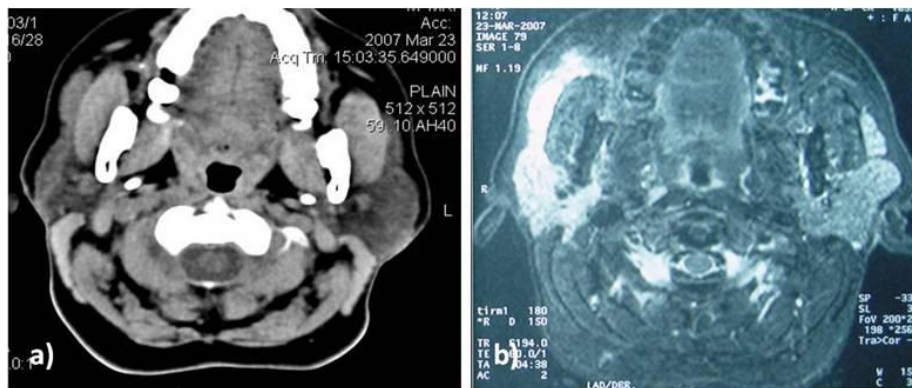


Figure: 4 a) CT scan showed a small calculus in the right parotid duct in its terminal part. b) MRI revealed dilatation of right Stensen's duct and secondary ducts within the right parotid gland.

Case 5

A 42 yr old asymptomatic male patient was referred for CBCT for implant purpose.

CBCT showed multiple, well defined oval shaped radiopacities mesial to the mandible on left side. (Figure 5) The two

large radioopacities were measuring 16.87x5.87mm and 8.95x4.72mm. Multiple left submandibular sialoliths were seen as an incidental finding.

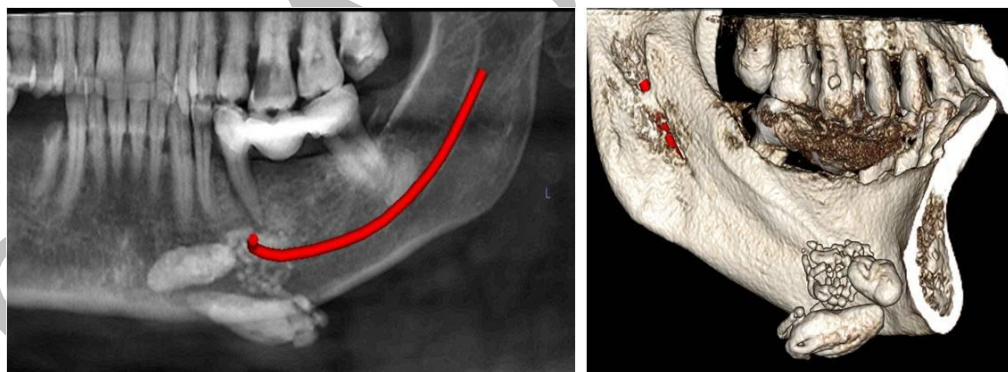


Figure 5: CBCT showed multiple, well defined radiopacities mesial to the mandible on left side.

DISCUSSION

Diagnosis of sialolithiasis is most of the times based on its clinical presentation and symptoms. It is also called as mealtime syndrome as patient

may complain of intermittent swelling in the salivary glandular region and pain during mealtime due to increased intraglandular pressure.¹

Sialoliths can be single or multiple. Their size may vary from less than 10 mm to abnormally large up to 15 mm in size.¹ Salivary calculi may occur within the intraglandular ductal tributaries or within the main ducts and are most commonly seen in submandibular gland (80%-95%), followed by parotid gland (5%-20%), sublingual & minor salivary glands (1%-2%).⁴

Clinically, the salivary stones have various presentations; they may be round or ovoid, rough or smooth & predominantly yellowish in color. It mainly consists of calcium phosphate with trace amounts of magnesium, potassium and ammonium. Submandibular salivary stones are composed of 82% inorganic & 18% organic material, whereas parotid stones are composed of 49% and 51%, respectively, therefore 40% of the parotid stones are radiolucent on radiographs.⁵

Radiographic examination is essential for diagnosis and treatment planning of sialolithiasis. The presence of sialolithiasis is confirmed by conventional radiography in 80% of cases, but the remaining 20% may need ultrasound, sialography, computed tomography, cone beam computed tomography, magnetic resonance imaging or sialoendoscopy.⁶

Imaging studies are useful for determining the exact location of sialolith, its dimensions, presence or absence of multiple stones and its effect on the ducts or the salivary gland.

In case 1 a standard mandibular occlusal radiograph was made as it is the best view to visualize the radiopaque submandibular duct stone. Occlusal radiograph showed a radiopacity which was present within the soft tissue of the floor of mouth on left side near the lingual cortical plate in 32-34 region, was oval in shape & approximately 6 X 4 mm in size. As the stone was located in the distal part of the duct close to the duct orifice, no further radiographic investigations were done. The stone was removed by giving small incision near the duct orifice.

Conventional radiography is used as a preliminary investigation in detecting the presence of sialoliths. Submandibular duct sialolith can be detected on standard mandibular occlusal radiograph. Parotid duct sialolith can be seen on Posteroanterior tangentially rotated radiograph. OPG can also reveal presence of parotid or submandibular sialoliths. However, radiolucent sialoliths cannot be detected on conventional radiography. As conventional radiography gives two dimensional representation of three

dimensional objects, has limitations like superimposition and image distortion, and does not give any idea about the effect on soft tissues; it plays a limited role in diagnosis and treatment planning for sialolithiasis.

Sialography is a traditional diagnostic method in which a radioopaque contrast agent is injected in the ductal system and radiographs are made. It is useful in detection of radiolucent stones or deep submandibular or parotid stones and shows ductal dilatations and blockage very clearly. The procedure is contraindicated in acute infections of salivary glands and in patients allergic to the contrast media.⁷

Submandibular or parotid sialolith larger than 2 millimetres can be easily detected with ultrasonography (USG).² USG is operator dependent, with no directly interpretable image for the surgeon, unless the surgeon is performing the investigation.

Case 2 had similar complaint as case 1 but standard mandibular occlusal radiograph did not reveal any abnormality. Panoramic radiograph showed a round radiopacity measuring about 8mm in diameter, below the inferior alveolar nerve canal distal to 38. To confirm the presence of sialolith and to know its exact location

CT scan was done. CT scan showed presence of sialolith in proximal part of the duct and left submandibular gland was normal. The sialolith was removed surgically.

High-resolution computerized tomography is considered to be the most sensitive method for the detection of sialoliths. Due to presence of soft tissue window and use of contrast agent in CT scan, effect of sialoliths on the duct or the parenchyma can be studied in detail.³ In case 3, Post contrast CT scan showed enlarged left Submandibular gland with contrast enhancement suggestive of sialadenitis. Though clinical findings like enlarged and tender submandibular gland and pus discharge from duct were suggestive of sialadenitis, CT scan was helpful in localization of sialolith and confirmation of its effect on the gland.

Magnetic resonance imaging is a recent, non-invasive diagnostic procedure with the advantage of no radiation exposure. Glandular parenchyma and ducts are seen more clearly, compared to other available techniques.⁸

In case 4, MRI was done only for academic purpose with patient's consent. MRI showed dilatation of right Stensen's duct and secondary ducts within the right parotid gland. The right parotid gland was

slightly smaller in size than left and showed mild heterogeneously high signal intensity on T₂ weighted sequences with heterogeneous enhancement on administration of contrast. The stone was not evident on MRI but the effect of this small calculus on the ductal system was clearly seen.

According to Yonetsu et al, if there is suspicion of sialolithiasis, CT scan should be recommended first, since; MRI is not very reliable in detecting small calculi. To assess the ductal architecture and salivary stones, investigators have advised thin sections of fast T₂ weighted MRI. Although beautiful images of the salivary ductal system can be generated with thin section T₂ weighted MR imaging, tiny calculi can be overlooked on MR images because of signal void associated with the calcified stone. Clearly, CT, ultrasound and simple conventional radiography will enable identification of the calculi but MR imaging helps to visualize the effect of sialolith on the ductal system as seen in our case 4.⁹

Cone beam computed tomography, with its dual advantage of low radiation dose and multiplanar imaging has become an integral part of dentistry. Apart from its routine use in implant planning and

impactions, it can very efficiently detect soft tissue calcifications as in our case 5.¹⁰ Since CBCT has poor soft tissue contrast, effect on the soft tissues adjacent to the lesion cannot be commented.

Different treatment options are selected according to the size and location of the sialolith. Small stones often “milked out” through the ductal orifice using bimanual palpation. When the stone is excessively large or spotted in the proximal duct, shock wave lithotripsy or surgical removal of the salivary calculi or gland may be required. Sialoendoscopy is a new procedure and is minimally invasive technique for treating large salivary stones.⁴

CONCLUSION

Several imaging modalities can be utilized in the diagnosis of sialolithiasis, yet the most appropriate is chosen by patient's presenting symptoms. Plain film radiography is an appropriate starting point from a cost benefit point of view. Although indications for CT and MRI may overlap, Contrast enhanced CT may demonstrate hard and soft tissue with minute differences in soft tissue densities. However MRI is an appropriate alternative modality to accurately reveal ductal morphology in cases in which sialography is contraindicated.

REFERENCES

1. S.R Ashwini Rani, Suragimath G, Bijjaragi S, Shetty P. K, Mealtime syndrome: An Enigma to Resolve. *J Adv Med Dent Science*. 2014; 2(1):120-23.
2. Tomasz Kopec, Małgorzata Wierzbicka, Witold Szyfter, Małgorzata Leszczyn'ska. Algorithm changes in treatment of submandibular gland sialolithiasis. *Eur Arch Otorhinolaryngol*. 2013; 270: 2089–93.
3. Nagla'a Abdel-Wahed, Maha E. Amer, Noha Saleh Mahmoud Abo-Taleb. Assessment of the role of cone beam computed sialography in diagnosing salivary gland lesions. *Imaging Science in Dentistry*. 2013; 43: 17-23.
4. Bodner L. Giant salivary duct calculi: Diagnostic imaging & surgical management. *OOOE*. 2002; 94:320
5. S. J. Siddiqui; sialolithiasis: an unusually large Submandibular Salivary stone. *British Dental Journal*. July 2002; 193 (2):89-91.
6. Victoria Pastor-Ramos, Alfonso Cuervo-Díaz, Luis Aracil-Kessler. Sialolithiasis. Proposal for a new minimally invasive procedure: Piezoelectric surgery. *J Clin Exp Dent*. 2014; 6(3):e295-8.
7. Williams M F. Sialolithiasis. *Otolaryngologic Clinics of North America*. 1999; 32: 819-34.
8. M. Andretta, a. Tregnaghi1, v. Prosenikliev, a. Staffieri. Current opinions in sialolithiasis diagnosis and treatment. *Acta Otorhinolaryngol Ital*. 2005; 25: 145-49.
9. Sumi, Izumi, Yonetsu, Nakamura Sublingual Gland: MR Features of Normal and Diseased States. *American Journal of Roentgenology*. 1999; 172: 717-22.
10. Dreiseidler T, Ritter L, Rothamel D, Neugebauer J, Scheer M, Mischkowski RA Salivary calculus diagnosis with 3-dimensional cone-beam computed tomography. 2010 Mosby.