

Forgotten Montgomery T-tube stent: A case reports and Review of literatureDr (Maj) Prasanna Kumar S¹, Prof. Lt Col. Ravikumar², Dr Somu L³, Dr Nazrin Mohd Ismail⁴**Abstract**

Background: Airway stenting is one of the many methods of managing complex laryngotracheal stenosis. The silicone T- tube described by Montgomery WW is widely used for stenting the stenotic segment. The ideal duration of stenting with this tube is not known.

Objective: To understand the clinical presentation and outcome of two cases of long forgotten Montgomery T- tube stenting. **Method:** Clinical case reports of laryngotracheal stenosis who presented to us after 11 years and 9 years of initial stenting with Montgomery T- tube. **Results:** T- tube removal and successful closure of tracheostomy was done in one case. Due to persistent stenosis at the subglottis T- tube had to be reinserted in the second case. **Conclusion:** Silastic T-tubes are relatively well tolerated, safe to use in definitive management of laryngotracheal stenosis. They can possibly be used for prolonged period of time and can be safely reused in the same patient after sterilisation. To the best of our knowledge this is the first report of the changes that would take place in a long standing T-tube. Though these two cases did not receive medical care in the interim period, we recommend biannual review and regular follow up for patient who are stented with T-tube.

Key words: Airway stent, laryngotracheal stenosis, T-tube stenting

¹Associate Professor, ²Professor and Head, ³Professor, ⁴Postgraduate student
Dept of Otorhinolaryngology, Head & Neck Surgery, Sri Ramachandra Medical College and research Institute, Porur, Chennai, (India)

Corresponding author mail: sprasannakumar10@gmail.com

Introduction

Laryngo-tracheal stenosis (LTS) is a complex problem associated with significant morbidity and mortality. The management of laryngotracheal stenosis is a surgical challenge. Resection anastomosis is the gold standard, but has its own limitation. Airway stenting especially using silicone T – tube still has a role to play in management of complex airway stenosis ^[1]. Montgomery WW

(1965) initially described this T- tube which is still being used widely the world over ^[2, 3].

A. Carretta et al have broadly identified the indications for Montgomery T- tube stenting ^[2]. a) Contraindication to definitive surgical treatment, b) Temporary stenting before definitive surgery and c) Complication of surgical treatment (resection anastomosis). The duration of stenting varies from patient to patient. The

exact duration of stenting for one single use of silastic Montgomery T- tube is not known. The changes that occur in a long standing Montgomery T- tube have not been described in literature.

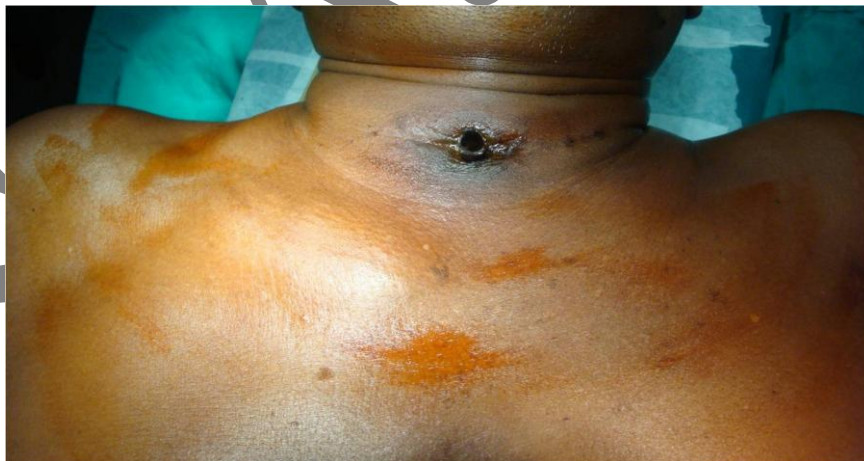We report 2 cases of laryngotracheal stenosis, which were treated with Montgomery T- tube stenting. These patients were lost for follow up for 11 and 9 years respectively and then reviewed and managed by us.

Case 1

A 48 year old male presented with complaints that the projecting part of the T- tube in his neck has almost disappeared and that there was foul smell emanating

from the stomal opening in the neck. On review of his case records it was found that he had sustained diffuse axonal injury following a road traffic accident 11 years back. He was intubated and managed in the ICU for 15 days. Subsequently, a month later after extubation he had developed cervical tracheal stenosis for which laserisation of tracheal stenosis and a Montgomery T- tube no 10 size stenting was done at our university hospital. He did not come for follow up for 11 years. At presentation, he was comfortable with no respiratory distress. We could barely see a brown corroded tube buried within the tracheal stoma (Figure 1).

Figure 1: Showing the 'almost buried' T tube insitu at presentation, in the first patient 11 years after implantation.



Flexible laryngoscopy and flexible tracheobronchoscopy through the T- tube showed no significant abnormality in the rest of the traheobroncheal tree. Under monitored anaesthetic care, we removed

the T- tube in one piece. The T- tube was found to be brown in colour, there was a white coating on the outer side of the tube at the upper end (Figure 2). This tube was very stiff and brittle. Since there was no

respiratory distress and the repeat flexible scopy showed no significant abnormality we decannulated him on table. This patient

is phonating well with no respiratory distress at 2 year follow up.



Figure 2: The T tube after removal. Note the change in colour, corrosion of the horizontal limb and the crusting 'biofilm' at the upper end of the tube.

Case 2

A 23 year old girl presented to us with respiratory distress for past 10 days. Review of case records revealed that this patient was treated for organophosphorous poisoning for which she was on prolonged ventilation followed by elective tracheostomy. Later, she developed supra stomal tracheal stenosis for which a Montgomery T- tube stenting was done 9

years back. She was lost for follow up. At presentation, she was in stridor. Conducted sounds were heard in both lung fields. Examination of the neck showed a brown corroded horizontal limb of the T-tube jutting out of the tracheostoma. Flexible endoscopy was tried but showed a dry crust in the tube which was hard. T- tube was removed (Figure 3).

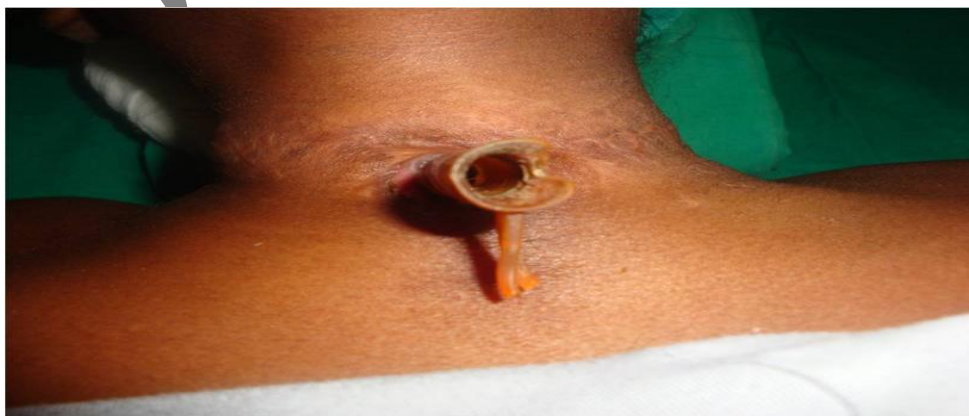

Figure 3: Showing the T- tube in-situ in the second patient 9 years after initial implantation

Flexible endoscopy done immediate post removal showed grade 1 narrowing in the subglottic region. The tracheal stoma was strapped and the patient was kept under observation and started on oral and inhalation steroids. She developed mild respiratory distress on 8th day which was

gradually progressive. Videolaryngoscopy and flexible laryngoscopy done on day 10 showed a significant narrowing at the subglottis (Figure 4) as well as in the lower trachea 2 cm above the carina. Hence we had to reinsert a new T-tube stent to maintain her airway.

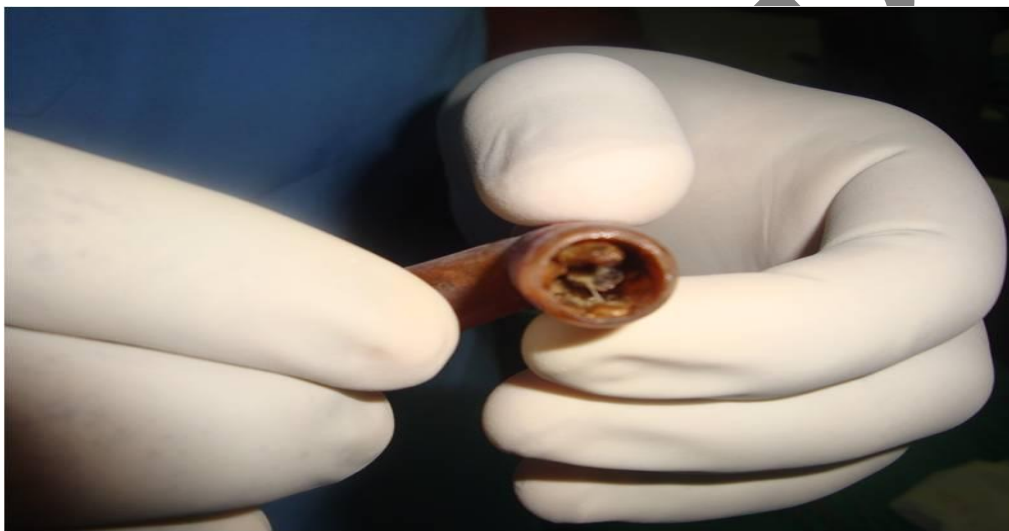


Figure 4: Showing the dry crusts within the T- tube immediately after removal

Discussion

The term 'stent' refers to a tube used in blood vessel or in a hollow organ to support it, and is an eponym after the English dentist Charles Stent^[4]. There are many types of airway stent which has been described in literature^[5-7]. C. S. Chin et al have discussed in detail the types of stents, their indication advantages and disadvantages of each type of stent. The silicone based Dumon and Montgomery T-tube stents is perhaps the most widely used stent worldwide^[8]. We have been using

the Montgomery T-tube stent in management of complex cervical laryngotracheal stenosis.

Montgomery T- tube is a temporary stent and needs to be replaced. The question of how long a silicone stent can be left in is very difficult to answer. A large scale prospective study is practically not possible because of ethical issues. A Carretta et al have recommended the change of T-tube once in 9- 12 months^[3]. Bernd Schmidt et al have reported that a silastic tracheal stent can be safely left in

situ for a period of 5 years in case of definitive long term treatment ^[9]. However, they also recommend annual inspection of the indwelling stent and cleaning.

In this article we report two cases of T-tube which was left in situ for a period of 11 years and 9 years respectively. These stents were long forgotten without any medical care or follow up during this period. In case one medical attention was sought when the horizontal limb of the T-tube had almost disappeared into the stoma (Figure1) and in case two when the patient experienced mild respiratory distress. Though both these stents had changed colour and were coated with bio film and crust (Figure 2 & 3) there was no evidence of active tissue reaction, infection / inflammation, or growth (malignancy) noted within the lumen of the larynx and trachea after removing the T-tube. Francesco Puma et al in their experimental study have compared the efficacy and long term tolerability of three types of stent i.e. self expandable metallic stents (Gianturco), the silicone stents (Dumon) and covered self-expandable synthetic stents (Polyflex). They have concluded that the silicon stent is better tolerated by the host mucosa compared to other stents ^[10].

Frank Schmal et al have studied the microbiological consequence of Montgomery T-tube stenting and have reported colonisation by *Staphylococcus aureus* and *Pseudomonas aeruginosa* at the subglottis and around the stoma and these are the two the main areas for formation of granulation ^[11]. In both our cases examination of the T-tube after it was removed showed the presence of crusting and biofilm at the upper end and stoma (Figure 2 & 4). Since there was no granulation or inflammation in the subglottis and trachea we did not send the specimen for culture and sensitivity.

There are many problems related to the use of T-tube that have been reported in literature. The most common among them is granulation at the stoma and the subglottis ^[10], crusting of secretion within the T-tube (Figure 4) can sometimes be very troublesome ^[6]. We had one case in which there was such severe crusting of the T-tube that we had to remove it and replace it with a tracheostomy tube. Restenosis can occur after removal of the stent as seen in our second case.

These two cases of forgotten T-tube bear testimony to the fact that silastic stents are relatively well tolerated in some patient and can be used for definitive stenting for long period of time. We

recommend a biannual inspection of the T-tube and tube change at least once a year. We could not find any reports of T-tube which has been left insitu for such a prolonged period of time and that too without any medical care.

Conclusion: Silastic T-tubes are relatively well tolerated, safe to use in definitive management of laryngotracheal stenosis. They can possibly be used for prolonged period of time and can be safely reused in the same patient after sterilisation. To the best of our knowledge this is the first report of the changes that would take place in a long standing T-tube. Though these two cases did not receive medical care in the interim period, we recommend biannual review and regular follow up for patient who are stented with T-tube.

References

- Hermes C. Grillo. Stents and sense. *Ann Thorac Surg* 2000;70:1142
- Montgomery WW. T-tube tracheal stent. *Arch Otolaryngol* 1965; 82:320—1.
- Carretta et al. *European Journal of Cardiothoracic Surgery* 36 (2009) 352—356.
- Ring, Malvin (2001). "How a Dentist's Name Became a Synonym for a Life-saving Device: The Story of Dr. Charles Stent". *Journal of the History of Dentistry* 49 (2): 77–80. PMID 11484317.
- Casal RF. Update in airway stents. *Curr Opin Pulm Med*. 2010 July;16(4):321-8.
- C. S. Chin, V. Litle, J. Yun, T. Weiser, and S. J. Swanson. *Airway Stents Ann. Thorac. Surg.*, February 1, 2008; 85(2): S792 - S796.
- Wood, Douglas E., Liu, Yun-Hen, Vallieres, Eric, Karmy-Jones, Riyad, Mulligan, Michael S. *Airway stenting for malignant and benign tracheobronchial stenosis Ann Thorac Surg* 2003 76: 167-174
- Vergnon J, Costes F, Polio J. Efficacy and tolerance of a new silicone stent for the treatment of benign tracheal stenosis: preliminary results. *Chest* 2000;118(2):422-426
- Bernd Schmidt, Heidi Olze, Adrian C. et al. Endotracheal balloon dilatation and stent implantation in benign stenoses *Ann Thorac Surg* 2001 71: 1630-1634
- Francesco Puma, Raffaele Farabi, Moira Urbani, et al. Long-Term Safety and Tolerance of Silicone and Self-Expandable Airway Stents: An Experimental Study. *Ann Thorac Surg* 2000;69:1030-1034
- Schmäl, F., Fegeler, W., Terpe, H. J., Hermann, W., Stoll, W. and Becker, K. (2003), Bacteria and Granulation Tissue Associated With Montgomery T-Tubes. *The Laryngoscope*, 113: 1394–1400. doi: 10.1097/00005537-200308000-00024.