

Incidental Detection of Microfilaria on Fine-Needle Aspiration Cytology (FNAC) of a Breast Lump-A Case Report

Dr. Madhuri S.Kate¹, Dr. Preeti Jain², Dr Rita Dhar³

Abstract

Introduction: Filariasis is a major public health problem in tropical countries like India. It is caused by *Wuchereria bancrofti* and *Brugia* species. The diagnosis is conventionally made by demonstrating microfilariae (MF) in the peripheral blood smear. Microfilariae (MF) have been incidentally detected in fine needle aspiration cytology (FNAC) smears of various lesions in clinically unsuspected cases of filariasis with absence of microfilariae in the peripheral blood. **Case presentation:** We report a case of MF in the breast diagnosed on fine needle aspiration cytology (FNAC) smears of a 32 years old woman. It was clinically diagnosed as fibroadenoma breast. **Conclusion:** The identification of MF in FNAC smears plays a significant role in diagnosis of disease and institution of specific treatment.

Keywords: Fine needle aspiration cytology, Fibroadenoma breast, Filariasis, Microfilaria

¹ Professor & Head, ² Specialist

Department of Pathology, ESI-PGIMS and Model Hospital, Andheri (East), Mumbai-93.

³ Head of Department of Pathology, MGM Medical college and University of Health Sciences, Navi Mumbai, India.

Corresponding author email: preetiright@gmail.com

Conflict of interest: None

Introduction: Filariasis is an infectious parasitic disease and is regarded as a major public health problem in the tropical countries of Africa, Southern America, and Asia. Filariasis in India is caused by two closely related nematode worms, *Wuchereria bancrofti* (*W. bancrofti*) and *Brugia malayi*.⁽¹⁾ Transmitted by the

Culex mosquito, humans serve as the definitive host. *W. Bancrofti* / microfilaria (MF) may produce lesions in various sites by affecting the lymphatics of the lower limbs, spermatic cord, epididymis, testis, retroperitoneum and female breast.⁽¹⁾ Although the incidence is high in Indian subcontinent, yet it is rare to find MF and

adult worm in breast nodule and few such cases have been documented in literature.⁽²⁻³⁾ Here, we present a case of microfilaria detected by fine needle aspiration cytology (FNAC) of breast lump with the clinical suspicion of Fibroadenoma reported at a tertiary care hospital.

Case Report:

A 32-year-old female presented with a painless nodule in the upper outer quadrant of the right breast since two months. Clinical examination revealed a mobile nodule measuring 3 × 2 cm. There was no axillary lymphadenopathy. Systemic examination was unremarkable. Examination of peripheral blood showed a hemoglobin level of 10.8 g/dl with a normal total leucocyte count and mild eosinophilia (differential count of

eosinophil - 09%). The erythrocyte sedimentation rate (ESR) was high, the value being 60 mm in the first hour.

FNAC was performed by a 24 G needle and yielded a granular material admixed with a turbid fluid. The smears were stained with the May-Grunwald-Giemsa (MGG) stain and Papanicolaou stain. The smears showed a sheathed parasite which was rounded anteriorly with elongated terminal nuclei and uniformly tapering posteriorly with a clear space free of nuclei at the caudal end – thus morphologically resembling MF of *W. bancrofti*. (Figures 1 and 2). Smears also revealed scattered inflammatory cells comprising polymorphs, lymphocytes and few histiocytes along with few clusters of benign ductal epithelial cells. A diagnosis of filariasis of breast was made.

Figure 1

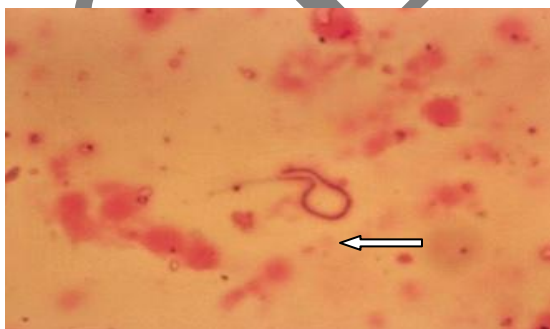

Figure 2

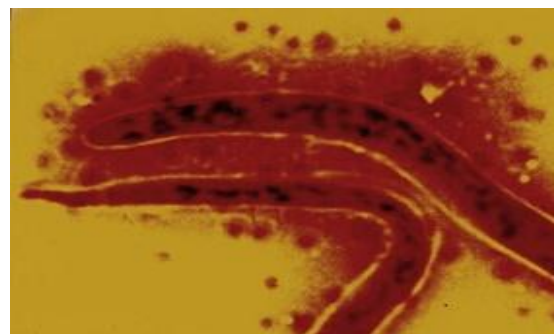


Figure 1 Cytological examination showed microfilaria (arrow) against background inflammatory cells comprising polymorphs, lymphocytes and histiocytes. May-Grunwald-Giemsa (MGG) staining, Scanner power view (10X)

Figure 2 Cytological examination showed microfilaria. May-Grunwald-Giemsa (MGG) staining, high power view (400X).

The patient responded well to a combined treatment of amoxicillin-clavulanic acid, albendazole, and a 12-day oral course of diethylcarbamazine (DEC). The breast swelling gradually resolved within 2 weeks of the initiation of therapy.

Discussion

“Filariasis” refers to lymphatic filariasis (LF) caused by *Wuchereria bancrofti* (*W. bancrofti*) and *Brugia* species.⁽¹⁾ Of these, *W. bancrofti* is common in India and shows nocturnal periodicity. It has been estimated in December 2006, that the total population at risk of LF was estimated to be 1,254 million in 83 endemic countries of which 64% was contributed by South-East Asia Region (SEAR) alone. In India it is estimated 554.2 million population are at risk of LF.⁽⁴⁾ The endemic areas are mainly

the sea coast and the banks of large rivers. Humans serve as the definitive host while *Culex* mosquitos serve as the vectors.⁽¹⁾ Lymphatic filariasis is so called because the adult worm lives in the lymphatic system of the definitive host and microfilaria (MF) is released and circulated in the peripheral blood. Lymphangitis, lymphadenitis, and lymphedema resulting in elephantiasis are various manifestations of lymphatic filariasis.⁽¹⁾ Most people with microfilaraemia do not show signs or symptoms of the disease but are important source of infection in the community. Thus, disease and infection do not necessarily accompany each other.⁽⁵⁾ The lifecycle of *Wuchereria bancrofti* is depicted in the following figure 3.

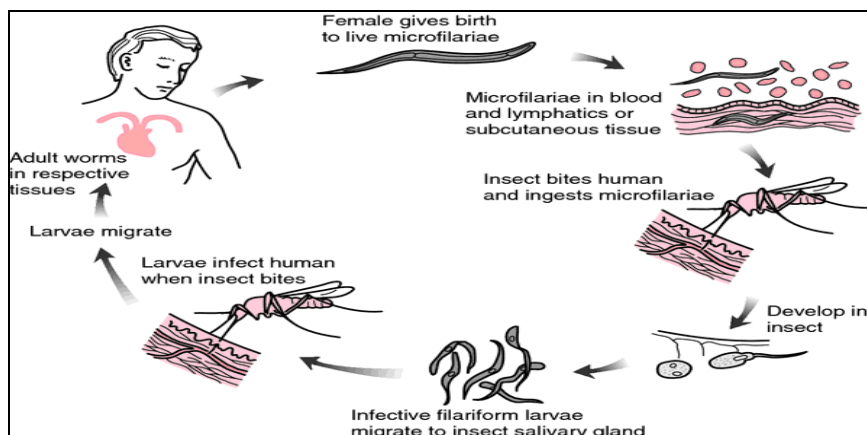


Figure 3 Lifecycle of *Wuchereria bancrofti*

Diagnosis of filariasis is usually made by finding MF in peripheral blood or skin and detection of filarial antigen and antibody. Adult worms can be detected in lymphatics, subcutaneous tissue, peritoneal and pleural cavities, heart, brain, scrotum and breast. However, in India filarial infection of the breast is very rare.⁽²⁻³⁾ The diagnosis is made on clinical grounds in the endemic areas. There are various reports stating the presence of microfilaria using aspiration cytology in various sites like spermatic cord, epididymis, testis and retroperitoneum. In spite of a large number of such lesions diagnosed on cytology, it is unusual to find adult filarial worms in the breast aspirate. Thus, the detection of microfilarial worm in a breast lesion by FNAC is an extremely rare finding and only few such cases have been documented in literature.⁽⁶⁾ The other parasites reported in the breast are cysticercosis, schistosomiasis, and dirofilariasis.⁽⁶⁾ The patients usually present with solitary, non-tender, painless and unilateral breast lump. The upper outer quadrant is the most common site.⁽⁷⁾ Most of the lesions involve subcutaneous tissue and present as a hard mass with cutaneous attachment.

Sometimes accompanying inflammatory changes including oedema of the skin makes it clinically indistinguishable from carcinoma.⁽⁷⁾

In cases of filariasis the host tissue immune response is variable, with intact worms provoking only minimal reaction. The degenerating parasite can be associated with inflammatory cell infiltration particularly eosinophils.⁽⁷⁾ Thus, the diagnosis of mammary involvement by *W. bancrofti* is dependant on the specific microscopic features of the adult worms and MF [9]. In the present case, MF was not detected in blood smear. Only FNAC confirmed the presence of MF. Filariasis is treated by diethylcarbamazine therapy.⁽¹⁾

Conclusion

As the cytomorphology of filariasis in breast aspirates is well characterised, the identification of MF in FNAC smears plays an important role in diagnosis of disease and institution of specific treatment. Thus, in countries where lymphatic filariasis is endemic, it should be considered in the clinical differential diagnosis of a soft tissue swelling. FNAC is a convenient and effective diagnostic method in patients with soft tissue mass.

This case is an interesting one as it was clinically suspected as fibroadenoma of the breast, but the FNAC revealed microfilarial worm. Also, although microfilariae in cytologic material are considered incidental findings, this case illustrates the value of routine fine needle aspiration cytology in the detection of asymptomatic and clinically unsuspected cases of bancroftian filariasis.

References

1. Park K. Textbook of Preventive and Social Medicine. 21st ed. Jabalpur: Banarsidas Bhanot Publishers; 2011. Epidemiology of communicable disease; pp. 244–50.
2. Kapila K, Verma K. Diagnostics of parasites in fine needle aspirates. *Acta Cytol.* 1996; 40:653–656
3. Rukmangandha N, Shanti V, Kiran CM, Nalini PK, Sarella JB. Breast filariasis by

fine needle aspiration cytology – a case report. *Indian J Pathol Microbiol.* 2006; 49:243–244

4. Weekly epidemiological record. Geneva: World Health Organization. 2007; 82(42):361–380

5. Kalpana Azad, Rashmi Arora, Kusum Gupta, and Uma Sharma. Lymphatic filariasis: Aspiration of adult gravid female worm from a soft tissue swelling. *J Cytol.* 2010; 27(4): 156–157.

6. K Sahai, K Kapila, K Verma. Parasites in fine needle breast aspirates—assessment of host tissue response. *Postgrad Med J.* 2002; 78:165–167

7. Hippargi SB, Kittur SK, Yelikar BR. Filariasis of the breast, diagnosed on fine needle aspiration cytology. *J Cytol.* 2007; 24:103–104

Acknowledgement:

We are grateful to Dr. Meenakshi Mathur, Dean, ESI PGIMS, Andheri (E), Mumbai, for her encouragement and support.