

Anatomical Study Of Arrangement Of Renal Hilar Structures In Indian Adult Human Cadavers

Dr. Surekha Dilip Jadhav*, Dr. Balbhim Ramchandra Zambare**

*Associate Professor, ** HOD and Professor, Department of Anatomy, PDVVPF'S Medical College, Ahmednagar, Maharashtra, India.

Abstracts: Background: Knowledge of arrangement of renal hilar structure is essential in the era of minimally invasive surgery. Nephron sparing surgeries like partial nephrectomy by laparoscope is treatment of choice and in this surgery hilar dissection is one of the important steps. However, in literature very few reports are available regarding the different patterns of dispositions of renal hilar structures. Aim of present study was to evaluate the arrangement of renal hilar structures. Methodology: Present work was carried out on fifty seven pairs of morphological normal kidneys of embalmed cadavers. Renal hilum of each kidney was dissected carefully to see the arrangement of renal artery, vein and pelvis. Results: Arrangement of renal hilar structures showed great variation. We classified arrangement of renal hilar structures into ten different patterns. In 22.80 % kidney we observed the arrangement of hilar structures according to textbooks. We observed anterior and posterior tributaries of renal vein in 32.45% and in 41.22% kidneys pelvis was the posterior most relation. Conclusion: Present study will help to understand the better knowledge of the disposition of hilar structures for the urological surgeons, radiologist and anatomists. [Jadhav S et al NJIRM 2015; 6(3): 49-53]

Key Words: Kidney, Nephrectomy, Renal artery, Renal hilum, Renal vein, Renal pelvis.

Author for correspondence: Dr. Surekha D Jadhav: - Associate Professor, Department of Anatomy, PDVVPF'S Medical College, Ahmednagar - 414111, Maharashtra, India. Email: drsurekhadjadhav@gmail.com

Introduction: Renal hilum is the middle concavity of the medial border which communicates with renal sinus. Classically, the disposition of renal hilar structures has been described in anatomical textbook from anterior to posterior as the renal vein, renal artery and renal pelvis^{1, 2}. However, there are reports which describe the variations in disposition of renal hilar structures. According to Standing et al. (2008)¹ about 70% of population has a single renal artery. Branching pattern of renal artery may vary. Posterior tributary of the renal vein may be present and it may pass anterior or posterior to pelvis and renal artery^{2, 3}. In certain kidney disorders nephrectomy is the choice of a therapeutic procedure and while performing it functional units of nephron are spared⁴.

According to Huang et al. (2006)⁵ radical nephrectomy may create problem for renal functions. But, laparoscopic partial nephrectomy (LPN) has many benefits⁶. While performing the laparoscopic partial nephrectomy (LPN) limited field of vision is available for hilar dissection and for clamping of renal vessels⁷. Now a days separate clamping of renal artery and vein is done because En-block clamping of these structures may result in Arterio- Venous fistula⁸. Surgeons who perform endopyelotomies should be aware of arrangements of the structures at the renal hilum because they have to perform hilar dissection⁹. Hence, the precise knowledge of normal and

variant anatomy of structures at the renal hilum is mandatory prior to any urological surgical interventions.

Usually, the variations in arrangement of renal hilar structures were detected incidentally while performing investigative imaging and angiographic procedures. Many researchers did work on the renal hilar structures especially renal arteries. However, there are very few detailed anatomical studies about the main renal hilar structures in Indian population. Considering the importance of arrangement of renal hilar structures during surgery especially LPN and renal transplant we evaluated the arrangement of main renal hilar structures in Indian population.

Material and Methods: The present work was carried out in our department on fifty seven (Total number of kidneys- one hundred and fourteen) pairs of morphological normal kidneys of embalmed cadavers. The mean age of the cadavers was 55 (range 39 to 73 years). All specimens were dissected from the whole cadaver and all kidneys were labeled and preserved in 10% formalin. Renal hilum of each kidney was dissected meticulously. After careful dissection, the arrangement of renal hilar structures was analyzed approximately 0.5 cm from the anterior lip of the renal hilum. Antero-posterior relations of structures were noted and

classified into various patterns. Accessory renal arteries were excluded from this study.

Results: The arrangement of renal hilar structures showed great variation in their relation at hilum. We classified the disposition of renal hilar structure into 10 various patterns (Table- 1).

Table 1: Showing the different patterns of arrangement of structures at renal hilum

Pattern	Arrangement of structures at renal hilum(Relations: Anterior--Posterior)
1A	RV- RA - P [Fig. 1]
1B	RV- AD- PD-P
2	AD-RV-PD-P [Fig.2]
3	AT- AD-P-PT -PD
4	RV-AD-P-PD [Fig.3]
5	AD-RV- P- PD
6	AD-AT -P-PD- PT [Fig.4]
7	AT-AD- PT-PD-P
8	AT-AD-PT-P-PD
9	Br from RA crossing RV-RV-AD -P-PD [Fig.5]
10	AD-AT- PT-P- PD ©

[RV-Renal vein, RA-Renal artery, P- pelvis, AD- Anterior division, PD- Posterior division, AT- Anterior tributary, PT- Posterior tributary, Br.- Branch]

Table 2: Number (n) and Percentage of each pattern

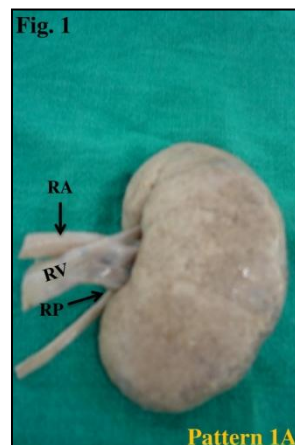
Pattern	Right (n=57)	Left (n=57)	Total (n=114)
1A	12 (21.05%)	14 (24.56%)	26 (22.80%)
1B	04 (7.01%)	07 (12.56%)	11 (9.64%)
2	03 (5.26%)	03 (5.26%)	6 (5.26%)
3	-	-	-
4	06 (10.5 %)	03 (5.26%)	09 (7.89%)
5	13 (22.80%)	10 (17.5%)	23 (20.17%)
6	12 (21.05%)	12 (21.05%)	24 (21.05%)
7	02 (3.50%)	02 (3.50%)	04 (3.50%)
8	03 (5.26%)	03 (5.26%)	06 (5.26%)
9	01 (1.75%)	01 (1.75%)	02 (1.75%)
10	01 (1.75%)	02 (3.50%)	03(2.63%)

Out of 57 cadavers only in 16 cadavers (28.07 %) we observed similar pattern of disposition of renal hilar structures bilaterally. In 7.19 % of the cases

the renal artery divided into anterior and posterior division and in 2 (3.5 %) cases we noted a branch given by main stem of renal artery which was crossing the renal vein (Fig.5).

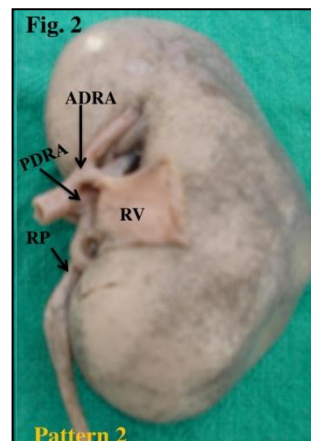
In 32.45 % cases we observed anterior and posterior tributaries of renal vein, in 38.59% of cases anterior division of renal artery was crossing renal vein and in 41.22% kidneys pelvis was the posterior most relation. The renal pelvis in between the divisions of renal artery and tributaries of renal vein was noted and details are shown in table 1. We noted that the renal pelvis was formed outside the hilum in 7 (6.1%) cases (Fig.6)

Fig. 1: Pattern 1A arrangement of renal hilar structures



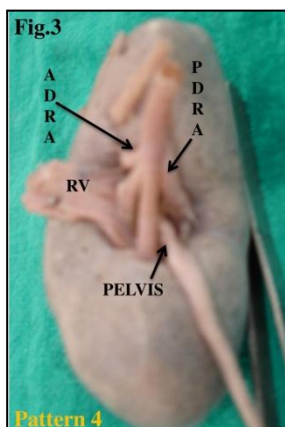
RA- Renal artery, RV- Renal vein, RP- Renal pelvis

Fig. 2 : Pattern 2 arrangement of renal hilar structures



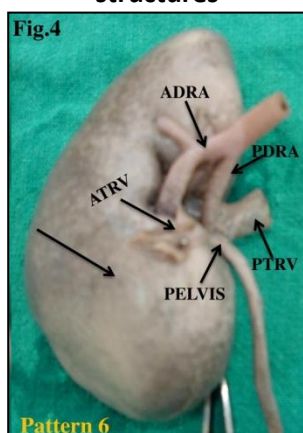
ADRA- Anterior division of renal artery, PDRA- Posterior division of renal artery, RP- renal pelvis, RV- Renal vein

Fig. 3: Pattern 4 arrangement of renal hilar structures



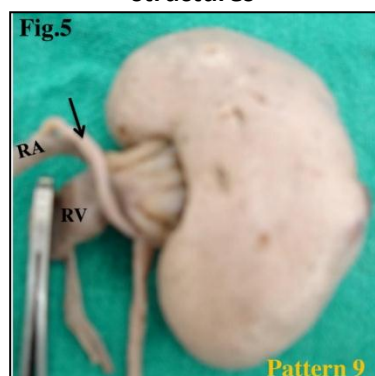
ADRA- Anterior division of renal artery, RV- Renal vein, ADRA- Anterior division of renal artery

Fig. 4: Pattern 6 arrangement of renal hilar structures



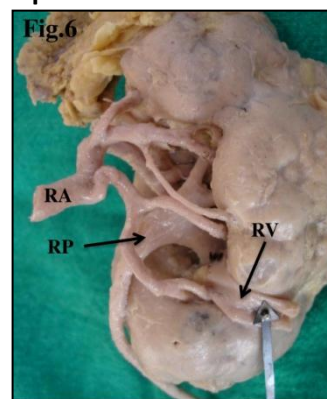
ADRA- Anterior division of renal artery, ATRA- Anterior tributary of renal vein, PTRV- Posterior tributary of renal vein, PDRA- Posterior division of renal artery

Fig. 5: Pattern 9 of arrangement of renal hilar structures



RV- Renal vein, RA- Renal artery, Black arrow shows branch from main stem of renal artery

Fig. 6: Black arrow showing Formation of renal pelvis outside the hilum



RA- renal artery, RV- renal vein, RP- renal pelvis

Discussion: Anatomical variations of renal hilar structures are not described in anatomy textbooks. Many researchers studied the renal vessels at perihilar and hilar region but there are very few reports about the arrangement of renal hilar structures. Urologist should have detailed knowledge of arrangement of the renal hilar structures before they perform various surgeries because during surgery they have to perform hilar dissection and hilar vessel clamping.

We classified the arrangement of renal hilar structures into 10 patterns while Trivedi et al. (2011)¹⁰ and Naveen Kumar et al. (2013)¹¹ observed 5 and 12 patterns. The normal anatomy of arrangement of renal hilar structures is described in pattern 1A while rest of the pattern described the variation in disposition of renal hilar structures. The results of our study were compared with similar previous studies (Table-3) and we noted that, each researcher got variable number of patterns and their incidence which may be because of anatomic variations of renal vessels are common in general population with different frequencies among several ethnic and racial groups. Present study observed that variant patterns are more common on left side which is in favor of Trivedi et al. (2011)¹⁰ and Naveen Kumar et al. (2013)¹¹.

Upper urinary tract obstruction commonly occurs due to obstruction at uretero-pelvic junction¹². Variant courses of renal vessels which crossed the renal pelvis were responsible for uretero-pelvic obstruction in 29- 65% cases^{13, 14}. We observed

that, in 2 cases a branch given by main stem of renal artery which was crossing the renal vein (Fig.5) which is very rare and clinically very important. In 34.21% cases there was presence of anterior and posterior tributaries of renal vein (Fig. 4). These variations should be kept in mind by surgeons and radiologist. In majority of cases the branches of renal artery and tributaries of renal vein occupy the perihilar and hilar region of kidney^{9,13}. We also observed the same results. Position of renal pelvis is also variable (Table 1). We observed that in 41.22% kidneys pelvis was the posterior most relation while Trivedi et al. (2011)¹⁰ reported it in 50%. Hassan et al. (2012)¹⁶ studied the variation in arrangement of structures at renal hilum in Bangladesh population and observed that renal pelvis was the posterior most structure in 100% kidneys which is in disagreement with our observations¹⁶.

Table 3: The comparison between the previous studies

Pattern	Joao et al. ¹⁵ (Brazil)	Trivedi et al. ¹⁰ (India)	Naveen Kumar et al. ¹¹ (India)	Present study (India)
V- A- P	83%	19%	45.8%	22.80%
V-A ₁ -A ₂ -P	-	08%	-	9.64%
A ₁ -V-A ₂ -P	-	23%	02.1%	5.26%
V-A ₁ -P-V-A ₂	-	22%	02.1 %	-
V-A ₁ -P-A ₂	-	20%	08.3%	7.89%
A ₁ -V-P-A ₂	-	08%	04.2%	20.17%
A ₁ -V ₁ -P-A ₂ -V	-	-	-	21.05%
V ₁ -A ₁ -V ₂ -A ₂ -P	-	-	-	3.50%
V ₁ -A ₂ -V ₂ -P-A ₂	-	-	-	5.26%
A ₁ -V ₁ -V ₂ -P-A ₂	-	-	-	2.63%
V-P- A	03%	-	02.1%	-
A-V-P	03%	-	28.1%	-

An [V- renal vein, A –renal artery, P- renal pelvis, A₁- anterior division of renal artery, A₂- posterior division of renal artery, V₁ anterior tributary of renal vein and V₂-posterior tributary of renal vein] A different variant pattern of disposition of renal hilar structures makes the crowding of structures at renal hilum and it may confuse surgeon and

pose difficulty during surgical dissection at hilar region and it may produce iatrogenic trauma to these structures and create emergency during surgery especially during laparoscopic partial nephrectomy. Therefore it is essential to have a detailed knowledge of renal hilar structures. Technically hilar dissection is more challenging in laparoscopic surgery than open surgery^{17,18}. Now a day, separate clamping of renal artery, vein and pelvis is preferred to En-block clamping of these structures which may result in Arterio- Venous fistula⁸.

Conclusion: We conclude from present study that, arrangement of structures at renal hilum and their numbers are highly variable than the classical pattern which is given in the standard textbooks of anatomy. Precise knowledge of normal and variant anatomy of arrangement of renal hilar structure is essential in the era of laparoscopic surgery, renal transplant, endopyelotomies and also during interpretation of various radiological techniques related to the kidney.

References:

1. Standring S, Borley NR, Collins P et al. Kidney. In Standring, S. (Ed.). Gray’s anatomy: The anatomical basis of clinical practice. 40th ed. London Churchill livingstone; 2008: 1225-1238.
2. Sinnatamby CS. Last’s anatomy regional and applied. 11th ed. UK: Churchill Livingstone Elsevier; 2006: 294.
3. Snell RS Clinical anatomy. 9th ed. Baltimore: Lippincott Williams and Wilkins; 2012: 207.
4. Nuygen M M, Gill I S, Ellison L M. The evolving presentation of renal carcinoma in the United States: trends from surveillance, epidemiology and end results program. J Urology. 2006; 176 (6): 2397-400.
5. Huang W C, Levey A S, Serio A M, Snyder M, Vickers A J, Raj G V, Scardino P T, Russo P. Chronic kidney disease after nephrectomy in patients with renal cortical tumours: a retrospective cohort study. Lancet Oncol. 2006; 7 (9): 735- 40.
6. Rogers C G, Metwalli A, Blatt A M, Bratslavsky G, Menon M, Linechan W N, Pinto P A. Robotic partial nephrectomy for renal hilar tumors: a multi-institutional analysis. J Urol. 2008; 180 (6): 2353-6.

7. Desai M M, Grill I S. Laparoscopic partial nephrectomy for tumour: current status at the Cleveland Clinic. *BIU Int.* 2005; 95 (2): 41-5.
8. Rapp D E, Orvieto M A, Gerber G S et al. Endoscopic stapling of renal hilum during laparoscopic nephrectomy and nephroureterectomy. *Urology.* 2004; 64 (4): 655-59.
9. Sampaio F J, Favorito L A. Endopyelotomy. Anatomical study of the vascular relationships to ureteropelvic junction. *J. Urol.* 1991; 97 (2): 73-77.
10. Trivedi S, Athavale S, Kotgiriwar S. Normal and variant anatomy of renal hilar structures and its clinical significance. *Int. J. Morphol.* 2011; 29 (4): 1379-83.
11. Naveen Kumar, Guru A, Aswini A P, Shetty S D, Nayak B, Narendra P. Evolution of the variant anatomical disposition of the renal hilar structures in south Indian adult human cadavers and its clinical implications. *J Clin Diagn Res.* 2013 Aug; 7(8): 1543-46.
12. Sampaio F J, Favorito L A. Ureteropelvic junction stenosis: vascular anatomical background for endopyelotomy. *J Urol.* 1993; 150: 1787-91.
13. Rouviere O, Lyonnet D, Berger P et al. Ureteropelvic junction obstruction: use of helical CT for preoperative assessment: comparison with intra-arterial angiography. *Radiology.* 1999; 213: 668-73.
14. Sampaio F J. The dilemma of crossing vessels at ureteropelvic junction: precise anatomic study. *J Endourol.* 1996; 10 (5) : 411-15.
15. Jaao A Lucas S V, Kenia F C, Guilherme P G, Celina A F, Rafael A D. Analysis of renal hilum extraparenchymal structures in Brazilian adult human cadavers. *Eur J Anat.* 2009; 13 (3): 145-53.
16. Hassan SM, Khalil M, Khalil M. Variation in arrangement of structures at hilum of human kidney. *Bangladesh Journal of Anatomy.* 2012; 10 (2): 76-79.
17. Gill I S, Colombo J R, Frank I, Moinzadeh A, Kaouk J, Desai M. Laparoscopic partial nephrectomy for hilum tumors. *J Uro.* 2005; 174 (3): 850-54.
18. Latouff J B, Beri A, D Ambros OF, Grull M, Leeb K, Janetsehek G. Laparoscopic partial nephrectomy for hilar tumors technique and results. *Eur, Urol.* 2008; 54(2): 409-16.

Conflict of interest: None
Funding: None
Cite this Article as: Jadhav S, Zambare B. Anatomical Study Of Arrangement Of Renal Hilar Structures In Indian Adult Human Cadavers. <i>Natl J Integr Res Med</i> 2015; 6(3): 49-53