

A Study Of 50 Cases Of Shoelace Repair For Midline Incisional Hernia.

Dr. Shah Bhavin K.*, Dr.GurjarVipul**

* Assistant Professor, ** Professor, Department of General Surgery, S.B.K.SM.I.R.C., Piparia, Vadodara, Gujarat, India.

Abstracts: Background & Objective: Incisional hernia of anterior abdominal wall is very common pathology come across in general surgical practice. Numerous surgical procedures have been described to repair them, with varying degree of success. This study aims to find the place of shoelace darn in the repair of anterior abdominal wall incisional hernias. Methodology: Fifty patients with anterior abdominal wall incisional hernias were managed by shoelace darn method in this prospective study. The details of operative technique have been described. Results: Shoelace darn repair of anterior abdominal wall incisional hernia was relatively easy procedure associated with fewer complications. There were no true recurrences noted. Conclusion: Shoelace darn repair still remains an excellent technique in the management of anterior abdominal wall incisional hernias, despite advent of mesh and laparoscopic repair. [Shah B NJIRM 2015; 6(3):10-13]

Key Words: Incisional hernia, shoelace repair, diabetes mellitus, mesh, modified shoelace technique.

Author for correspondence: Dr.Bhavin Shah,B/304,shree gokulesh residency, near vallabh vidhya mandir school, waghodia-dabhoi ring road, Vadodara -390025, Gujarat, India. E mail: drbhavin_08@yahoo.com.

Introduction: Midline ventral incisional hernias commonly follow median or paramedian incision for laparotomy. The incidence reported varies from 3.8 -11.5%, 90% of them within 3 years after surgery¹. They are second most common hernias after inguinal hernia. They may vary in size from 1-2 cm to huge, incorporating almost entire small bowel in hernial sac. Aetiology varies from technique used for closure of laparotomy incision, level of experience of surgeon (more common if closure done by resident surgeon), postoperative infection (almost doubles risk)², postoperative cough, nutrition and immunity of the patient and age. Incisional hernia is a clinical diagnosis, which can be confirmed by ultrasonography. Several studies in the past have compared shoelace repair and prosthetic mesh repair. The aim of study was to confirm the efficacy of shoelace technique, morbidity and mortality associated with it and to know its place in today's general surgical practice.

Material and Methods: This prospective study was carried out over a period of 2.5 years at our institute, S.B.K.S. M.I.R.C., Vadodara. 50 patients with midline incisional hernias were studied between September 2011 to march 2014. All the 50 patients had undergone shoelace repair. Permission of IRB was not taken as shoelace darn repair of anterior abdominal wall for incisional hernia is an established technique and it does not include any new drugs.

Inclusion criteria- All the patients with midline incisional hernia, irrespective of age and sex were

included in the study. All the patients underwent preoperative investigations for fitness including Complete Blood Count, Random Blood Sugar, Renal Function Tests, Liver Function Tests, Coagulation profile, X-ray chest, Electrocardiogram, Ultrasonography of the abdomen and if needed, Echocardiogram and Tread Mill Test. All fit patients were included in the study. Patients were kept indoor until stitch removal and were followed up in OPD. During post-operative period patients were studied for wound infection, seroma formation, recurrence and other major complications including intestinal injury and fistula formation, myocardial infarction, deep vein thrombosis and pneumonia.

Technique: Patients were given general or spinal anaesthesia, as suitable for individual patient. All the patients were given Inj. Ceftriaxone 1 gm 12 hourly and Inj. Amikacin 500 mg 12 hourly for 5 days, first dose at the time of incision. A Ryle's tube is introduced if patient is given general anaesthesia and Foley's catheter is introduced in all patients after induction of anaesthesia. Surgery begins with an elliptical incision to include old scar, and scar is excised. With alternate blunt and sharp dissection, a plain is developed between skin and subcutaneous tissue, and hernial sac. Dissection is deepened, so that hernial sac is freed from all sides from subcutaneous tissue, and neck of the sac (seen as anterior rectus sheath surrounding sac) is reached. If during dissection peritoneum of the hernial sac is inadvertently opened, we closed it with 2-0 polyglactin suture. If hernia sac protrudes

from only a part of previous incision, still we include whole incision in repair. Anterior rectus sheath is freed from overlying skin and subcutaneous tissue, throughout the length of incision, on both sides of previous incision. A significant width of anterior rectus sheath should be clearly seen all around the sac. Then we make a ribbon of anterior rectus sheath by incising it, about 1.5 cm lateral to the edge of sac, on both sides. This makes two parts of each anterior rectus sheath, one medial ribbon of 1.5 cm width and rest of the lateral part. Now these two medial ribbons of 1.5 cm width are approximated in midline by a continuous Nylon 1 no. Loop suture. As they are approximated, hernia sac automatically gets inverted and disappears after completion of this layer, underneath. Next, shoelace darn layer is taken by Nylon 1 no. Loop suture to bridge the gap between two lateral parts of anterior rectus sheath. Starting from the top of incision, each suture is passed about 1 cm lateral to edge of cut anterior rectus sheath, taking about 1 to 1.5 cm of anterior rectus sheath (cranio-caudally) with each bite. Then suture is passed through new midline, developed from medial ribbons of anterior rectus sheaths and then to the opposite side. Similar type of bite is taken on opposite anterior rectus sheath and suture is again reverted back to opposite side, taking the bite of new midline. Sutures should be approximately 0.5 cm apart and fairly tense to narrow the gap considerably between cut edges of anterior rectus sheath³. This way the missing anterior rectus sheath is replaced by Nylon loop suture. Negative suction drain is put in subcutaneous plane, after achieving haemostasis. Subcutaneous tissue is closed by intermittent 2-0 polyglactin suture. Skin is closed by Nylon 2-0 vertical mattress suture. We also have operated a case with modified shoelace technique, where after reconstructing new midline by shoelace method, a polypropylene mesh is fixed for missing anterior rectus sheath, with good result. Here mesh is fixed with continuous 1 no. Nylon loop suture, incorporating new midline and middle of the mesh, as shown in figure 4 and diagrammatically in figure 5, by midline blue suture. Periphery of mesh is sutured to cut edge of anterior rectus sheath by running 1 no. polypropylene suture as well as 10-12 intermittent polypropylene 2-0 fixing stitches⁴.

Figure 1: Operative photograph of completed dissection of hernia sac of a midline incisional hernia.

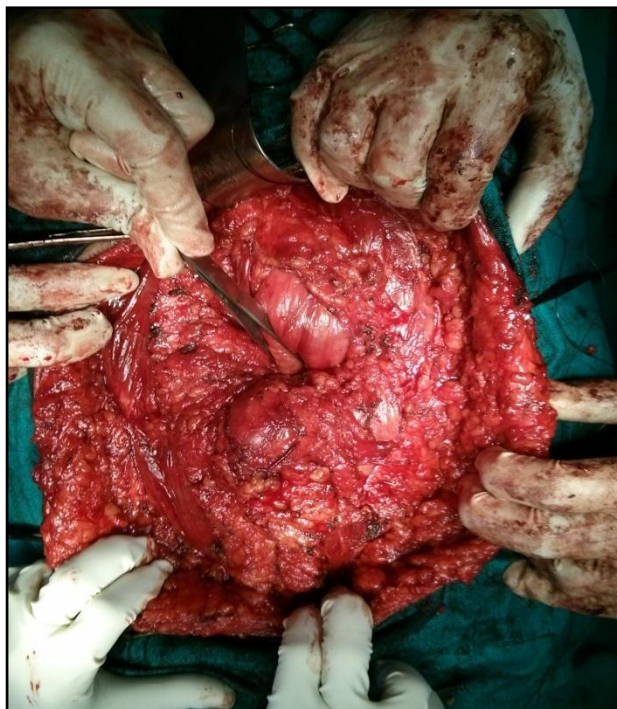


Figure 2: Operative photograph of completed shoelace darn repair of midline incisional hernia.

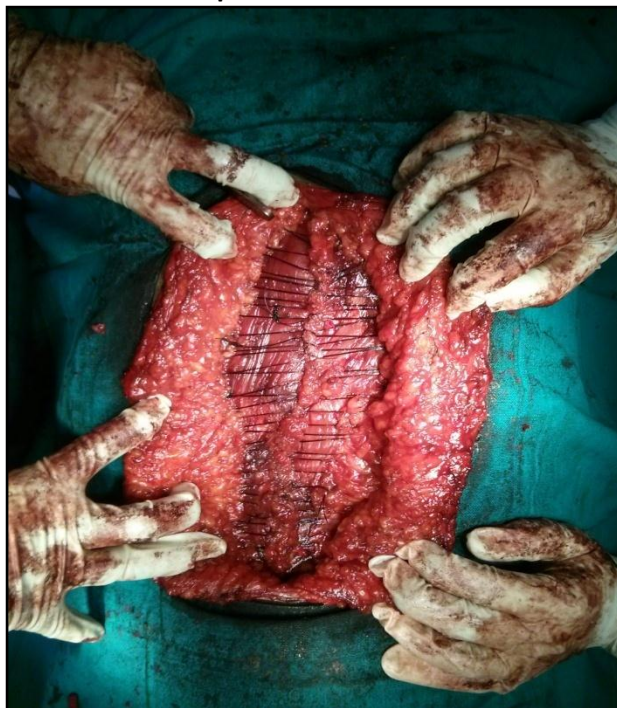


Figure 3: Diagrammatic presentation of shoelace repair.

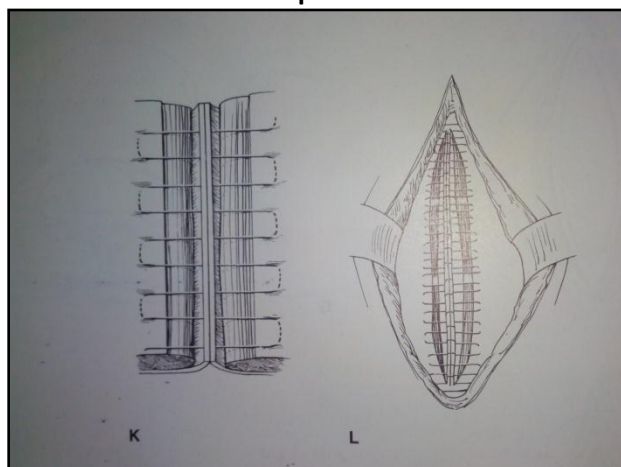


Figure 4: Modified shoelace repair using polypropylene mesh for missing anterior rectus sheath.

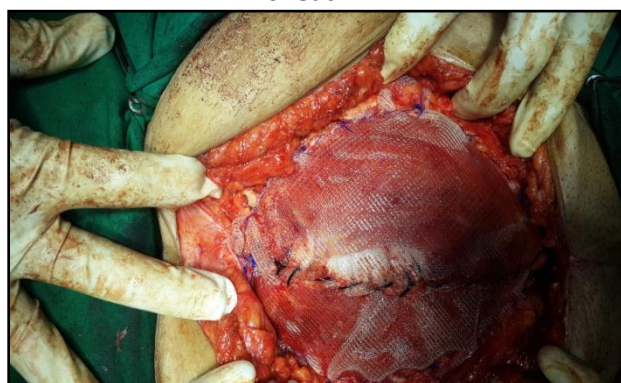
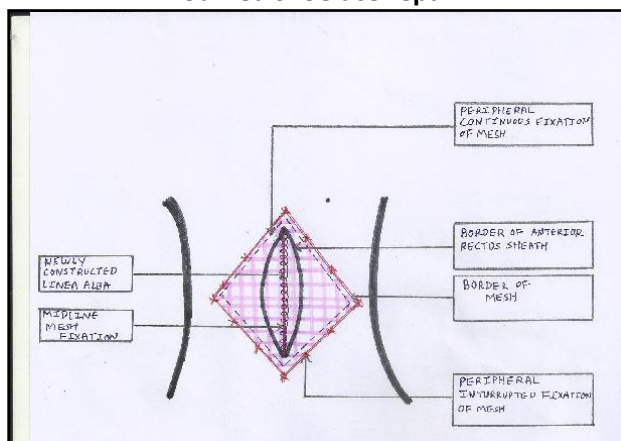


Figure 5: Diagrammatic representation of modified shoelace repair.



Results & Observations: 50 patients had undergone shoelace repair for midline ventral hernia. All the patients were kept hospitalized postoperatively until stitch removal.

1. Total hospitalization period was average 11 days, two days preoperative and 9 days postoperatively.
2. 2 patients (4%) had minor wound infection⁵, which responded to oral antibiotics.
3. 3 patients (6%) had serous discharge or seroma formation⁵, after removing negative suction drain, which responded to dressings within average 7 days.
4. There were no life threatening complications or no instances of deep vein thrombosis, hypostatic pneumonia or myocardial infarction⁶.
5. There was no recurrence noted. One patient had bilateral spigelian hernia after 6 months and had generalized decreased abdominal muscle tone. She was operated and spigelian hernias were repaired by polypropylene 1 no. continuous suture after invaginating peritoneal sac. A 30*30 cm mesh was fixed subcutaneously covering whole anterior abdominal wall.
6. Average operative time remained 3 hours.

Discussion: Midline incisional hernias are quite common. They can be surgically cured by insertion of prosthetic mesh via onlay(subcutaneous) repair, inlay(under rectus muscles), combined insertion method(two meshes, one onlay and one inlay), laparoscopically, by direct tissue repair or by shoelace repair. We have performed shoe-lace repair over the years and have found it an excellent method in preventing recurrence. Insertion of foreign body is a significant risk factor, predisposing to infection, in immuno compromised patients (diabetes mellitus, HIV, transplant patients etc.). We routinely avoid mesh insertion in diabetic patients and perform shoe-lace repair. We have noted only minor incidences of wound infection with this method, which easily respond to oral antibiotics. Most significant advantage is peritoneum is not opened; hence incidence of intestinal injury and fistulisation becomes nil.

Technique is quite simple and can be performed with relatively ease. No major expense is involved as 4 to 5 Nylon 1 no. loop sutures and suction drain only are required. Postoperative recovery is smooth and rapid. As soon as patient is fully awake Ryle's tube is removed. Ambulation is begun in the evening of operation. The intravenous infusion is

stopped the next morning and the patient is encouraged to walk, eat and drink normally. Complications are few and minor. The most serious complication is wound infection. Strict asepsis, gentle dissection and meticulous haemostasis are necessary to reduce wound infection. Vacuum drains are removed usually after 2 days.

Some authors have used shoelacing of ventral hernia defect along with laparoscopic ventral hernia repair to prevent seroma formation and restore near normal anatomy⁷.

Conclusion: We conclude that shoelace repair of ventral hernia is a significant armamentarium in the hands of a surgeon for incisional hernia repair and still it remains operation of choice for many patients, especially diabetic and immunocompromised patients.

References:

1. Matar Z. Open surgical management of incisional hernia. The Internet Journal of Surgery 2007;15(2);pp174-76
2. Sanders David L. The modern management of incisional hernias. British Medical Journal(BMJ) 2012;344:e2843
3. Abrahamson J. The Shoelace repair, Chap 71. In : Bendavid R, Abrahamson J, Arregui ME et al (eds.) Abdominal wall hernias : New York: Springer;2001;pp.483-96
4. Joshi MA, Singh MB, Gadhire MA. Study of the outcome of modified Shoelace repair for midline incisional hernia. Hernia 2014;014:pp.1234-8
5. Majid TA, Yaseen MM, Shakir WM. Shoelace darn repair of abdominal incisional hernia. The Iraqi Postgraduate Medical Journal 2007;6(3);pp.198-202
6. Johnson D, D. Harrison DH. A technique for repairing massive ventral incisional hernias without the use of a mesh .British Journal of Plastic Surgery 1999; 52(5) : pp. 399–403
7. Ornstein SB, Dumeer JL, Monteagudo J, Poi MJ, Novitsky YW. Outcomes of laparoscopic ventral hernia repair with routine defect closure using “shoelacing” technique. Surgical Endoscopy 2011;25(5);pp.1452-57

Conflict of interest: None
Funding: None
Cite this Article as: Shah B, Gurjar V, A study of 50 cases of shoelace repair for midline incisional hernia. Natl J Integr Res Med 2015; 6(3): 10-13