

A study of 50 cases of Stoppa's pre-peritoneal repair of bilateral inguinal hernia

Dr. Shah Bhavin K. *, Dr. Singh Vijoy **

* Assistant Professor, ** Professor, Department of General Surgery, S.B.K.S. M.I.R.C., Piparia, Vadodara

Abstracts: Background: Recurrent and complex bilateral inguinal hernias are associated with high recurrence rate. Giant prosthetic repair of visceral sac (GPRVS) is popular in America and Europe. In India it is less frequently performed procedure. We wanted to prospectively analyse the procedure. Methodology: In this prospective study 50 patients were operated, at our institute, over 2.5 years, for bilateral inguinal hernias, which included direct, indirect, recurrent and re-recurrent hernias. Patients were treated by GPRVS method of stoppa. Patients were observed for complications and followed up in O.P.D. for at least 1 year. Results: Developing pre-peritoneal plane was quite easy and there were minimal complications. Operative time varies from 30 minutes to 90 minutes and recurrence rate was nil at 1 year follow up. Conclusion: GPRVS is a very good operation for recurrent and re-recurrent inguinal hernias with minimal morbidity and mortality. [Shah B NJIRM 2015; 6(2):57-60]

Key Words: Recurrent inguinal hernia, pre-peritoneal plane, polypropylene mesh, Stoppa's GPRVS

Author for correspondence: Dr. Bhavin Shah, Department of General Surgery, S.B.K.S. M.I.R.C., Piparia, Vadodara – 391760. E-mail: drbhavin_08@yahoo.com

Introduction: Inguinal hernia is one of the most common pathology come across by a general surgeon. It is seen at all ages, direct hernia being common in elderly and indirect hernia in children and adults. It is a clinical diagnosis and can be confirmed by ultrasonography if necessary. There are a variety of surgical procedures ranging from tissue repair, prosthetic mesh repair by open as well as laparoscopic method. The aim of the study was to know the efficacy of Stoppa's pre-peritoneal approach as a primary treatment and in recurrent and re-recurrent inguinal hernia.

Material and Methods: This prospective study was carried out over a period of 2.5 years at our institution S.B.K.S. M.I.R.C., in department of General Surgery, Vadodara. As the study was done for an already established surgical procedure which did not involve any new drugs, permission of Institute Research Council was not taken. All the patients had undergone pre-operative fitness which included Complete Blood Count, Random Blood Sugar, Renal Function Tests, Urine analysis, Electrocardiogram and X-ray chest. Other investigations like echocardiogram and Tread Mill Test were done if necessary. In our first 3 cases, we chose patients with bilateral direct hernias with relatively small size. We then included patients with indirect hernias and recurrent hernias in study as we gained experience with technique.

Technique: All patients were given regional (spinal) anaesthesia. Patients were operated by lower

midline incision, starting just below umbilicus extending upto symphysis pubis. After incising skin, subcutaneous tissue and linea alba in midline, pre-peritoneal plane was developed by blunt dissection with fingers under abdominal wall muscles. In obese patients, a Trendelenburg position helps to reduce the hernia contents¹. Inferior epigastric vessels were identified and spared. Plane was developed upto space of Retzius (pre-prostatic space) and space of Borgos (upto obturator foramen). Posteriorly, psoas muscles and genital vessels were exposed. As plane is being developed, small direct hernia sac reduces itself. Larger sac may need some dissection. In indirect hernia, a finger is passed around the bundle of sac, vas deferens and genital vessels (spermatic cord), care being taken not to lift external iliac vessels with the bundle. Vas deferens can be clearly seen coming up from pelvis and genital vessels can be seen coming forward from psoas muscles. Sac is identified here and separated gently with plain forceps from cord components. Gentle continuous traction on sac may be necessary. After the sac is separated, vas deferens and genital vessels are separated as far as possible and paeritalized, being careful to leave the triangular sheath of areolar tissue between them. This sheath prevents direct contact between external iliac vessels and mesh. Paeritalization prevents weakening of mesh by cutting it for passage of spermatic cord². Larger sac may present some difficulty and a separate incision may be necessary in inguinal region to separate adhered sac from scrotum. During this

dissection peritoneum of sac may open inadvertently and it can be closed by polyglactin 3-0, so that small bowel does not protrude during dissection. Both vas and genital vessels can be lifted by a gauze piece for easier dissection. After paeritalization vas deferens and genital vessels no longer come in the way of mesh insertion. Polypropylene mesh is inserted in pre-peritoneal plane. Mesh size is decided as written below.

Vertical size= distance between umbilicus and pubic symphysis and horizontal size= 2 cm less then distance between two anterior superior iliac spines of patient ³.

Then mesh is cut in chevron shape to fit in pelvis. Mesh was put by hands of surgeon in our study v/s by 8 Kelly's clamps in original Stoppa's technique. It is spread upto both psoas muscles on both sides. Anteriorly it is spread upto prostate and obturator foramens . Two arms of No.18 negative suction drains were put anterior to mesh. Some have argued against drainage, saying it doesn't provide any benefit ⁴, but the amount of sero-sanguinous discharge on 1st post- operative day in our study do not provide us comfort for such experiment. Mesh size used 30*30 cm, material being polypropylene. Mesh is fixed to umbilical fascia of Richet by just one polyglactin 2-0 stitch. Linea alba is sutured by continuous 1 No. Nylon loop. Subcutaneous tissue is sutured by intermittent polyglactin 2-0 suture and skin by intermittent vertical mattress suture of Nylon No 2-0 .

Figure 1: Dissection Showing Direct Hernial Sac And Spermatic Cord (Encircled With Gauze)

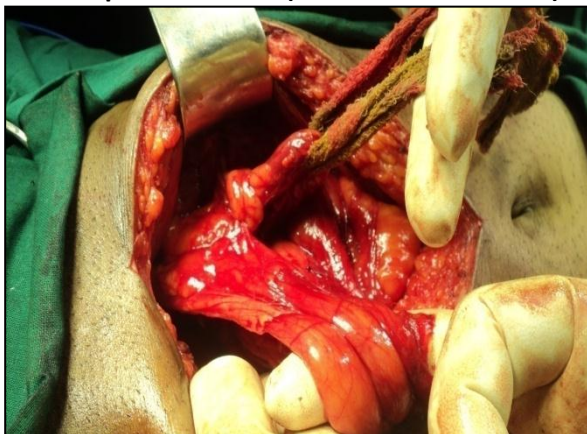


Figure 2-Dissection Showing Lateral Boundary, Psoas Major Muscel And Also Inferior Epigastric Vessels Just Above Spermatic Cord Beneath The Anterior Abdominal Wall

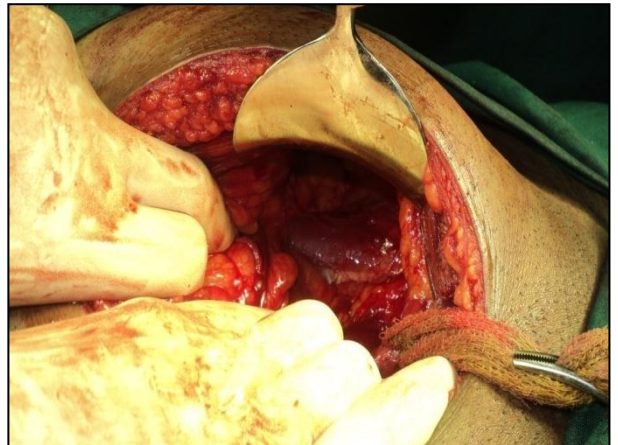
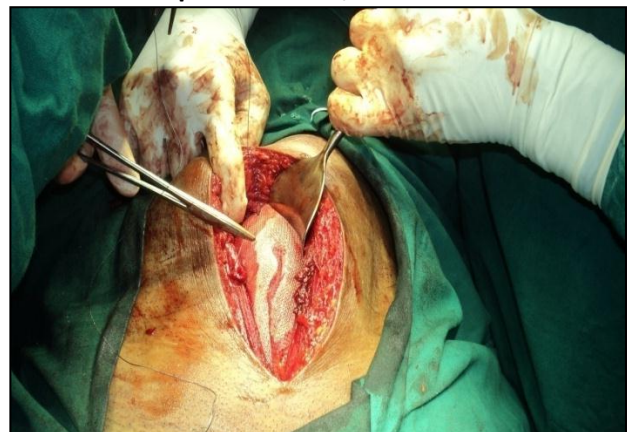


Figure 3- Spreading Mesh

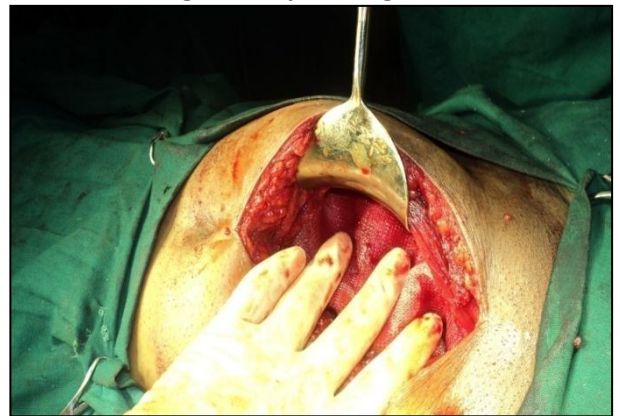

Figure 4-Mesh Fixation By Just One Stitch On Superior Border, In Midline



Results: It was feared that developing such a large pre-peritoneal plain will be difficult as well as time consuming. But to our surprise results were in complete contrast. Plane developing was quite

easy and average time for complete dissection on one side was not more than 30 minutes. Time decreased as expertise developed. The time taken can be significantly less than even Lichtenstein's repair⁵. The most difficult part of surgery seems to be freeing of larger indirect sac from vas and genital vessels. Repair of direct hernias was quite fast and easy and bilateral direct hernias can be repaired even more rapidly than inguinal approach. Repair of recurrent and re-recurrent hernias was also quite easy as one enters in virgin pre-peritoneal plane, bypassing inguinal region. On the first postoperative day about 400-600 ml sero-sanguinous drainage was observed, which usually declines to 200 ml on 2nd day and drain can be removed on 4th day. No wound infections were found. Small amount of self-limiting serous discharge was seen in 2(4%) cases. First operated case complained uneasiness on 1st postoperative day and was observed in ICU. One patient developed hippocampus infarction on day 7 and patient died at home 1 month after discharge. No other major complications were seen. No recurrences were seen upto 1 year of follow up, which coincide with Mohammad Aslam study⁶.

In, Hernia, 2006, stoppa's procedure results were described in 420 hernias and results were as described below: "Operative time decreased from 100 min (1995) to 61-66 min (2001-2003). Drain remained in place in 100% (1995), and 0% (2003). Regional anaesthesia was performed in 25% (1995) and 80-90% in the last years; hospital stay decreased from 5.1 to 1.2 days (2003), and morbidity from 50% (1995) to 12-16% (P<0.0001). There were three recurrences, two in the first 30 cases (6.6%), and one in the remaining 180 (0.5%)⁷". As the number was large in that study, recurrences may have been seen. As we performed all procedure in spinal anaesthesia morbidity related to general anaesthesia decreased. We routinely kept patients for 7-8 days and discharged only after stitch removal.

The recurrence rate was 0.71% (3 out of 420) in Hemmat Maghsoudi's study⁸, which also suggest very low recurrence rate. No neuropathies, chronic pain or testicular atrophies were seen as in that study as in ours.

Discussion: Stoppa's pre-peritoneal hernia repair is an excellent but infrequently performed method for inguinal hernia. Due to unfamiliarity of pre-peritoneal approach, especially in older surgeons, it remains an infrequently performed surgery. We have seen that it is quite easy to develop pre-peritoneal plane, especially in direct hernias and small to medium indirect hernias. In bilateral hernias time taken for surgery can decrease significantly, while in recurrent hernia and re-recurrent hernia, it avoids difficult dissection in inguinal region while simultaneously chances of recurrence becomes almost nil and no major complications are observed.

Actually, keeping in mind the low recurrence rate of Stoppa's technique, laparoscopic Totally Extra peritoneal Procedure (TEPP) was developed, to combine low recurrence with minimal pain of laparoscopic procedure⁹. It is also method of choice when TEPP proves difficult and conversion to open technique is required¹⁰.

The procedure involves a lower midline incision below umbilicus, which is cosmetically not a suitable site, especially in females. Unfamiliarity to anatomy of pre-peritoneal cleavage plane and close proximity of external iliac vessels during dissection may discourage a surgeon to choose this procedure. It is not suitable procedure for primary, unilateral hernia due to need for larger midline incision. It is also not procedure of choice for very large primary, indirect hernia as this involves tedious dissection in pre-peritoneal plane, with sometimes a need to put second incision in inguinal region to free contents of hernial sac.

Conclusion: Stoppa's pre-peritoneal repair remains a significant armamentarium for a hernia surgeon for difficult, recurrent and re-recurrent inguinal hernia surgery.

References:

1. Stoppa RE. The treatment of complicated groin and incisional hernias. *World J Surg* 1989;13:545.
2. Stoppa RE. Reinforcement of the Visceral Sac by a Preperitoneal Bilateral Mesh Prosthesis in Groin Hernia Repair, Chap 64. In : *Abdominal*

- Wall Hernias : New York : Springer ;2001;pp. 428-36.
3. Stoppa RE. Giant Prosthesis for Reinforcement of the Visceral Sac in the Repair of Groin and Incisional Hernias, Chap 175. In : Fischer Joseph E, editor. *Mastery of Surgery*, 5th edn. Lippincott Williams & Wilkins; 2007;pp .1923-1931.
 4. Rodrigues A, Hwan J, Massazo E , Consuelo JR . The Stoppa procedure in inguinal hernia repair: to drain or not to drain *Rev. Hosp. Clin.(online)* 2003 ;58 (2):97-102.
 5. Malazgirt Z, Ozkan K., Dervisoglu A, Kaya E. Comparison of Stoppa and Lichtenstein techniques in the repair of bilateral inguinal hernias. *Hernia* 2000; 4(4): 264-67.
 6. Aslam MN, Shoaib S. A practical experience with the repair in our set up. *Pak J of Med Health Sci* 2009;3(2):171-73.
 7. Fernandez LR, Tartas RA, Jimenez-Miramón FJ, Marin-Lucas FJ, de Adana-Belbel JC, Esteban ML. Stoppa procedure in bilateral inguinal hernia, *Hernia* 2006 ;10(2):179-83.
 8. Hemmat Maghsoudi, Ali Pourzand. GPRVS, the stoppa groin hernia repair for groin hernia in 234 patients. *Ann Saudi Medicine* 2005;25(3):228-232.
 9. Knook MT, Weidema WF, Stassen LP, Boelhouwers RU, van Steensel CJ. Endoscopic totally extraperitoneal repair of bilateral inguinal hernias . *The British Journal Of Surgery* 1999; 86 (10): 1312-6.
 10. Ates M, Dirican A, Ozgor D, Gonultas F, Isik B. conversion to Stoppa procedure in laparoscopic totally extraperitoneal inguinal hernia repair. *Journal Of The Society Of Laparoendoscopic Surgeons* 2012; 16 (2): 250-4.

Conflict of interest: None
Funding: None
Cite this Article as: Dr. Shah B, Dr. Singh V, A study of 50 cases of Stoppa's pre-peritoneal repair of bilateral inguinal hernia. <i>Natl J Integr Res Med</i> 2015; 6 (2): 57-60