

## Morphometric Study Of Thyroid Cartilage In Indian Cadavers

Rawal J.D\*, Kariya V.B\*\*, Doshi B.D\*\*, Jadav H.R\*\*\*.

\*Assistant Professor, \*\*Associate Professor, \*\*\*Professor & Head, Dept. Of Anatomy, GMERS Medical College Sola, Ahmedabad Gujarat.

**Abstract: Introduction:** The larynx is an air passage and a sphincteric device used in respiration and phonation. The larynx, from inside outwards has a framework of mucosa surrounded by fibro-elastic membrane which in turn is surrounded by cartilages and then a layer of muscles. As thyroid cartilage is the largest amongst all the laryngeal cartilage, its study is helpful in constructing biomechanical model, planning of laryngoplasty, positioning of thyroplasty window and analysis of CT and MRI scan. **Aim:** The aim of the present study is to estimate various dimensions of Thyroid cartilages in Indian subjects. **Material & Methods:** 50 larynx were obtained from embalmed cadavers, of which 10 larynx were of females. Thyroid cartilage was dissected from the larynx and morphometric analysis was done. **Results & Conclusions:** The average maximum height of the thyroid laminae was found to be 26.56 mm.  $\pm$  2.88 mm. on the right and 26.60 mm.  $\pm$  2.84 mm. on the left in males and 24.20 mm.  $\pm$  3.89 mm. on both right and left in females. The average width of the thyroid laminae was found to be 36.83 mm.  $\pm$  3.60 mm. on the right and 37.07 mm.  $\pm$  3.67 mm. on the left side in males and 31.85 mm.  $\pm$  3.69 mm. both on right and left in females. The average internal angle of thyroid cartilage was found to be  $74.40^\circ \pm 8.21^\circ$  in males and  $92.35^\circ \pm 6.63^\circ$  in females. [Rawal J NJIRM 2014; 5(3) :46-50]

**Key Words:** Internal Angle, Larynx, Thyroid Cartilage, Thyroid laminae.

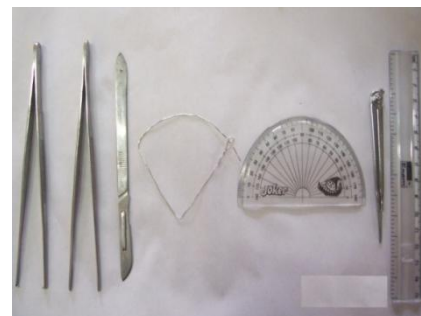
**Author For Correspondence:** Dr. Jitendra D Rawal; F-402, ICB Flora, S.G. Highway, Near Gota Chokdi, Gota, Ahmedabad, Gujarat, India. Pin 382481; Email: jeeturw@gmail.com

**Introduction:** The larynx, which is an air passage and a sphincteric device used in respiration and phonation, is present in the neck region projecting between the great vessels of neck region extending from the level of third cervical to sixth cervical vertebra. The larynx, from inside outwards has a framework of mucosa surrounded by fibro-elastic membrane which in turn is surrounded by cartilages and then a layer of muscle. Thyroid cartilage is the largest amongst the laryngeal cartilages. It extends from the level of third cervical vertebra to the fifth cervical vertebra. It has two quadrilateral laminae which are fused on the anterior aspect along their inferior two-thirds in the median plane having an angle between them thus forming subcutaneous laryngeal prominence ('Adam's apple') which is more distinct at its upper end and that being more prominent in males than in females. Knowledge of laryngeal anatomy is being utilized for diagnosis of various congenital and acquired laryngeal disorders using laryngoscopy, myography and imaging techniques. Appropriate surgical intervention also requires a sound knowledge of laryngeal anatomy. Proper understanding of the anatomy of larynx has helped the researchers in the field of laryngeal physiology to make great contributions towards understanding of laryngeal functions. As thyroid

cartilage is important part of laryngeal cartilages its morphometric study will help in better understanding of laryngeal anatomy.

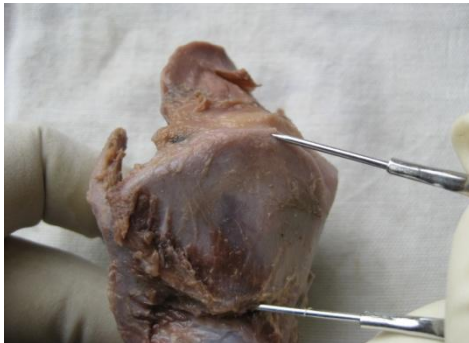**Material And Methods:** Fifty specimens of Thyroid Cartilage were dissected from embalmed cadavers. The study consisted of meticulous dissection using standard dissection kit. The methodology of this study is based on the observation of morphology and various measurements pertaining to the thyroid cartilages. The study protocol was prepared in the form of a proforma. Measurements were taken with the help of a divider, a protractor, a scale and a wire loop. Instruments used in dissection and measurement are shown in Figure 1

**Figure 1: Instruments Used In Dissection And Measurement**



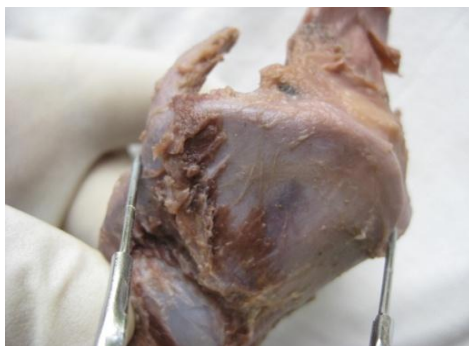
Distance between the highest point on the upper border and the lower border of the thyroid cartilage laminae was measured on both sides for obtaining the height of the thyroid lamina. One of the tips of the divider was then fixed in the superior thyroid notch and the other at the posterior border the thyroid cartilage as shown in Figure 2

**Figure 2: Measurement Of Height Of Thyroid Lamina**

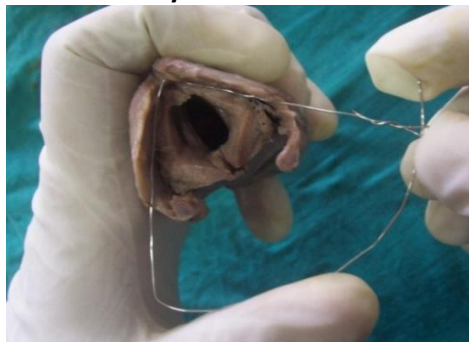

The width of the lamina was similarly measured on both sides as shown in Figure 3

**Figure 3: Measurement Of Width Of Thyroid Lamina**



**Figure 4: Measurement Of Internal Angle Between Thyroid Laminae**



A platform was created for the placement of the wire loop touching the inner surface of the two laminae of the thyroid cartilage. The loop was then gently removed without disturbing the angle and placed on the protractor to obtain the measurement of the internal angle between the thyroid laminae as shown in Figure 4

**Statistical Analysis:** All these measurements were statistically analyzed by calculating the Mean ( $\bar{x}$ ) and Standard Deviation (SD).

The Mean ( $\bar{x}$ ) and the Standard Deviation (SD) was calculated using following formulae:

$$SD = \sqrt{\frac{1}{N} \sum_{i=1}^N (x_i - \bar{x})^2}$$

$$\bar{x} = \frac{1}{n} \cdot \sum_{i=1}^n x_i$$

Observations & Results: Maximum Height Of The Thyroid Lamina Between Cranial And Caudal Rims: The maximum height of the thyroid cartilage lamina was measured on both sides and the findings were as shown in Table 1

**Table 1: Maximum Height Of The Thyroid Lamina Between Cranial And Caudal Rims**

	Side	No.	Min. (mm.)	Max. (mm.)	Mean (mm.)	SD
M	Rt.	40	20	33	26.56	2.88
	Lt.	40	20	33	26.60	2.84
F	Rt.	10	18	30	24.20	3.89
	Lt.	10	18	30	24.20	3.89

The maximum height of thyroid lamina ranged between 20 mm. and 33 mm. in males and between 18 mm. and 30 mm. in females, both for right and left sides.

In males, the average maximum height of thyroid lamina was found to be 26.56 mm. ± 2.88 mm. on the right and 26.60mm. ± 2.84 mm. on the left

side. In females, the average maximum height of thyroid lamina was found to be 24.20mm.  $\pm$  3.89 mm. on both right and left sides.

Width Of The Thyroid Lamina From The Bottom Of The Superior Thyroid Notch To The Posterior Border Of The Thyroid Cartilage: The distance between the superior thyroid notch and the posterior border of the lamina of the thyroid cartilage was measured on both sides and the findings were as shown in Table 2

**Table 2 Width OF THE Thyroid Lamina FROM THE Bottom OF THE Superior Thyroid Notch TO THE Posterior Border OF THE Thyroid CARTILAGE**

	Side	No.	Min. (mm.)	Max. (mm.)	Mean (mm.)	SD
M	Rt.	40	28	43	36.83	3.60
	Lt.	40	28	44	37.07	3.67
F	Rt.	10	26	35	31.85	3.69
	Lt.	10	26	35	31.85	3.69

In males, the width of the thyroid lamina ranged between 28 mm. and 43 mm. on the right and between 28 mm. and 44 mm. on the left side. The average width was found to be 36.83 mm.  $\pm$  3.60 mm. on the right and 37.07 mm.  $\pm$  3.67 mm. on the left side. In females, the average width was found to be 31.85 mm.  $\pm$  3.69 mm. both on right and left sides.

**Internal Angle Between The Thyroid Laminae:** The internal angle between the laminae of the thyroid cartilage was measured and the findings were shown in Table 3 and Table 4

**Table 3: Internal Angle between the Thyroid Laminae**

	No.	Min. (Degrees)	Max. (Degrees)	Mean (Degrees)	SD
M	40	53	94	74.40	8.21
F	10	82	99	92.35	6.63

In males, the internal angle ranged between 53° and 94° and the average was found to be 74.40°  $\pm$  8.21°. In females, the internal angle ranged between 85° and 100° and the average was found to be 92.35°  $\pm$  6.63°.

**Table 4: Internal Angle between The Thyroid Laminae (Distribution)**

Range (Degrees)	No. of Cases (Male)	Percentage	No. of Cases (Female)	Percentage
51 - 60	2	4.3	0	0
61 - 70	10	23.9	0	0
71 - 80	15	39.1	0	0
81 - 90	12	30.4	5	50
91 - 100	1	2.2	5	50

**Discussion:** Morphometry of Thyroid cartilages has been studied by various researchers. Accurate anatomical knowledge is essential in diagnostic and therapeutic procedures in the field of laryngology. Aside from pure anthropometry, such information has potential application in studies of laryngeal physiology, in advance methods of laryngeal imaging, and in surgery of the laryngeal framework.

Zieliński<sup>2</sup> in his study on 52 unfixed larynges involving 28 male and 24 female cadavers reported the height of the thyroid lamina from cranial to caudal rims. He reported the average measurement to be 32.3 mm.  $\pm$  0.44 mm. for male and 24.47 mm.  $\pm$  0.14 mm. in females. He reported the measurement only for the right side of the specimens. Eckel et al<sup>3</sup> reported the average value to be 27.4 mm.  $\pm$  2.47 mm. on the right and 27.6 mm.  $\pm$  2.32 mm. on the left side in male cadavers. In case of female cadavers, they reported the average to be 22.2 mm  $\pm$  2.85 mm. on the right and 22.1 mm.  $\pm$  2.67 mm. on the left side. Wysocki et al, 4 in their study, reported the measurement for right side only. In their study, the average was 28.68mm.  $\pm$  3.06 mm. in males and 25.62 mm.  $\pm$  2.73 mm. in case of females. In present study the average measurement is found to be 26.56 mm.  $\pm$  2.88 mm. on the right and 26.60 mm.  $\pm$  2.84 mm. on the left in the male cadavers. The results nearly match with what has been reported by Eckel et al.<sup>3</sup> In the females, the average measurement is found to be 24.20 mm.  $\pm$  3.89 mm. both on the right and on the left. In case of females, the values closely matched the study reported by Zieliński.<sup>2</sup>

Tayama et al<sup>5</sup> reported the width of the thyroid lamina on one the right side in their study. They found the average width to be 37.27 mm.  $\pm$  4.52 mm. in males and 28.91 mm. in case of female cadavers. Eckel et al<sup>3</sup> found the average to be 41.9 mm.  $\pm$  3.38 mm. on the right and 41.5 mm.  $\pm$  3.7 mm. on the left in male cadavers and 31.2 mm.  $\pm$  2.73 mm. on the right and 31.2 mm.  $\pm$  2.83 mm. on the left in case of female cadavers. In present study the average measurement is found to be 36.83 mm.  $\pm$  3.60 mm. on right and 37.07 mm.  $\pm$  3.67 mm. on left in case of male cadavers. In female cadavers, the average is 31.85 mm.  $\pm$  3.69 mm. on right as well as on the left side.

In present study, the internal angle of the thyroid lamina has been measured. Some researchers have reported the measurement of the external angle in their work. Eckel and Sittel<sup>6</sup> worked on twenty unfixed specimens from 12 male and 8 female cadavers of German origin. They measured the internal angle in horizontal sections. They reported the average internal angle to be 63.76°  $\pm$  8.1° in males and 80.21°  $\pm$  7.44° in female cadavers. Tayama et al<sup>5</sup> reported the average external angle between the thyroid laminae to be 77.17°  $\pm$  10.15° in males and 89.8°  $\pm$  12.44° in female cadavers. In their study they also compared their findings with Eckel and Sittel.<sup>6</sup> Jotz et al<sup>7</sup> did study on 100 fixed specimens obtained from cadavers of Brazilian origin of which 50 were males and 50 were females. Study was done measuring the external angle. They found the average to be 76.68°  $\pm$  11.35° in males and 91.08°  $\pm$  13.44° in females. In present study the average of the measurement of internal angle is found to be 74.40°  $\pm$  8.21° in males and 92.35°  $\pm$  6.63° in females. To establish present findings and to add authenticity to present study, the ratio of the angle of thyroid lamina in females to that in males is calculated.

External angle: They found the average to be 76.68°  $\pm$  11.35° in males and 91.08°  $\pm$  13.44° in females. In present study the average of the measurement of internal angle is found to be 74.40°  $\pm$  8.21° in males and 92.35°  $\pm$  6.63° in females. To establish present findings and to add authenticity to present study, the ratio of the angle of thyroid lamina in females to that in males is calculated.

It was observed in present study that the angle in females was 20% greater than males, so there is a variation in voice production in case of males and females. In the other studies mentioned above, it ranged from 16% to 26% but it was invariably greater in females. Tayama et al<sup>4</sup> mentioned that their study was consistent with that of Sprinzi et al (1999). Eckel and Sittel<sup>5</sup> suggested that there was a general agreement on the gender dimorphism of the larynx, characterized by about 20° greater angle formed by the thyroid laminae in female larynges. This statement exactly matched our findings. Wysocki et al<sup>3</sup> quoted Ajmani et al (1980), Sprinzi et al (1999) and Tayama et al (2001) that thyroid cartilage angle was significantly larger in women and girls than in men and boys. They mentioned this rule to be widely known as one of the dimorphic features in humans. Jotz et al<sup>6</sup> quoted Ajmani (1990) who had noted that the angle of the thyroid cartilage was significantly larger in women than in men, varying from 60° to 106° in men and from 88° to 132° in women. Ajmani, Jain and Saxena,<sup>8</sup> in their study on 150 specimens of both genders, mentioned that the thyroid angle in male was 78°  $\pm$  10° and in female 106°  $\pm$  14°. Not only are such gender related morphological differences important for the purpose of biomechanical modeling, but they also have important clinical implications. They are critical to the accurate placement of electromyography electrodes in male versus female patients, as well as the precise planning of laryngeal framework surgeries involving thyroid angle alteration and/or precise positioning of thyroplasty window.

#### Conclusions :

1. The average maximum height of the thyroid laminae was found to be 26.56 mm.  $\pm$  2.88 mm. on the right and 26.60 mm.  $\pm$  2.84 mm. on the left in male and 24.20 mm.  $\pm$  3.89 mm. on both right and left in female cadavers. The results nearly match with the other studies.
2. The average width of the thyroid laminae was found to be 36.83 mm.  $\pm$  3.60 mm. on the right and 37.07 mm.  $\pm$  3.67 mm. on the left side in male and 31.85 mm.  $\pm$  3.69 mm. both on right and left in female cadavers. So this observation is similar to the observations of other studies.

3. The average internal angle was found to be  $74.40^\circ \pm 8.21^\circ$  in male and  $92.35^\circ \pm 6.63^\circ$  in female cadavers, which supports the observation of previous studies.

**References:**

1. Bannister L. Respiratory System. In: Bannister LH, Berry MM, Collins P, Dyson M, Dussek JE, Ferguson MWJ, editors. Gray's Anatomy: The Anatomical Basis of Medicine and Surgery. 38<sup>th</sup> ed. New York: Churchill Livingstone, 1995; 1637-45.
2. Zieliński R. Morphometric Study on Senile Larynx. Folia Morphol. 2001 Vol. 60, No. 2: 73-78.
3. Eckel HE, Sittel C, Zorowka P, Jerke A. Dimensions of the Laryngeal Framework in Adults. Surg Radiol Anat 1994; 16(1): 31-36.
4. Wysocki J, Kielska E, Orszulak P, Reymond J. Measurements of Pre- and Postpubertal Larynx: A Cadaver Study. Surg Radiol Anat 2008; 30: 191-9.
5. Tayama n, Chan RW, Kaga K, Titze IR. Geometric Charecterization of the Laryngeal Cartilage Framework for the Purpose of Biomechanical Modeling.

Conflict of interest: None
----------------------------

Funding: None
---------------