

## Role Of Fiber Optic Bronchoscopy (FOB) In The Diagnostic Evaluation Of Non-Resolving Pneumonia

Dr. Lalitkumar B. Patel\*, Dr. Jigna Dave\*\*, Dr. Yesha V. Patel\*

\*Senior Resident, \*\*Professor, Department Of Respiratory Medicine, Govt. Medical College, Bhavnagar, India

**Abstract:** Background: This study aims to evaluate the etiology in cases of non-resolving pneumonia using FOB. Non-resolving pneumonia is a challenging clinical condition that requires more investigation. It accounts for 15% of inpatient pulmonary consultations. A delay in diagnosis and treatment may lead to a rise in mortality by 3% to 5%. Material And Methods: A cross-sectional study was done over a period of 22 months. A total of 50 cases of non-resolving pneumonia were included. A complete history was taken and a clinical examination was done. All were subjected to CECT chest and investigations which were required for diagnosis. FOB and guided procedures were done for all patients and samples were sent to the laboratory. Result: In this study, bacterial pneumonia (32%) was found to be the commonest etiology of non-resolving pneumonia, followed by Tuberculosis (22%), malignancy (16%) and fungal pneumonia (6%). In 24% of patients, the results were inconclusive. Conclusion: Non-resolving pneumonia is often an area of clinical dilemma. FOB is an extremely useful investigation. [Patel L Natl J Integr Res Med, 2023; 14(1): 32-36, Published on Dated: 20/01/2023]

**Key Words:** Fiber Optic Bronchoscopy (FOB), Non-Resolving Pneumonia, Broncho Alveolar Lavage (BAL)

**Author for correspondence:** Dr. Lalitkumar B. Patel, Senior Resident, Department Of Respiratory Medicine, Government Medical College, Bhavnagar (India). E-Mail: lalitbpatel333@gmail.com Mobile: 7874015563

**Introduction:** Non-resolving pneumonia is a common clinical problem, estimated to be responsible for approximately 15 percent of inpatient pulmonary consultations and 8 percent of bronchoscopies<sup>1,2</sup>. A delay in diagnosis and treatment may lead to a rise in mortality by 3 to 5 percent.

There are a variety of reasons that a case of pneumonia might resolve slowly or incompletely, including those relating to the etiology of pneumonia (misdiagnosis of the pathogen or the presence of a resistant pathogen); and the development of complications from the initial infection. Approximately 20 percent of presumed non responding community-acquired pneumonia is due to non-infectious causes<sup>3,4</sup>.

The relative ease and low risk of bronchoscopy make this the diagnostic procedure to obtain specimens from patients with a wide spectrum of possible infectious and noninfectious etiologies of non-resolving pneumonia. The efficacy of FOB in the etiological diagnosis of non-resolving pneumonia has been around 70-86%. Detailed micro-biological, cytological and histo-pathological tests of the yielded specimens by this procedure can be done for etiological diagnosis of underlying cause<sup>5</sup>. In this study, we aimed to establish the role of fiber optic bronchoscopy in evaluating the etiological

diagnosis of non-resolving pneumonia or slowly resolving pneumonia and also to find out co-morbid conditions if any associated with non-resolving pneumonia.

**Material & Methods:** The study was a prospective cross-sectional study conducted on a total of 50 patients.

Inclusion Criteria: 1) Presence of persistence of clinical symptoms and signs (cough, sputum production, with or without fever more than 100°F). 2) Failure of resolution of the radiographic features by 50% in 2 weeks or completely in 4 weeks on serial chest X-ray (indicated in at least 2 consecutive chest X-rays) despite antibiotic therapy for a minimum period of 10 days. 3) Sputum for acid-fast bacilli (AFB) smear-negative for 2 consecutive days.

Exclusion Criteria: 1) Age less than 18 years. 2) Diagnosed cases of lung cancer or sputum-positive pulmonary tuberculosis were excluded. 3) Patient who gave negative consent for Fiber optic bronchoscopy. Written informed consent was taken from all the subjects before the study.

A complete history was taken and a clinical examination was done. All were subjected to CECT chest and investigations which were required for diagnosis. Fiber-optic bronchoscopy

This is an Open Access article distributed under the terms of the Creative Commons Attribution 4.0 International License (<http://creativecommons.org/licenses/by/4.0/>), allowing third parties to copy and redistribute the material in any medium or format and to remix, transform, and build upon the material for any purpose, even commercially, provided the original work is properly cited and states its license.

was done in all patients, by which the macroscopic appearance of the trachea-bronchial tree was noted. During bronchoscopy Broncho alveolar lavage (BAL) was taken and fluid was sent for AFB smear and CBNAAT/TruNAAT, gram stain and culture, fungal stain and culture, and malignant cells in all patients. Bronchial brushing and biopsy were also done in selected patients

who were sent for cytopathology, and histopathology, respectively.

**Results:** A total of 50 subjects were included in the present study Out of 50 cases 28(56%) were male and 22(44%) were female. 60 % of patients were above the age of 50 years [Table 1].

**Table 1: Age And Gender Wise Distribution Of Patients (N=50)**

Age (In Years)	Male	Female	No. Of Patients	Percentage%
20-29	02	03	05	10%
30-39	04	03	07	14%
40-49	04	04	08	16%
50-59	08	06	14	28%
>60	10	06	16	32%
Total	28	22	50	100%

The most common symptoms were cough in 46 patients (92%) followed by fever (78%),

decreased appetite (68%), breathlessness (30%), and hemoptysis (22%), [Table 2].

**Table 2: Various Presenting Symptoms Of The Patients (N=50)**

Presenting Symptoms	No. Of Patients	Percentage%
Cough	46	92%
Fever	39	78%
Decreased Appetite	34	68%
Breathlessness	15	30%
Haemoptysis	11	22%
Chest Pain	10	20%

From a total of 50 subjects 26 (52%) patients had a significant past history which also revealed the associated co-morbid conditions. Of these 26 patients, 7 patients had more than one co-morbid condition. 13 patients (26%) had diabetes mellitus, 11 patients (22 %) had chronic obstructive pulmonary disease (COPD), 4 patients (8%) had pulmonary tuberculosis in the past have

received treatment for the same and 7 patients (14%) had systemic hypertension. 31 (62%) patients had a history of smoking, alcoholism or tobacco chewing. Of these, 21 patients (42%) were addicted to more than one of these habits. 20 patients (40%) had smoking habits, 8 patients (16%) were alcoholic and 23 patients (46%) had tobacco chewing habits [Table 3].

**Table 3: The Comorbidities And Addiction Of The Study Population (N=50)**

Condition & Addiction	Number Of Patients	Percentage
COPD	11	22%
Diabetes	13	26%
Tuberculosis In Past	04	08%
Hypertension	07	14%
Tobacco Chewing	23	46%
Smoking	20	40%
Alcoholic	08	16%

In this study, FOB was done in all 50 patients. The most common macroscopic finding in FOB was inflammation with purulent secretions in the bronchial tree (46%), only inflamed mucosa was seen in 8 patients (16%), intraluminal growth was

observed in 6 cases (12%) and in 13 cases (26%) tracheobronchial tree were within normal limit [Table 4].

**Table 4: Macroscopic Finding During Bronchoscopy (N=50)**

Bronchoscopic Findings	No. of cases	Percentage %
Mucosal Inflammation With Purulent Secretion	23	46%
Inflamed Mucosa Only	08	16%
Intraluminal Growth	06	12%
Normal Tracheo-Bronchial Tree	13	26%

In this study, bacterial pneumonia (32%) was found to be the commonest etiology of non-resolving pneumonia, followed by Tuberculosis (22%), malignancy (16%) and fungal pneumonia (6%). In 24% of patients, the results were inconclusive. In pneumonia Gram-negative bacteria were found to be the predominant pathogens, accounting for approx. 14 (87.5%) cases of pyogenic infections and among them klebsiella 7 (43.7%) cases and pseudomonas 5 (31.25%) cases were the common pathogens. The incidence of malignancy was found to be high among smokers compared to non-smokers. Among malignancies, squamous cell carcinoma (50%) was common [Table 5].

**Table 5: The Etiology Of Non-Resolving Pneumonia (N=50)**

Etiology	No. Of Cases	Percentage
Bacterial	16	32%
Tuberculous	11	22%
Malignancy	8	16%
Fungal	3	6%
Inconclusive	12	24%

**Discussion:** Amberson was the first person to describe the term “unresolved organizing or protracted pneumonia” in 1943<sup>5</sup>. There is a lack of uniformity regarding the definition of non-resolving pneumonia, however in many studies, the entity of “slow resolution” has been defined as failure of radiographic resolution by 50% in two weeks or failure of complete resolution by one month despite adequate antibiotic therapy<sup>7</sup>.

Non-resolving pneumonia heralds a clinical scenario where the diagnostic dilemma is a cause of clinical concern. The lack of a definitive etiological diagnosis prevents a more targeted approach in the management. Among the various diagnostic tools available for such a scenario, the role of diagnostic bronchoscopy cannot be undermined. In our study, 76% of patients were over the age of 40 years and 60% were over the age of 50 years. Arunabha et al study has, 80% of patients were over the age of 40 years and nearly 50% were over the age of 50 years<sup>5</sup>. Fein et al

have shown in their study that only 30% of patients above 50 years of age show complete radiologic resolution by 4 weeks<sup>8</sup>. Non-resolving or slowly resolving pneumonia is common in elderly patients due to age-related impairment of several components of host defences.

In this study, the most common symptoms were cough (92%) followed by fever (78%), decreased appetite (68%), breathlessness (30%), and haemoptysis (22%). In Arunabha et al study, cough (100%) followed by fever (96.6%), haemoptysis (53.3%), chest pain (38.5%), and breathlessness (33.3%)<sup>5</sup>. Kirtland et al. studied 39 patients with slowly resolving pneumonia and found cough as the commonest symptom (92%) followed by chest pain (38%), breathlessness (38%), fever (36%), and haemoptysis (28%)<sup>9</sup>.

Boyed observed in his study that right lung appears to be more at risk for slow resolution and has also noted a predilection of chronic infiltrative disease for right upper lobe<sup>10</sup>. In the present study also, right lung involvement was most common (60%), and right upper lobe was most commonly affected (28%).

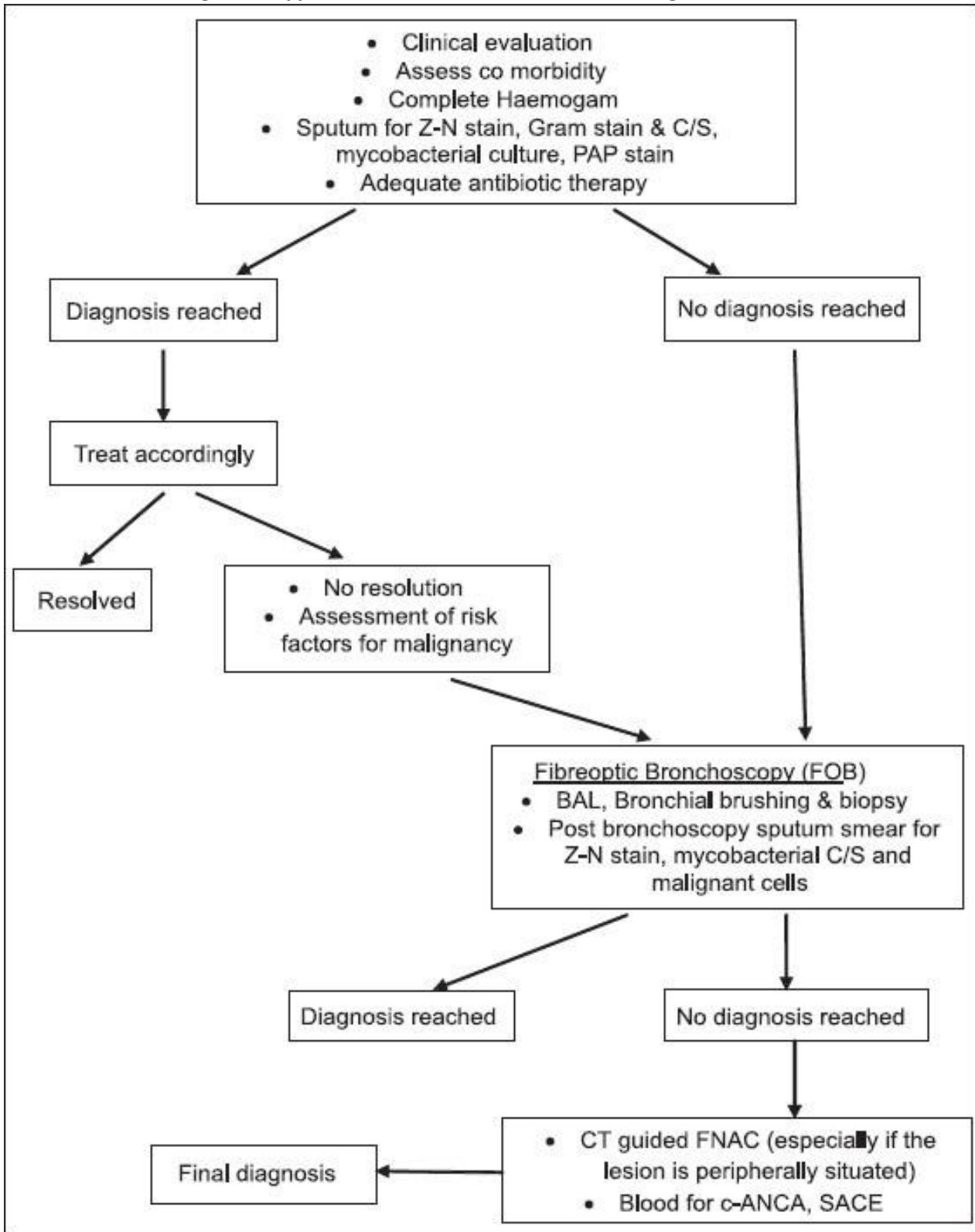
Diabetes mellitus was found to be the commonest comorbidity in this study and was present in 26 % of cases. In Arunabha et al study, 33% of patients were diabetic<sup>5</sup>. Avijgan et al have also reported that diabetes mellitus was a major association with a delayed resolution of pneumonia<sup>11</sup>.

In this study, pyogenic infection was diagnosed as etiological agent in 16 (32%) cases. Gram-negative bacteria were found to be the predominant pathogens, accounting for approx. 87.5% cases of pyogenic infections, and among them klebsiella (43.7%) and pseudomonas (31.25%) were the common pathogens. Fein also shared a similar observation of the increased occurrence of gram-negative etiology of pneumonia in elderly patients with comorbidities<sup>8</sup>. Tuberculosis was diagnosed in 22% of cases in the present study. Silver et al.

found malignancy as a specific cause of non-resolving pneumonia in 11.4% of cases in their series of 35 patients<sup>12</sup>. In the present study, malignancy was diagnosed in 16% of cases. Fiber optic bronchoscopy (FOB) was done in 50 patients, and an etiological diagnosis could be established in 38 cases (diagnostic yield 76%). BAL fluid was taken in all of these patients, and

the conclusive diagnosis was achieved in 32 patients (64%); pyogenic infection was found to be the commonest etiology. In the study by Silver et al., FOB was diagnostic in 86% of cases, and infections were the most common etiology obtained at FOB<sup>12</sup>. Balamugesh et al. have also found FOB a very useful tool in evaluating non-resolving pneumonia<sup>13</sup>.

**Figure 1: Approach To A Patient With Non-Resolving Pneumonia<sup>1</sup>**



**Conclusion:** Non-resolving pneumonia is often an area of clinical dilemma. FOB is an extremely useful investigation. Pyogenic infections are the commonest etiology, but the microbiological profile is different from that of community-acquired pneumonia. Tuberculosis, malignancy and other non-infectious causes like vasculitis are other important etiologies to be looked for.

#### References:

1. Marrie TJ. Mycoplasma pneumoniae pneumonia requiring hospitalization, with emphasis on infection in the elderly. Arch Intern Med 1993; 153:488.
2. Gotway MB, Leung JW, Dawn SK, Hill A. Nonresolving pneumonia in an otherwise healthy patient. Clin Pulm Med. 2004; 11:198–200.
3. Arancibia F, Ewig S, Martinez JA, et al. Antimicrobial treatment failures in patients with community-acquired pneumonia: causes and prognostic implications. Am J Respir Crit Care Med 2000; 162:154.
4. Fayez K, Tamim H, Walid K, Shadi L. Nonresolving pneumonia. Am J Ther. 2011;18: e177–9.
5. Chaudhuri A, Mukherjee S, Nandi S, Bhuniya S, Tapadar S, Saha M. A study on non-resolving pneumonia with special reference to role of fiberoptic bronchoscopy. Lung India: official organ of Indian Chest Society. 2013;30(1):27–32.
6. Amberson JB. Significance of unresolved organizing or protracted pneumonia. J Mich State Med Soc. 1943; 42:599–603.
7. Rome L, Murali G, Lippmann M. Non-resolving pneumonia and mimics of pneumonia. Med Clin North Am 2001; 85:1511–30.
8. Fein AM. Pneumonia in the elderly: Overview of diagnostic and therapeutic approaches. Clin Infect Dis 1999; 28:726–9.
9. Kirtland SH, Winterbauer RH. Slowly resolving chronic and recurrent pneumonia Clin Chest Med. 1991;12:303–18.
10. Boyd DH. Failure of resolution Br J Dis Chest. 1975;69:259–66.
11. Avijgan M. Specificity and sensitivity of clinical diagnosis for chronic pneumonia East Mediterr Health J. 2005;11:1029–37.
12. Feinsilver SH, Fein AM, Niederman MS, Schult DE, Faegenburg DH. Utility of fiberoptic bronchoscopy in non resolving pneumonia Chest. 1990;98:1322–6.
13. Balamugesh T, Aggarwal AN, Gupta D, Behera D, Jindal SK. Profile of repeat fiberoptic

bronchoscopy Indian J Chest Dis Allied Sci. 2005;47:181–5.

Conflict of interest: None
----------------------------

Funding: None
---------------

Cite this Article as: Patel L, Dave J, Patel Y. Role Of Fiber Optic Bronchoscopy (FOB) In The Diagnostic Evaluation Of Non-Resolving Pneumonia. Natl J Integr Res Med 2023; Vol.14(1): 32-36
--