

## A Study Of Paranasal Sinus Complications In Post Covid Patients At A Tertiary Care Centre

Dr. Andalib Daymakumar\*, Dr. Yadukrishnan MU\*, Dr. Sushil G Jha\*\*

\*3<sup>rd</sup> Year Resident, \*\*Professor & HOD, Department Of Otorhinolaryngology, Sir T Hospital And Government Medical College, Bhavnagar, Gujarat- 364001

**Abstract:** Background: Paranasal sinus complications in patients recovering from COVID 19 is on the rise. This study is to evaluate the clinically suspected cases of Post Covid Sinusitis patients. Material And Methods: Total 200 cases of Post Covid Sinusitis patients were included in this study. The demographic profile, clinical and radiological presentation, underlying immunocompromised status, laboratory results and treatment outcome of the patients was analysed. Result: Post Covid Sinusitis was observed mainly in the fifth and sixth decade of life with a male predominance. Most common associated disease was diabetes mellitus (77%). Laboratory analysis revealed infection with Mucor and Aspergillus species most commonly. Sino-nasal, orbital, cerebral, palatine and skin involvement found in 100%, 40%, 12.5%, 37% and 2.5% of patients, respectively. Symptoms and signs are headache (62.5%), cheek swelling (40%), and decreased vision (26.5%). All patients were treated by surgical debridement, antibiotics and antifungal medications. Overall survival rate was 87.5%. Conclusion: Clinical suspicion and early diagnosis in post covid patients followed by surgical debridement of diseased tissue, antifungal and antibiotic medications are crucial for better prognosis and improved survival rates. [Daymakumar A Natl J Integr Res Med, 2021; 12(4):8-13]

**Key Words:** COVID 19, Diabetes Mellitus, Fungal Sinusitis, Mucor

**Author for correspondence:** Dr. Andalib Daymakumar, Department Of Otorhinolaryngology, Sir T Hospital And Government Medical College, Bhavnagar– 364001. E-Mail: dayma\_andalib@yahoo.in

**Introduction:** Corona virus disease 2019 (COVID 19), caused by the novel Severe Acute Respiratory Syndrome Corona virus 2 (SARS-CoV-2) is an infectious disease leading to a global pandemic<sup>1,2</sup>. Several cases of opportunistic fungal and bacterial infections have been reported in Post Covid patients which may be attributed to immunosuppression and preexisting comorbidities (Diabetes, Lung disease)<sup>3</sup>. Rhino-orbital-cerebral Mucormycosis was declared an epidemic in the state of Gujarat, India in the month of May 2021. Acute invasive fungal rhinosinusitis is a fatal fungal infection that has serious morbidity and mortality. Cases of acute bacterial sinusitis and chronic rhinosinusitis have also been noted.

Aim and Objective: The aim of this article is to analyse the signs and symptoms, radiological, microbiological and pathological findings, patient demographics, medical and surgical management and the clinical outcome of the clinically suspected cases of Post Covid Sinusitis presenting to Department of Otorhinolaryngology, Sir T hospital and Government Medical College, Bhavnagar, Gujarat.

**Material & Methods:** A Retrospective observational study was carried out on 200 cases

of Post Covid Sinusitis patients who were admitted in the Department of Otorhinolaryngology, Sir T hospital and Government Medical College, Bhavnagar, Gujarat in the months of May and June 2021.

The study included patients of all age groups and gender. Detailed History taking, general examination and ear, nose, throat examination, Diagnostic Nasal Endoscopy, radiological investigations like CT Paranasal sinus and MRI Brain+ Orbit were done. Covid RTPCR testing and routine blood investigations were done.

All patients having suspicion of complication based on clinical and CT findings suggestive of opacities in paranasal sinus or MRI Brain/Orbit findings suggestive of orbital cellulitis, optic neuritis, intracranial extension most likely due to fungal aetiology were sent for nasal swab testing and posted for operative management.

Functional Endoscopic Sinus Surgery (FESS) with/without Caldwell Luc's approach was done, diseased tissue removed intraoperatively was sent for potassium hydroxide mount and histopathological examination. Pus was sent for culture sensitivity testing. Patients were started on Injectable Amphotericin and respective

This is an Open Access article distributed under the terms of the Creative Commons Attribution 4.0 International License (<http://creativecommons.org/licenses/by/4.0/>), allowing third parties to copy and redistribute the material in any medium or format and to remix, transform, and build upon the material for any purpose, even commercially, provided the original work is properly cited and states its license.

sensitive Antibiotics. Nasal douching was done for all the patients. Orbital extension was managed by Ophthalmologists and for intracranial extension, Physicians and Neurosurgeons were consulted.

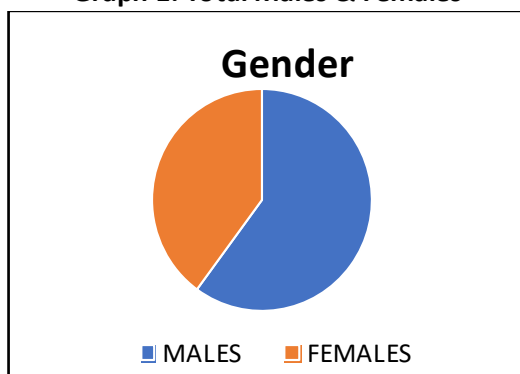
**Inclusion Criteria:** All Post Covid patients presenting with complain related to nasal and paranasal sinus were included in the study.

**Exclusion Criteria:** Patients giving negative consent for participation in the study were excluded

**Results:** The study was carried out in a total of 200 patients who were admitted in Sir T hospital, Bhavnagar from May 2021 to June 2021 with Post Covid Sinusitis.

Among them it was observed that males 60 % (n= 120) were more affected than females 40% (n= 80) with highest prevalence seen in fifth and sixth decade of life.

**Graph 1: Total Males & Females**



**Table 1: Symptoms Of Patients Presenting With Sinus Complications**

Symptoms	N (%)
Headache	125 (62.5)
Cheek Swelling	80 (40)
Nasal Obstruction	66 (33)
Decreased Vision	51 (26.5)
Facial Pain	37 (18.5)
Tooth Ache	36 (18)

**Table2: Associated Co-Morbidities Of Patients Included In The Study**

Co-Morbidities	N (%)
Diabetes Mellitus	154 (77%)
Steroid Use	50 (25%)
Oxygen Support	40 (20%)
Hypertension	28 (14%)
Cardiac Disease	6 (3%)

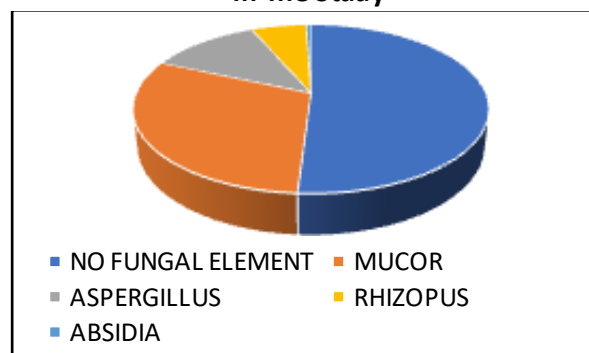
**Table 3: Clinical Extension Of Disease In Patients Included In The Study**

Paranasal Sinuses	N (%)
Maxillary Sinus	186 (93)
Ethmoid Sinuses	142 (71)
Sphenoid Sinus	70 (35)
Frontal Sinus	44 (22)
Orbit	80(40)
Intracranial	25 (12.5)
Palate	64 (37)
Skin	5 (2.5)

**Table 4: Potassium Hydroxide (KOH) Reports Of The Patients Included In The Study**

KOH Mount / Culture	N (%)
No Fungal Elements	102 (56)
Mucor	61 (30.5)
Aspergillus	24 (12)
Rhizopus	12 (6)
Absidia	1(0.5)

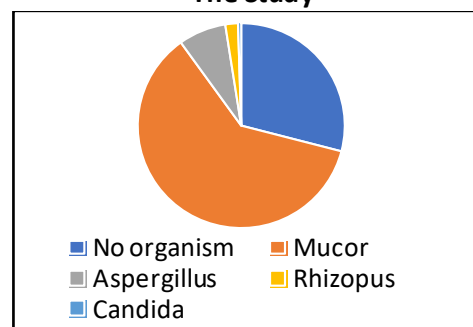
**Graph 2: KOH Reports Of The Patients Included In The Study**



**Table 5: Histopathological Reports Of The Patients Included In The Study**

Histopathological Results	N (%)
No Organism	58(29)
Mucor	122(61)
Aspergillus	15 (7.5)
Rhizopus	04 (2)
Candida	01 (0.5)

**Graph 3: Patient's Histopathological Reports In The Study**

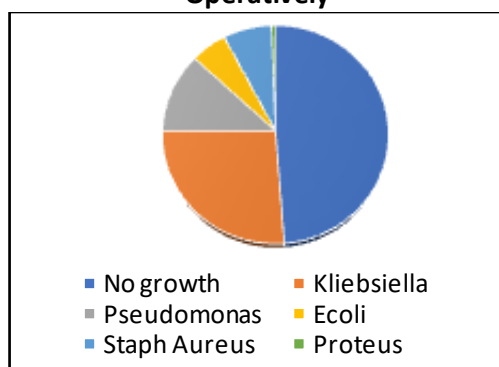


Pus present in 160 patients, drained intra-operatively and sent for culture sensitivity.

**Table 6: Pus Culture Sensitivity Reports Of Patients In Whom Pus Was Drained Intra-Operatively**

Pus Culture Sensitivity	N (%)
No Growth	82(48.8%)
Klebsiella	44 (26.2%)
Pseudomonas	20 (11.9%)
Staphylococcus Aureus	12(7.1%)
Escherichia Coli	09 (5.3%)
Proteus Vulgaris	01 (0.5%)

**Graph 4: Pus Culture Sensitivity Reports Of Patients In Whom Pus Was Drained Intra-Operatively**



**Table 7: Segregation Of Bacterial And Fungal Sinusitis On The Basis Of Pus Culture And KOH/Histopathology Reports**

	Organisms In Pus Culture Sensitivity	Fungal Elements	Total
Bacterial Sinusitis	58	-	58
Fungal Sinusitis	-	114	114
Bacterial + Fungal Sinusitis	28	28	28

**Table 8: Involvement Of Paranasal Sinuses In Bacterial And Fungal Sinusitis**

Paranasal Sinus	Bacterial Sinusitis	Fungal Sinusitis
Maxillary	37 (92.5%)	121 (85.2%)
Ethmoid	28 (70%)	85 (59.8%)
Sphenoid	14 (35%)	99 (69.7%)
Frontal	9 (22.5%)	42 (29.5%)

Surgery was done in all patients, followed by injectable amphotericin and antibiotics postoperatively with regular renal function monitoring and electrolyte imbalance

management in fungal sinusitis patients while antibiotics were started for the bacterial sinusitis patients. Alkaline nasal douching and gentian violet douching were done for all the patients. Out of these patients 25 patients expired whereas 175 patients recovered post operatively. \*N = number of patients

**Discussion:** Covid 19 patients have largely been reported to suffer from fungal co-infection. Yang et al. found three (3/52, 5.8%) patients with pulmonary fungal co-infection in 52 critically ill patients<sup>4</sup>. Paranasal sinus complications occurring due to bacterial as well as fungal infection in post covid patients have been found. Acute invasive fungal sinusitis is a time-sensitive condition that must be recognized and treated promptly to avoid life-threatening complications<sup>3</sup>.

A Standardized definition of AIFR includes presence of tissue invasion by fungal elements over an acute clinical course of less than 4 weeks<sup>5</sup>. Progression occurs over a number of days, but no longer than a few weeks with possible vascular invasion and thrombosis<sup>6</sup>.

Usually, it presents with acute onset of facial pain, fever, and nasal congestion with frequent extension into adjacent structures, including the paranasal soft tissues, orbit, and cranial vault.

Orbital involvement results in attenuation of vision, while sinus or intracranial extension can be associated with proptosis or neurological impairments, respectively<sup>6,7</sup>.

In this study, 120(60%) patients were male and 80(40%) patients were female. In the study of Patron et al, 44% patients were male and 55.9% patients were female.

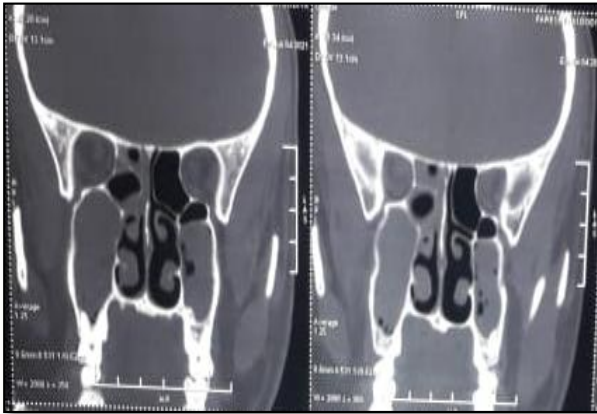
In this study, most common presenting symptoms were headache (62.5%), cheek swelling (40%), nasal obstruction (33%), decreased vision (26.5%), facial pain (18.5%) and toothache (18%). Symptoms noted here are slightly different from the study of Patron et al like headache, visual loss, facial pain and fever (59.3, 47.5, 35.6 and 33.9 percent respectively)<sup>8</sup>.

Previous study carried out by Kursun et al., on non-COVID AIFR showed that the most common co-morbidity was DM, and to a lesser extent, haematological malignancies and chronic kidney disease<sup>9</sup>. In other pre-COVID pandemic studies,

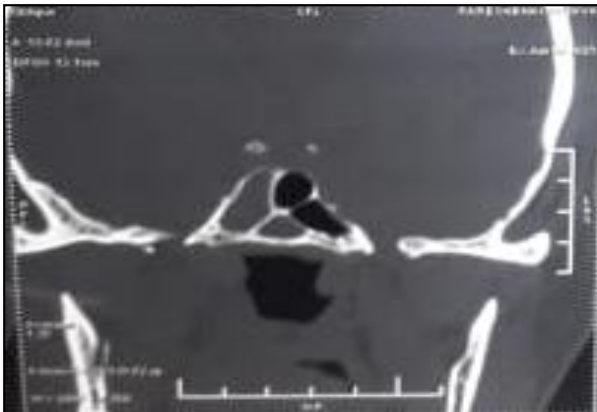
the most common concomitant disease was also DM. Turner et al. at 2013 reported presence of diabetes, hematologic malignancies, and corticosteroid use in 47.8%, 39.0% and 27.6% of their patients, respectively<sup>10</sup>.

This is in accordance with results in our study as the most common associated disorder was diabetes mellitus (77%) followed by hypertension (14%). Out of the 200 patients, long term steroid use was reported in 25% patients and 20% patients were previously on oxygen support.

**Figure 1: CT Paranasal Sinus Showing Opacities In Maxillary**

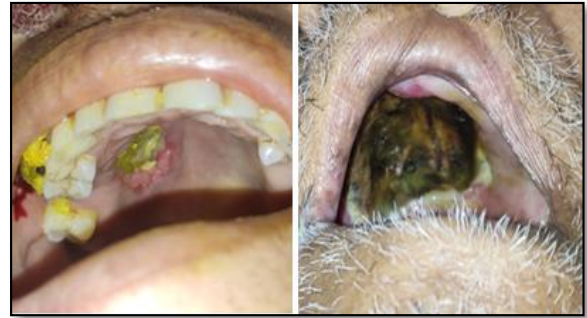

**Figure 2: Ethmoid And Sphenoid Sinuses In A Post Covid Sinusitis Patient**

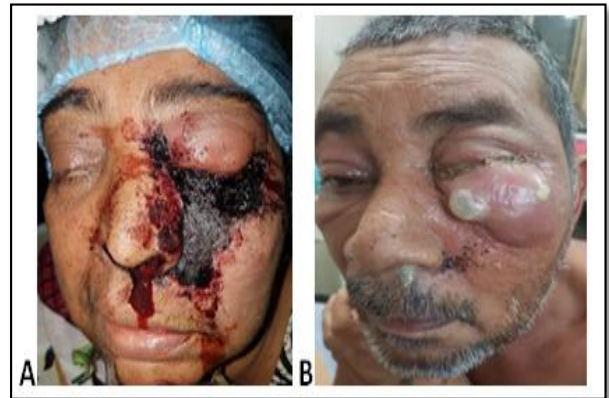

Clinical examination, endoscopic findings and CT scan showed various stages of sinonasal (100%), orbital (40%), cerebral (12.5%), palatine (37%) and skin (2.5%) involvement. In this study, the most commonly involved paranasal sinus is maxillary sinus (93%) followed by ethmoid sinus (71%), sphenoid sinus (35%) and frontal sinus (22%). In Bacterial sinusitis, involvement of Maxillary > Ethmoid > Sphenoid > Frontal sinus and in Fungal sinusitis Maxillary > Sphenoid > Ethmoid > Frontal sinus. Palatal affection had variable patterns which involved palatal ulcers and palatal necrosis.

**Figure 3 & 4: Palatal Involvement Showing Palatal Ulceration With Necrosis**



**Figure 5: [A]Skin Involvement In A Post Covid Fungal Sinusitis Patient [B] Periorbital Abscess In A Post Covid Fungal Sinusitis Patient**



Surgical management was done for all the patients (100%) included in this study, tissue specimen was sent for KOH mount/culture and Histopathological examination and Injectable Amphotericin was started. In this study the KOH mount/culture demonstrated no fungal elements isolated (56%), Mucor (30.5%), Aspergillus (12%), Rhizopus (6%) and Absidia (0.5%). The histopathological reports are suggestive of No Organism isolated (29%), Mucor (61%), Aspergillus (7.5%), Rhizopus (2%) and Candida (0.5%). Most studies reported mainly the Mucorales species<sup>9,11,12,13</sup>.

In this study, 80% of the patients were found to have pus discharge intraoperatively in the paranasal sinuses. The Pus Culture Sensitivity reporting showed no growth in 48.8% patients and rest of the bacterial organisms isolated were Klebsiella (26.2%), Pseudomonas (11.9%), Staphylococcus aureus (7.1%), Escherichia coli (5.3%) and Proteus vulgaris (0.5%).

It was observed that out of the 200 patients included in the study, 114 were of fungal sinusitis, 58 were of bacterial sinusitis and 28 patients were of fungal + bacterial sinusitis. It has been observed that patients, whose diagnosis was early with limited disease extension, have

the best outcome with minimal mortality and morbidity. Acute invasive fungal sinusitis has high mortality and morbidity rates (18%–80%) despite improvements in medical and surgical management protocols<sup>6,14,15</sup>. Orbital and intracranial extension is associated with an increased risk of death. Mortality has been reported to range from 20% to 68% in previous studies<sup>15-19</sup>. The mortality rate in this study is 12.5% while the survival rate is 87.5%. The overall survival rate of non-COVID AIFR cases reviewed by Turner et al., was 49.7% in comparison to 87.5% in the present study. This relatively better survival rate may be due to early diagnosis while close observation during the follow-up period after COVID-19 recovery, aggressive surgical debridement, and early use of antifungal medications.

**Limitations:** The study include single referral tertiary centre experience and relatively short term follow up .

**Conclusion:** Due to high mortality rate the diagnosis and management of invasive fungal sinusitis continues to present as a challenge for otorhinolaryngologist , whereas bacterial sinusitis has a relatively better prognosis. Clinical suspicion and early diagnosis in post covid patients followed by surgical debridement of diseased tissue, antifungal and antibiotic medications are crucial for better prognosis and improved survival rates.

**References:**

1. Coronaviridae Study Group of the International Committee on Taxonomy of Viruses, Gorbalenya AE, Baker SC, et al. The species severe acute respiratory syndrome-related coronavirus: classifying 2019-nCoV and naming it SARS-CoV-2. *Nat Microbiol* 2020;5:536.
2. Zhou P, Yang X-L, Wang X-G, et al. A pneumonia outbreak associated with a new coronavirus of probable bat origin. *Nature* 2020;579:270–273.
3. El-Kholy et al.: Post COVID-19 Invasive Fungal Sinusitis. *Laryngoscope*, 00:1–7, 2021
4. Yang X, Yu Y, Xu J, et al. Clinical course and outcomes of critically ill patients with SARS-CoV-2 pneumonia in Wuhan, China: a singlecentered, retrospective, observational study. *Lancet Respir Med* 2020;8:475–481.
5. Chakrabarti A, Denning DW, Ferguson BJ, et al. Fungal rhinosinusitis: a categorization and

- definitional schema addressing current controversies. *Laryngoscope* 2009;119:1809–1818.
6. Aribandi M, McCoy VA, Bazan C III. Imaging features of invasive and noninvasive fungal sinusitis: a review. *Radiographics* 2007;27:1283–1296
7. Momeni AK, Roberts CC, Chew FS. Imaging of chronic and exotic sinonasal disease. *Am J Roentgenol* 2007;189:S35–S45.
8. Patron P,Sanguansak T. Acute Versus Chronic Invasive Fungal Rhinosinusitis: A Case-Control Study.*Infect Dis:Res Treat.*2012;5:43-
9. Kursun E, Turunc T, Demiroglu YZ, Aliskan HE, Arslan AH. Evaluation of28 cases of mucormycosis. *Mycoses* 2015;58:82–87.
- 10.Turner JH, Soudry E, Nayak JV, Hwang PH. Survival outcomes in acute invasive fungal sinusitis: a systematic review and quantitative synthesis of published evidence. *Laryngoscope* 2013;123:1112–1118.
- 11.Bellazreg F, Hattab Z, Meksi S, et al. Outcome of mucormycosis after treatment: report of five cases. *New Microbes New Infect* 2015;6:49–52.
- 12.Ketenci I, Ünlü Y, Kaya H, et al. Rhinocerebral mucormycosis: experience in 14 patients. *J Laryngol Otol* 2011;125:e3.
- 13.Saedi B, Sadeghi M, Seilani P. Endoscopic management of rhinocerebral mucormycosis with topical and intravenous amphotericin B. *J Laryngol Otol* 2011;125:807–810.
- 14.Gillespie MB, O'Malley BW, Francis HW. An approach to fulminant invasive fungal rhinosinusitis in the immunocompromised host. *Arch Otolaryngol Head Neck Surg* 1998;124:520–526.
- 15.Parikh SL, Venkatraman G, DelGaudio JM. Invasive fungal sinusitis: a 15-year review from a single institution. *Am J Rhinol* 2004;18:75–81.
- 16.40. Iwen PC, Rupp ME, Hinrichs SH. Invasive mold sinusitis: 17 cases in immunocompromised patients and review of the literature. *Clin Infect Dis* 1997;24:1178–1184.
- 17.Kennedy CA, Adams GL, Neglia JR, Giebink GS. Impact of surgical treatment on paranasal fungal infections in bone marrow transplant patients. *Otolaryngol Head Neck Surg* 1997;116:610–616.
- 18.Süslü AE, Ögretmeno glu O, Süslü N, Yücel ÖT, Önerci TM. Acute invasive fungal rhinosinusitis: our experience with 19

patients. Eur Arch Otorhinolaryngol  
2009;266:77.

19. Talbot GH, Huang A, Provencher M. Invasive aspergillus rhinosinusitis in patients with acute leukemia. Rev Infect Dis 1991;13:219–232.

Conflict of interest: None
Funding: None
Cite this Article as: Daymakumar A, MU Y, Jha S. A Study Of Paranasal Sinus Complications In Post Covid Patients At A Tertiary Care Centre. Natl J Integr Res Med 2021; Vol.12(4): 8-13